



Available online at
SciVerse ScienceDirect
www.sciencedirect.com

Elsevier Masson France
EM|consulte
www.em-consulte.com/en



REVIEW

Drug-induced valvular heart disease: An update

Valvulopathies médicamenteuses. Mise au point

Michel Andrejak^{a,b,*}, Christophe Tribouilloy^{b,c}

^a Service de pharmacologie clinique, hôpital Sud, CHU d'Amiens, avenue René-Laennec, Salouel, 80054 Amiens cedex 1, France

^b Inserm U1088, Amiens, France

^c Service de cardiologie, CHU d'Amiens, Amiens, France

Received 6 March 2012; received in revised form 11 February 2013; accepted 14 February 2013
Available online 22 March 2013

KEYWORDS

Drug-induced valvular disease;
Ergot alkaloids;
Ergot-derived dopamine agonists;
Norfenfluramine;
Valvular regurgitation

MOTS CLÉS

Agonistes dopaminergiques ergotés ;
Dérivés d'ergot ;
Norfenfluramine ;
Régurgitation valvulaire ;
Valvulopathies médicamenteuses

Summary Numerous reports have shown an unquestionable association between fibrotic valve disease and the following drugs: ergot alkaloids (such as methysergide and ergotamine), ergot-derived dopaminergic agonists (such as pergolide and cabergoline) and drugs metabolized into norfenfluramine (such as fenfluramine, dexfenfluramine and benfluorex). This review focuses on different aspects of drug-induced valvular heart disease: historical background; echocardiographic features; different drugs recognized as being responsible for valvular heart disease; and pathophysiology.

© 2013 Elsevier Masson SAS. All rights reserved.

Résumé Il est maintenant bien établi que le développement d'un processus fibrotique au niveau des valves cardiaques peut être associé à l'utilisation des médicaments suivants : alcaloïdes de l'ergot comme méthysergide et ergotamine, agonistes dopaminergiques également dérivés de l'ergot ainsi que des médicaments dont le point commun est qu'ils sont métabolisés en norfenfluramine, la fenfluramine, la dexfenfluramine et le benfluorex. Cette revue générale concerne différents aspects de ces valvulopathies médicamenteuses : historique, caractéristiques échocardiographiques, principales substances concernées et mécanismes physiopathologiques.

© 2013 Elsevier Masson SAS. Tous droits réservés.

Abbreviations: BMI, body mass index; CI, confidence interval; FDA, Food and Drug Administration; GPRD, General Practice Research Database; MDMA, 3,4-methylenedioxymethamphetamine; VHD, valvular heart disease.

* Corresponding author. Service de pharmacologie clinique, hôpital Sud, CHU d'Amiens, avenue René-Laennec, Salouel, 80054 Amiens cedex 1, France. Fax: +03 22 08 70 96.

E-mail address: andrejak.michel@chu-amiens.fr (M. Andrejak).

1875-2136/\$ – see front matter © 2013 Elsevier Masson SAS. All rights reserved.

<http://dx.doi.org/10.1016/j.acvd.2013.02.003>

Background

The possibility that the intake of drugs might be responsible for the onset of valvular heart disease (VHD) was first proposed in the mid-1960s for ergot alkaloids used for migraine prophylaxis – initially methysergide (Desernil®) and then ergotamine (Gynergene®). In 1997 to 1998, drug-related VHD was reported for two appetite suppressants – fenfluramine (Ponderal®) and dexfenfluramine (Isomeride®) – that had previously been recognized as being associated with the occurrence of pulmonary arterial hypertension. These findings led to the withdrawal from the market of these two drugs. More recently, similar findings of drug-related VHD with ergot-derived dopamine agonists were reported in patients treated with pergolide (Celance®) for Parkinson's disease and cabergoline (Dostinex®) for hyperprolactinaemic disorders. Subsequently, similar drug-related VHD was reported with prolonged use of the recreational drug ecstasy (3,4-methylenedioxymethamphetamine; MDMA) and with a drug indicated for diabetes in overweight patients (benfluorex; Mediator®). The diagnosis of such drug-related VHD is based on echocardiography.

All of these drugs that have been shown to be capable of inducing VHD were found to have a common pharmacological action on a specific serotonin receptor – the 5HT_{2B} receptor. Indeed, these drugs have an agonistic action, with a high affinity for these receptors (which are highly present in valvular tissue), leading to valvular alterations similar to those observed previously in carcinoid heart disease, a neuroendocrine malignancy linked to enterochromaffin cells, which produce great quantities of serotonin. The various drug-induced VHDs have similar morphological and histological features, characterized by tissue thickening and an abundant extracellular matrix of glycosaminoglycans and collagen, with proliferation of myofibroblasts and smooth muscle cells, few calcifications and no pronounced inflammation. The underlying valve structure is usually unchanged.

Echocardiographic features

Echocardiography is the key examination for screening and grading iatrogenic valve disease [1]. The echocardiographic features are common for all drug-induced VHDs. Variable degrees of valve regurgitation are observed. Drug-induced valve disease is generally not responsible for severe valve stenosis. It can be difficult to attribute a causal relationship between a specific drug and valve damage because pretreatment echocardiographic data are not available in the majority of cases. Moreover, mere detection of regurgitation does not provide information on the aetiology. Actually, diagnosis using two-dimensional echocardiography is based, above all, on studying the texture and motion of the valves and analysing the subvalvular apparatus for mitral and tricuspid VHD. Typically, one can generally see mild or moderate valve thickening in the absence of calcification or marked commissural fusion (in contrast with rheumatic valve disease). Restricted valve motion, which is responsible for the regurgitation, is the most characteristic feature of drug-induced valve disease. In mitral

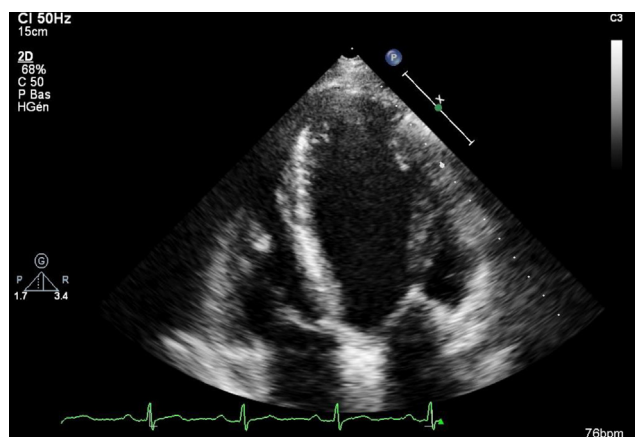


Figure 1. Patient with toxic aortic and mitral valvulopathy due to benfluorex. On this apical four-chamber view using two-dimensional echocardiography, the mitral leaflets have lost their flexibility. Note the marked remodelling of the mitral subvalvular apparatus, with slight thickening of both leaflets.

valve regurgitation, the restriction generally affects both mitral leaflets but often predominates at the posterior leaflet. Leaflet thickening is often minimal but is generally associated with unequivocal thickening and shortening of the chordae tendineae (Figs. 1 and 2). In aortic regurgitation, valve thickening is often mild (and may not be present). Variable degrees of leaflet retraction are observed, responsible for malcoaptation and regurgitation during diastole (Fig. 1). Using two-dimensional echocardiography, a small central triangular valve hiatus during diastole is observed in the short-axis view, sometimes associated with a subtle 'dome-like' aspect of the aortic valve during systole. Aortic regurgitation visualized with colour Doppler is generally central. Tricuspid and pulmonary drug-induced VHD is less common; echocardiographic findings seem similar to those observed in mitral and aortic damage.

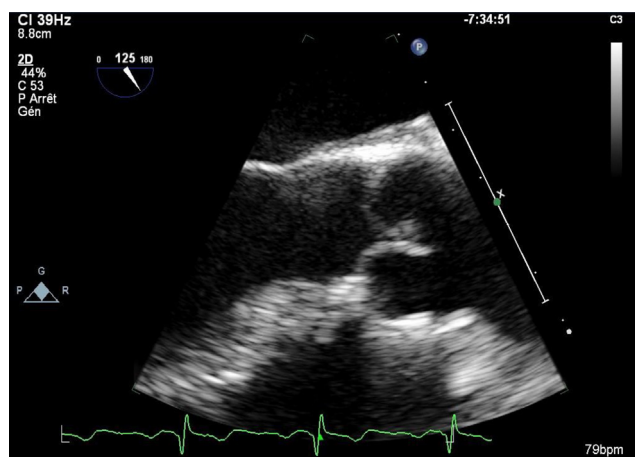


Figure 2. Same patient as in Fig. 1: the aortic cusps are slightly thickened, restrictive and fibrous-looking, with defective central coaptation.

Valvular heart disease associated with migraine drugs

Methysergide and ergotamine are old drugs used to prevent or treat migraine. These drugs were the first to be recognized as being associated potentially with the occurrence of valvular regurgitation. Methysergide – already known to induce fibrotic tissue alterations, which may explain pulmonary arterial hypertension as well as retroperitoneal fibrosis – was the first drug to be implicated. In 1967, Graham et al. [2] associated the development of valvular abnormalities with the use of this drug. Indeed, they published a series of 36 patients treated on a long-term basis with methysergide, who developed cardiac murmurs linked to mitral and/or aortic regurgitation (generally without clinical symptoms), with regression or disappearance of the murmurs after drug discontinuation in more than one third of patients. Some years later, a frequently-associated involvement of the tricuspid valves was highlighted [3]. Then, in 1974, ergotamine – another ergot alkaloid structurally related to methysergide – was also shown to be associated with left-sided VHD for the first time, with other cases reported thereafter. From 1974, the fibrotic nature of the valvular lesions was recognized, with an emphasis on these lesions being morphologically similar to those described in carcinoid heart disease [1,4]. These drugs are still on the market but are used only for short-term treatment and very rarely induce VHD.

Valvular heart disease associated with fenfluramine and dexfenfluramine

VHDs have been observed with fenfluramine and dexfenfluramine, which were used largely as anti-obesity drugs. A short time after the withdrawal of these drugs from the market in France, due to the demonstration that they may induce pulmonary arterial hypertension [5], the first 24 cases of valvular insufficiencies were reported in the USA with the fenfluramine-phentermine association, in women aged 44 ± 8 years [6]. These patients were known to have no past cardiovascular history and took this drug combination for a mean duration of 12 months; they presented with cardiac failure symptoms or a heart murmur. Echocardiograms performed on these patients demonstrated an unusual valvular morphology, with varying degrees of valvular regurgitation involving both left- and right-sided valves. The involved valves exhibited leaflet thickening, with retraction of the chordae tendineae leading to malcoaptation of the valves and regurgitation. Five of the patients subsequently underwent cardiac surgery for valve replacement. The histopathological features of the valves excised were nearly identical to those seen in patients with carcinoid syndrome and those previously described with ergot alkaloid-related antimigraine drugs (plaques of proliferative myofibroblasts in an abundant extracellular myxoid or collagen matrix). After this first publication, the Food and Drug Administration (FDA) indicated that a significant number of VHD notifications had been received in association with the intake of phentermine in combination with fenfluramine as well as

with dexfenfluramine (approved for use in the USA in 1996). Thirty-three cases were indeed retrieved by notifications.

Other studies were published some months later, showing that duration of drug exposure played a significant role in the development of VHD. Thus, in the study performed by Khan et al. [7], it was found that prolonged intake of fenfluramine or dexfenfluramine led to a multiplication of the risk of VHD by 22. Data other than from the USA were published with concordant results. Thus, Jick et al. [8] retrospectively analysed the UK General Practice Research Database (GPRD) and extracted symptomatic cases of VHD confirmed by echocardiography and associated with the intake of fenfluramine or dexfenfluramine (duration of treatment 21 ± 12 months) but no cases associated with phentermine alone or obese patients who did not take appetite suppressants. This was an important consideration, as a hypothesis regarding a specific potential role for obesity itself in the development of VHD had been advanced. The 5-year cumulative incidence of valvular regurgitation was found to be 7.1 per 10,000 patient-years when fenfluramine or dexfenfluramine was taken for less than 3 months and 35 per 10,000 patient-years for a treatment duration of 4 months or more.

Studies performed later also took into account the potentially confounding factor of obesity itself and the fact that unexplained valvular regurgitations may occur spontaneously. Taking into account these possible biases, all the studies confirmed the potential of fenfluramine and dexfenfluramine to induce valvular regurgitations when administered on a long-term basis. A meta-analysis of nine published case-control pharmacoepidemiological studies by Sachdev et al. [9] compared 3769 patients with 5009 matched controls (mean age 46 years; 85% of women with a mean body mass index [BMI] of 36; mean duration of treatment 397 days). When the drug intake duration was greater than 90 days, 12% of patients presented VHDs when taking fenfluramine-type appetite suppressants compared with 5% of obese patients who were not taking these drugs (odds ratio [OR] 2.2; 95% confidence interval [CI] 1.7–2.7). Thus, one in eight patients receiving these drugs for greater than 90 days was found to have VHD, with aortic regurgitations occurring three times more frequently than mitral regurgitations.

So, much data reported in the literature support the point that fenfluramine-type appetite suppressants may induce VHD – mainly aortic regurgitation but also, although with a lower incidence, mitral restrictive regurgitation, essentially when the duration of drug intake was greater than 3 to 6 months [10], whereas pulmonary arterial hypertension may appear after a shorter treatment time. It has been reported that withdrawal of the drugs decreases the severity of regurgitation or stabilizes the valvular lesions in some of the patients involved [11]. However, several cases of fenfluramine-associated valvular disease have been reported up to 7 years after drug withdrawal [12,13].

Valvular heart disease associated with benfluorex (Mediator®)

Benfluorex (Mediator®) is the most recent drug found to be involved in inducing VHD. This drug is structurally

related to amphetamines and is partially metabolized to norfenfluramine. It was initially indicated in patients with hypertriglyceridaemia or for diabetes mellitus in overweight patients in combination with dietetic recommendations. In France, following reassessment of the benefit–risk balance in patients with hypertriglyceridaemia, the Medicine Drug Agency decided in April 2007 to limit benfluorex use to its other indication, diabetes mellitus in overweight patients ($\text{BMI} \geq 25 \text{ kg/m}^2$) in association with an appropriate diet. Benfluorex had also been widely prescribed in France as an appetite suppressant.

The first case reports of benfluorex-associated VHD were published successively in 2003, 2006, 2009 and 2010 [14–17]. The first publication described a case of multiple valve disease requiring mitral and aortic valve replacement and tricuspid valvuloplasty [17]. This case was related to intermittent and short-term intake of benfluorex. The second report [16] concerned severe mitral regurgitation associated with tricuspid regurgitation in a woman who had been treated with benfluorex for 8 years. The third case of benfluorex-associated valvulopathy was associated with a series of five pulmonary arterial hypertension cases [14].

Subsequently, two studies compared patients selected as having ‘unexplained’ mitral regurgitation with age- and sex-matched patients who had mitral regurgitation with aetiological or functional explanations [18,19]; the latter patients were used as the control group. In the first study, performed by Frachon et al. [18], 27 patients with unexplained mitral regurgitation were compared with 54 controls. The use of benfluorex was documented in 19 patients in the first group and in three in the second group, with an odds ratio of 17.1 (3.5–83) after adjustment for BMI, diabetes and dexfenfluramine intake. In a second study confirming these results [19], 22 patients with unexplained mitral regurgitation were compared with 22 of 156 patients who underwent surgery for dystrophic mitral regurgitation, matched for age, body weight and diabetes. Eight of the 22 patients (36.4%) in the first group but only one (4.5%) in the group with dystrophic valvulopathy had a history of benfluorex use. The total duration of benfluorex treatment associated with unexplained mitral regurgitation was 63 (12–175) months; the duration of benfluorex treatment was 56 months at the time of valvular disease diagnosis.

More recently, 40 cases identified retrospectively in the cardiology departments in eight hospitals in France have been reported and analysed [20]. Owing to hospital recruitment of symptomatic patients, the observations collected represent the most severe presentation of these VHDs. The cases analysed in this multicentre registry had a quite homogeneous presentation: patients were middle-aged and mainly women, with obesity and/or diabetes mellitus and exposure to benfluorex for a mean duration of 72 ± 53 months. Most patients had symptomatic heart failure. Echocardiographic analysis also identified homogeneous features in these patients. Common findings were leaflet thickening and retraction with inconstant minimal commissural fusion and rare calcifications. Subvalvular apparatus was thickened and shortened with fused chordae tendineae. These injuries resulted mainly in loss of leaflet coaptation and predominant mitral or aortic regurgitation. Indeed, mitral and aortic regurgitations were the most frequent features, whereas significant stenoses were uncommon. In four

cases (10%), organic tricuspid valve involvement was also identified and there was one case of organic pulmonary valve dysfunction. Multiple fibrotic valve diseases were present in more than 75% of patients, displaying predominantly an association of aortic and mitral regurgitations (72.5%) and leading to combined valve surgery in 11 cases (27.5%). These morphological and histological features (valvular tissue thickening and an abundant extracellular matrix of glycosaminoglycans and collagen with proliferation of myofibroblasts and smooth muscle cells) were similar to those previously reported after exposure to other appetite suppressants and ergot alkaloids.

A cohort study using two large French national databases, drawing on Health Insurance data (Caisse Nationale d'Assurance Maladie des travailleurs salariés [CNAMTS]) and diagnostic data on discharge from public and private hospitalizations (PMSI), has been recently published [21]. Data from patients aged 40 to 69 years with reimbursements for antidiabetic drugs in 2006 were analysed. The risk of hospitalization for valvular regurgitation in the 2 years following was found to be 2.5 times higher when taking benfluorex for mitral regurgitation, 4.4 times higher for aortic insufficiency and 3.9 times higher for valvular replacement surgery. The estimated numbers of hospitalizations for a diagnosis of VHD was found to be 5 for 10,000 patient-years.

The re-evaluation of the benefit–risk balance of benfluorex in light of these data led to suspension of the marketing authorization of the drug in France and then in Europe, in November and December 2009, respectively [22].

More recently, the randomized prospective REGULATE trial [23], whose results were published in 2012, included 847 patients with type II diabetes (mean age: 59 years) randomized to 1 year of treatment with a combination of either benfluorex–sulphonylurea ($n=423$) or pioglitazone–sulphonylurea ($n=424$). Echocardiography was performed at baseline, before treatment, and at 1 year in 615 of these patients. Emergence (appearance or deterioration) of valvular regurgitation was observed more frequently (27% vs 11%; $P<0.0001$) in the group treated with benfluorex (OR 2.97 [1.91–4.63]). At last, an echocardiography-based multicentre study [22] compared the frequency of left heart valve regurgitation in diabetic patients exposed to benfluorex for at least 3 months and in diabetic controls never exposed to the drug: 293 patients and 293 controls were matched for age, gender, body mass index, smoking, dyslipidaemia, hypertension and coronary artery disease. The frequency and relative risk (OR) of mild or more severe left heart valve regurgitation were significantly increased in benfluorex-exposed patients compared with controls: 31.0% vs 12.9% (OR 3.55 [2.03–6.21]) for aortic and/or mitral regurgitation; 19.8% vs 4.7% (OR 5.29 [2.46–11.4]) for aortic regurgitation; and 19.4% vs 9.6% (OR 2.38 [1.27–4.45]) for mitral regurgitation. This study therefore confirmed that the use of benfluorex is associated with a significant increase in the frequency of left heart valve regurgitation in diabetic patients.

Estimates of the number of benfluorex-associated deaths in France have been proposed as probably being higher than 500 [24] and were more recently calculated to be around 1300 due to VHD in these patients; this number is regarded as possibly underestimated [25].

Valvular heart disease associated with ergot-derived dopaminergic agonists

Two drugs of this pharmacological class are implicated: pergolide (Celance®) and cabergoline (Dostinex®). The first drug has been indicated in the treatment of Parkinson's disease (with a defined benefit against bradykinesia and rigidity); the second drug is also used as an antiparkinsonian drug in many countries but not in some countries, such as France, where it is only used to treat hyperprolactinaemic disorders.

The first three case reports describing a probable association between VHD and pergolide were published in 2002 [26]. Subsequent data suggested that the incidence was not as low as initially believed. Thus, a study performed in Belgium [27] evaluated data from 79 patients treated with pergolide and 19 patients with Parkinson's disease who had never been treated with ergot-derived dopaminergic agonists (controls). The study concluded that restrictive VHD was present in 33% of the patients treated with pergolide and in none of the controls. The VHD was more frequently mitral regurgitation and more rarely aortic or tricuspid regurgitation.

Next, two studies published simultaneously in 2007 clearly confirmed the increased risk of VHD with pergolide (as well as cabergoline when used to treat parkinsonian patients) [28,29]. The first study [28] was a large case-control analysis nested in the UK GPRD cohort (already used to evaluate the association between appetite suppressants and VHD, as previously discussed). The cohort selected for this study included 11,417 patients who had received antiparkinsonian drugs for a mean duration of 4.2 years. In this cohort, 31 patients were newly diagnosed as having cardiac regurgitation. Six of these 31 patients were treated with pergolide and six with cabergoline. The other 19 patients did not receive any dopamine agonist during the year preceding the diagnosis of valvular disease. These 31 patients were compared with 663 age- and sex-matched controls. The rate of newly diagnosed valve regurgitation was multiplied by 7.1 (95% CI 2.3–22.3) in patients treated with pergolide and by 4.9 (1.5–15.6) in patients treated with cabergoline, but was unchanged in patients treated with other dopamine agonists (lisuride, pramipexole, ropinirole). In this study, the risk was further raised with higher doses of the two drugs. These results were confirmed by the second study [29], in which the echocardiographic prevalence of VHD was studied in 155 parkinsonian patients treated with dopamine agonists (64 received pergolide, 49 received cabergoline and 42 received non-ergot-derived dopamine agonists) compared with 90 control subjects. Moderate or severe valvular regurgitation was found with a greater frequency in patients treated with pergolide (23.4%) or cabergoline (28.6%) than in patients taking non-ergot dopamine agonists (0%) or in controls (5.6%).

Concordant data have also been reported in France [30,31]. The first study [30] prospectively included 86 parkinsonian patients treated with pergolide for more than 3 months compared with 47 patients not treated with this drug. Moderate to severe regurgitations were found in 17.4% of patients treated with pergolide compared with only 4.3% of control patients. The finding of regurgitation was found to be related to the cumulative dose of pergolide. A

meta-analysis was then performed on seven comparative trials and reported an odds ratio of 3.1, the risk being statistically correlated with the pergolide cumulative dose. In another study [31], 30 patients with Parkinson's disease treated by pergolide were evaluated and compared with a control group (age- and sex-matched consecutive patients without known VHD referred to the cardiology department for various reasons). A restrictive pattern of valvular regurgitation was observed in 12/30 (40%) parkinsonian patients treated with pergolide, with heart failure symptoms in two cases. Compared with controls, aortic and mitral regurgitation occurred respectively 3.1 and 10.7 times more frequently under pergolide treatment. An increase in the frequency of tricuspid regurgitation was also found but this was not significant. In 10 of the 13 patients presenting valvular regurgitation, pergolide treatment was withdrawn. In six of these patients, the mitral regurgitation grade was found to be lower 10 to 18 months later, whereas no change was observed for aortic regurgitation.

From the data available in the literature, VHD associated with pergolide is generally plurivalvular, involving mitral valves slightly more frequently (and then aortic and tricuspid valves). Echocardiographic and histopathological lesions were found to be similar to those described in VHD due to exposure to appetite suppressants.

These data led the FDA to withdraw pergolide from the market in the USA. In many other countries, especially in Europe, pergolide continued to be marketed because the drug was considered potentially to have a specific place in the management of Parkinson's disease. However, significant limitations in the use of the drug were announced: use limited to patients with parkinsonian symptoms resistant to other dopamine agonists; echocardiography performed before drug initiation and then every 6 months; and contraindication in case of previous VHD or fibrosis. With these limitations, prescription of pergolide largely decreased and no more VHDs associated with pergolide were notified. The marketing of this drug finally stopped in France in May 2011.

Valvular heart disease associated with cabergoline when treating hyperprolactinaemic disorders

Cabergoline, an ergot-derived dopamine agonist reported as being associated with VHD when used in Parkinson's disease, is also commonly used as first-line therapy in hyperprolactinaemia patients, as it is able to normalize prolactin levels and to restore gonadal function and prolactinoma size when administered at low doses (0.5–2 mg/week) [32].

Very few case reports have been published on VHD associated with the intake of low doses of cabergoline to treat hyperprolactinaemia [33,34]. In one of these cases, a 10-year previous intake of dexfenfluramine and then bromocriptine may also be implicated.

Several pharmacoepidemiological studies have been performed to evaluate the valvular risk of long-term low doses of cabergoline used to treat hyperprolactinaemic disorders; most were unable to confirm the risk of valvular regurgitation. However, two studies found an increased prevalence of mild tricuspid regurgitation [35,36]. The clinical significance

of the data available needs to be confirmed by larger prospective studies with rigorous methodology and prolonged duration of follow-up [37].

Valvular heart disease associated with ecstasy (MDMA)

MDMA (also known as ecstasy) is used as a recreational drug (psychoactive stimulant). In 2007, Droogmans et al. reported that this drug was associated with the development of significant valvular regurgitation in long-term users (3–6 tablets/week for 6 years) with a significant correlation between dose and severity of the valvular alterations, which were very similar to those reported with pergolide and fenfluramine [38].

Mechanisms involved in drug-induced VHD

The hypothesis of a serotonergic mechanism to explain drug-induced VHD has been postulated since the first cases were reported because of their similarities to carcinoid heart disease. Serotonin is known to have mitogenic effects on fibroblasts and smooth muscle cells by upregulating transforming growth factor beta, which, in turn, stimulates glycosaminoglycan production and cell proliferation. It was initially postulated that appetite suppressants, such as fenfluramine, increase circulating serotonin concentrations by interfering with serotonin transporter proteins [1]. However, it has been shown that chronic fenfluramine use lowers plasma and platelet serotonin concentrations. It was therefore hypothesized that drug-induced VHD may be related to the stimulation of a serotonin receptor subtype. A role for 5HT_{2B} receptors, a subtype of one of the seven serotonin (5HT) receptors, has been demonstrated (Fig. 3). Indeed, methylergonovine (an active metabolite of ergotamine and methysergide) and pergolide have high affinity for 5HT_{2B} receptors. Pergolide, cabergoline and MDMA are also potent agonists at the 5HT_{2B} receptor. It has been highlighted that lisuride, an ergot-derived dopaminergic agonist like pergolide, does not induce VHD. Actually, lisuride is characterized by an antagonistic (and not agonistic) effect on 5HT_{2B} receptors [39]. Norfenfluramine (a metabolite of fenfluramine), dexfenfluramine and benfluorex have also been found to have a high affinity for 5HT_{2B} receptors [40].

Serotonin 5HT_{2B} receptors are expressed on both aortic and mitral valve leaflets (as well as in pulmonary arteries); their stimulation by 5HT_{2B} agonist drugs may result in fibroblast proliferation and collagen synthesis, and may explain the development of VHD. These lesions can occur on bioprostheses, as reported recently in a patient with similar fibrotic histopathological alterations occurring simultaneously on the mitral bioprosthesis and the native aortic valve during benfluorex therapy [41].

Recently, a model of VHD has been reported in Wistar rats exposed over 5 months to pergolide or serotonin; the rats developed valvular lesions very similar to those described in human pathology, with the same echocardiographic and histological features. The use of cyproheptadine, a 5HT_{2B} antagonist drug, prevented the development of pergolide-induced VHD in this model [42]. Such a model, as well as the

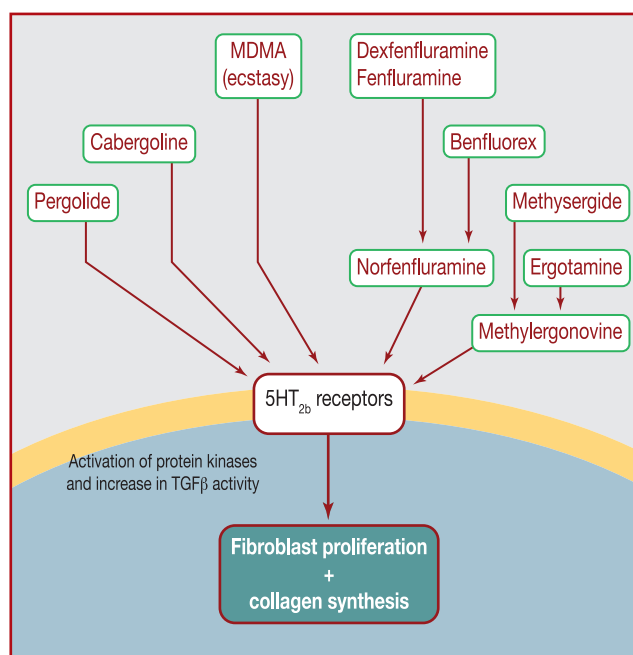


Figure 3. Mechanisms of drug-induced valvular heart disease. TGFβ: transforming growth factor beta.

search for 5HT_{2B} activity, may provide future tools that will probably be useful in evaluating the cardiac safety of new drugs as well as the evidence of 5HT_{2B} receptor agonistic potency in pharmacological in vitro assays [43].

Disclosure of interest

The authors declare that they have no conflicts of interest concerning this article.

References

- [1] Bhattacharyya S, Schapira AH, Mikhailidis DP, Davar J. Drug-induced fibrotic valvular heart disease. *Lancet* 2009;374:577–85.
- [2] Graham JR. Cardiac and pulmonary fibrosis during methysergide therapy for headache. *Am J Med Sci* 1967;254:1–12.
- [3] Misch KA. Development of heart valve lesions during methysergide therapy. *Br Med J* 1974;2:365–6.
- [4] Elangbam CS. Drug-induced valvulopathy: an update. *Toxicol Pathol* 2010;38:837–48.
- [5] Abenhaim L, Moride Y, Brenot F, et al. Appetite-suppressant drugs and the risk of primary pulmonary hypertension. International Primary Pulmonary Hypertension Study Group. *N Engl J Med* 1996;335:609–16.
- [6] Connolly HM, Crary JL, McGoon MD, et al. Valvular heart disease associated with fenfluramine-phentermine. *N Engl J Med* 1997;337:581–8.
- [7] Khan MA, Herzog CA, St Peter JV, et al. The prevalence of cardiac valvular insufficiency assessed by transthoracic echocardiography in obese patients treated with appetite-suppressant drugs. *N Engl J Med* 1998;339:713–8.
- [8] Jick H, Vasilakis C, Weinrauch LA, Meier CR, Jick SS, Derby LE. A population-based study of appetite-suppressant drugs and the risk of cardiac-valve regurgitation. *N Engl J Med* 1998;339:719–24.

- [9] Sachdev M, Miller WC, Ryan T, Jollis JG. Effect of fenfluramine-derivative diet pills on cardiac valves: a meta-analysis of observational studies. *Am Heart J* 2002;144:1065–73.
- [10] Shively BK, Roldan CA, Gill EA, Najarian T, Loar SB. Prevalence and determinants of valvulopathy in patients treated with dexfenfluramine. *Circulation* 1999;100:2161–7.
- [11] Mast ST, Jollis JG, Ryan T, Anstrom KJ, Crary JL. The progression of fenfluramine-associated valvular heart disease assessed by echocardiography. *Ann Intern Med* 2001;134:261–6.
- [12] Dahl CF, Allen MR, Urie PM, Hopkins PN. Valvular regurgitation and surgery associated with fenfluramine use: an analysis of 5743 individuals. *BMC Med* 2008;6:34.
- [13] Greffe G, Chalabreysse L, Mouly-Bertin C, et al. Valvular heart disease associated with fenfluramine detected 7 years after discontinuation of treatment. *Ann Thorac Surg* 2007;83:1541–3.
- [14] Boutet K, Frachon I, Jobic Y, et al. Fenfluramine-like cardiovascular side-effects of benfluorex. *Eur Respir J* 2009;33:684–8.
- [15] Gueffet JP, Piriou N, Trochu JN. Valvular heart disease associated with benfluorex. *Arch Cardiovasc Dis* 2010;103:342–3.
- [16] Noize P, Sauer M, Bruneval P, et al. Valvular heart disease in a patient taking benfluorex. *Fundam Clin Pharmacol* 2006;20:577–8.
- [17] Rafel Ribera J, Casanas Munoz R, Anguera Ferrando N, Batalla Sahun N, Castro Cels A, Pujadas Capmany R. [Valvular heart disease associated with benfluorex]. *Rev Esp Cardiol* 2003;56:215–6.
- [18] Frachon I, Etienne Y, Jobic Y, Le Gal G, Humbert M, Leroyer C. Benfluorex and unexplained valvular heart disease: a case-control study. *PLoS One* 2010;5:e10128.
- [19] Tribouilloy C, Rusinaru D, Henon P, et al. Restrictive organic mitral regurgitation associated with benfluorex therapy. *Eur J Echocardiogr* 2010;11:614–21.
- [20] Le Ven F, Tribouilloy C, Habib G, et al. Valvular heart disease associated with benfluorex therapy: results from the French multicentre registry. *Eur J Echocardiogr* 2011;12:265–71.
- [21] Weill A, Paita M, Tuppin P, et al. Benfluorex and valvular heart disease: a cohort study of a million people with diabetes mellitus. *Pharmacoepidemiol Drug Saf* 2010;19:1256–62.
- [22] Tribouilloy C, Rusinaru D, Marechaux S, et al. Increased risk of left heart valve regurgitation associated with benfluorex use in patients with diabetes mellitus: a multicenter study. *Circulation* 2012;126:2852–8.
- [23] Derumeaux G, Ernande L, Serusclat A, et al. Echocardiographic evidence for valvular toxicity of benfluorex: a double-blind randomised trial in patients with type 2 diabetes mellitus. *PLoS One* 2012;7:e38273.
- [24] Hill C. [Number of deaths attributable to benfluorex]. *Presse Med* 2011;40:462–9.
- [25] Fournier A, Zureik M. Estimate of deaths due to valvular insufficiency attributable to the use of benfluorex in France. *Pharmacoepidemiol Drug Saf* 2012;21:343–51.
- [26] Pritchett AM, Morrison JF, Edwards WD, Schaff HV, Connolly HM, Espinosa RE. Valvular heart disease in patients taking pergolide. *Mayo Clin Proc* 2002;77:1280–6.
- [27] Van Camp G, Flamez A, Cosyns B, Goldstein J, Perdaens C, Schoors D. Heart valvular disease in patients with Parkinson's disease treated with high-dose pergolide. *Neurology* 2003;61:859–61.
- [28] Schade R, Andersohn F, Suissa S, Haverkamp W, Garbe E. Dopamine agonists and the risk of cardiac-valve regurgitation. *N Engl J Med* 2007;356:29–38.
- [29] Zanettini R, Antonini A, Gatto G, Gentile R, Tesei S, Pezzoli G. Valvular heart disease and the use of dopamine agonists for Parkinson's disease. *N Engl J Med* 2007;356:39–46.
- [30] Corvol JC, Anzouan-Kacou JB, Fauveau E, et al. Heart valve regurgitation, pergolide use, and parkinson disease: an observational study and meta-analysis. *Arch Neurol* 2007;64:1721–6.
- [31] Dupuy D, Lesbre JP, Gerard P, Andrejak M, Godefroy O. Valvular heart disease in patients with Parkinson's disease treated with pergolide. Course following treatment modifications. *J Neurol* 2008;255:1045–8.
- [32] Valassi E, Klibanski A, Biller BM. Clinical Review: potential cardiac valve effects of dopamine agonists in hyperprolactinemia. *J Clin Endocrinol Metab* 2010;95:1025–33.
- [33] Cawood TJ, Bridgman P, Hunter L, Cole D. Low-dose cabergoline causing valvular heart disease in a patient treated for prolactinoma. *Intern Med J* 2009;39:266–7.
- [34] Chague F, Belleville I, Boujon B, Petit JM. [An aortic insufficiency diagnosed under cabergoline]. *Ann Cardiol Angeiol (Paris)* 2009;58:189–91.
- [35] Colao A, Galderisi M, Di Sarno A, et al. Increased prevalence of tricuspid regurgitation in patients with prolactinomas chronically treated with cabergoline. *J Clin Endocrinol Metab* 2008;93:3777–84.
- [36] Kars M, Delgado V, Holman ER, et al. Aortic valve calcification and mild tricuspid regurgitation but no clinical heart disease after 8 years of dopamine agonist therapy for prolactinoma. *J Clin Endocrinol Metab* 2008;93:3348–56.
- [37] Vallette S, Serri K, Serri O. Cabergoline therapy for prolactinomas: is valvular heart disease a real safety concern? *Expert Rev Cardiovasc Ther* 2010;8:49–54.
- [38] Droogmans S, Cosyns B, D'Haenen H, et al. Possible association between 3,4-methylenedioxymethamphetamine abuse and valvular heart disease. *Am J Cardiol* 2007;100:1442–5.
- [39] Hofmann C, Penner U, Dorow R, et al. Lisuride, a dopamine receptor agonist with 5-HT_{2B} receptor antagonist properties: absence of cardiac valvulopathy adverse drug reaction reports supports the concept of a crucial role for 5-HT_{2B} receptor agonism in cardiac valvular fibrosis. *Clin Neuropharmacol* 2006;29:80–6.
- [40] Rothman RB, Baumann MH, Savage JE, et al. Evidence for possible involvement of 5-HT_{2B} receptors in the cardiac valvulopathy associated with fenfluramine and other serotonergic medications. *Circulation* 2000;102:2836–41.
- [41] Ayme-Dietrich E, Lawson R, Gasser B, Dallemand R, Bischoff N, Monassier L. Mitral bioprosthesis hypertrophic scarring and native aortic valve fibrosis during benfluorex therapy. *Fundam Clin Pharmacol* 2012;26:215–8.
- [42] Droogmans S, Roosens B, Cosyns B, et al. Cyproheptadine prevents pergolide-induced valvulopathy in rats: an echocardiographic and histopathological study. *Am J Physiol Heart Circ Physiol* 2009;296:H1940–8.
- [43] Huang XP, Setola V, Yadav PN, et al. Parallel functional activity profiling reveals valvulopathogens are potent 5-hydroxytryptamine(2B) receptor agonists: implications for drug safety assessment. *Mol Pharmacol* 2009;76:710–22.