

# Recommendations on the echocardiographic assessment of aortic valve stenosis: a focused update from the European Association of Cardiovascular Imaging and the American Society of Echocardiography

**Helmut Baumgartner (chair)<sup>1\*</sup>, Judy Hung (co-chair)<sup>2</sup>, Javier Bermejo<sup>3</sup>, John B. Chambers<sup>4</sup>, Thor Edvardsen<sup>5</sup>, Steven Goldstein<sup>6</sup>, Patrizio Lancellotti<sup>7</sup>, Melissa LeFevre<sup>8</sup>, Fletcher Miller Jr<sup>9</sup>, and Catherine M. Otto<sup>10</sup>**

**Reviewers:** This document was reviewed by members of the 2014–16 EACVI Scientific Documents Committee. EACVI reviewers included: Gilbert Habib, Bernard Cosyns, Victoria Delgado, Erwan Donal, Raluca Dulgheru, Massimo Lombardi, Nuno Cardim, Kristina H Haugaa. This document was reviewed by members of the 2015–16 ASE Guidelines & Standards Committee, the 2016–17 ASE Board of Directors, and 2016–17 Executive Committee. ASE reviewers included Deborah A. Agler, Federico M. Asch, Merri L. Bremer, Benjamin Byrd, Hollie D. Carron, Frederick C. Cobey, Meryl Cohen, Keith A. Collins, Patrick H. Collier, Mary C. Corretti, Benjamin Eidem, Craig Fleishman, Neal Gerstein, Edward A. Gill, Yvonne E. Gilliland, Sandra Hagen-Ansert, Lanqi Hua, Thomas V. Johnson, Soo H. Kim, James N. Kirkpatrick, Allan L. Klein, Jonathan R. Lindner, Carol Mitchell, Tasneem Naqvi, Maryellen H. Orsinelli, Andy Pellett, Patricia A. Pellikka, Sue D. Phillip, Vera H. Rigolin, Lawrence G. Rudski, Vandana Sachdev, Anita Sadeghpour, Liza Y. Sanchez, Elaine Shea, Roman M. Sniecinski, Vincent Sorrell, Raymond F. Stainback, Cynthia Taub, Steven Walling, Neil J. Weissman, Susan E. Wiegers, David H. Wiener.

<sup>1</sup>Division of Adult Congenital and Valvular Heart Disease, Department of Cardiovascular Medicine, University Hospital Muenster, Muenster, Germany; <sup>2</sup>Division of Cardiology, Massachusetts General Hospital, Boston, MA, USA; <sup>3</sup>Hospital General Universitario Gregorio Marañón, Instituto de Investigación Sanitaria Gregorio Marañón, Universidad Complutense de Madrid and CIBERCV, Madrid, Spain; <sup>4</sup>Guy's and St. Thomas' Hospitals, London, UK; <sup>5</sup>Department of Cardiology and Center for Cardiologial Innovation, Oslo University Hospital, Oslo and University of Oslo, Oslo, Norway; <sup>6</sup>Heart Institute, Washington, District of Columbia, USA; <sup>7</sup>Universtiy of Liège Hospital, GIGA Cardiovascular Science, Heart Valve Clinic, Imaging Cardiology, Liège, Belgium and Gruppo Villa Maria Care and Research, Anthea Hospital, Bari, Italy; <sup>8</sup>Duke University Medical Center, Durham, NC, USA; <sup>9</sup>Mayo Clinic, Rochester, Minnesota, USA; and <sup>10</sup>Division of Cardiology, University of Washington School of Medicine, Seattle, WA, USA

Received 20 December 2016; editorial decision 22 December 2016; accepted 23 December 2016

\* Corresponding author. Tel: +49 251 8346110; Fax: +49 251 8346109. E-mail: helmut.baumgartner@ukmuenster.de

© The Authors, 2017. This article is being co-published in the European Heart Journal – Cardiovascular Imaging and the Journal of the American Society of Echocardiography. The articles are identical except for minor stylistic and spelling differences in keeping with each journal's style. Either citation can be used when citing this article.

Echocardiography is the key tool for the diagnosis and evaluation of aortic stenosis. Because clinical decision-making is based on the echocardiographic assessment of its severity, it is essential that standards are adopted to maintain accuracy and consistency across echocardiographic laboratories. Detailed recommendations for the echocardiographic assessment of valve stenosis were published by the European Association of Echocardiography and the American Society of Echocardiography in 2009. In the meantime, numerous new studies on aortic stenosis have been published with particular new insights into the difficult subgroup of low gradient aortic stenosis making an update of recommendations necessary. The document focuses in particular on the optimization of left ventricular outflow tract assessment, low flow, low gradient aortic stenosis with preserved ejection fraction, a new classification of aortic stenosis by gradient, flow and ejection fraction, and a grading algorithm for an integrated and stepwise approach of aortic stenosis assessment in clinical practice.

**Keywords** aortic stenosis • echocardiography • computed tomography • quantification • prognostic parameters

## Table of Contents

Abbreviations .....	255
Introduction .....	256
Aetiologies and morphologic assessment .....	257
Basic assessment of severity .....	257
Recommendations for standard clinical practice .....	257
Peak jet velocity .....	258
Mean pressure gradient .....	261
Aortic valve area .....	263
Alternative measures of stenosis severity .....	266
Simplified continuity equation .....	266
Velocity ratio and VTI ratio (dimensionless index) .....	266
AVA planimetry .....	266
Experimental descriptors of stenosis severity (not recommended for routine use) .....	266
Advanced assessment of AS severity .....	267
Basic grading criteria .....	267
Special considerations of difficult subgroups .....	267
Low flow, low gradient AS with reduced EF .....	267
Low flow, low gradient AS with preserved EF .....	269
Normal flow, low gradient AS with preserved EF .....	269
New classification of AS by gradient, flow and ejection fraction .....	270
Assessment of the left ventricle in AS .....	270
Conventional parameters of LV function .....	270
Novel parameters of LV function .....	270
LV hypertrophy .....	270
Integrated and stepwise approach to grade AS severity in clinical practice .....	271
High gradient AS track .....	271
Low gradient AS track .....	272
Associated pathologies .....	272
Aortic regurgitation .....	272
Mitral regurgitation .....	272
Mitral stenosis .....	273
Dilatation of the ascending aorta .....	273
Arterial hypertension .....	273
Prognostic markers .....	273
Follow-up assessment .....	273

## Abbreviations

AoA	aortic cross-sectional area
AR	aortic regurgitation
AS	aortic stenosis
AV	aortic valve

AVA	aortic valve area
CMR	cardiac magnetic resonance imaging
CSA	cross-sectional area
CT	computed tomography
CW	continuous-wave
CWD	continuous-wave Doppler
D	diameter of the LVOT
EF	ejection fraction
EOA	effective orifice area
GLS	global longitudinal strain
LV	left ventricle
LVOT	left ventricular outflow tract
Max	maximum
MR	mitral regurgitation
MS	mitral stenosis
MSCT	multislice CT
ΔP	pressure gradient
PR	pressure recovery
SV	stroke volume
SVi	stroke volume index
TTE	transthoracic echocardiography
TOE	transoesophageal echocardiography
V	velocity
VTI	velocity time integral
2D	two-dimensional
3D	three-dimensional

## Introduction

Aortic stenosis (AS) has become the most common primary heart valve disease and an important cause of cardiovascular morbidity and mortality. Echocardiography is the key tool for the diagnosis and evaluation of AS, and is the primary non-invasive imaging method for AS assessment. Diagnostic cardiac catheterization is no longer recommended<sup>1–3</sup> except in rare cases when echocardiography is non-diagnostic or discrepant with clinical data.

Because clinical decision-making is based on the echocardiographic assessment of the severity of AS, it is essential that standards be adopted to maintain accuracy and consistency across echocardiographic laboratories when assessing and reporting AS. Recommendations for the echocardiographic assessment of valve stenosis in clinical practice were published by the European Association of Echocardiography and the American Society of Echocardiography in 2009.<sup>4</sup> The aim of the 2009 paper was to detail the recommended approach to the echocardiographic evaluation of valve stenosis, including recommendations for specific measures of

stenosis severity, details of data acquisition and measurement, and grading of severity. These 2009 recommendations were based on the scientific literature and on the consensus of a panel of experts. Since publication of this 2009 document, numerous new studies on AS have been published, in particular with new insights into the difficult subgroup of low gradient AS. Accordingly, a focused update on the echocardiographic assessment of AS appeared to be a needed document and is now provided with this document.

As with the 2009 document, this document discusses a number of proposed methods for evaluation of stenosis severity. On the basis of an updated comprehensive literature review and expert consensus, these methods were categorized for clinical practice as:

- Level 1 Recommendation: an *appropriate and recommended* method for all patients with aortic stenosis.
- Level 2 Recommendation: a *reasonable* method for clinical use when additional information is needed in selected patients.
- Level 3 Recommendation: a method *not recommended* for routine clinical practice although it may be appropriate for research applications and in rare clinical cases.

It is essential in clinical practice to use an integrative approach when grading the severity of AS, combining all Doppler and 2D data as well as clinical presentation, and not relying on one specific measurement. Loading conditions influence velocity and pressure gradients; therefore, these parameters vary depending on intercurrent illness of patients with low vs. high cardiac output. In addition, irregular rhythms or tachycardia can make assessment of AS severity challenging. Ideally, heart rate, rhythm, and blood pressure should be stated in the echocardiographic report and haemodynamic assessment should be performed at heart rates and blood pressures within the normal range. These guidelines provide recommendations for recording and measurement of AS severity using echocardiography. However, although accurate quantification of disease severity is an essential step in patient management, clinical decision-making depends on several other factors, most

importantly, whether or not symptoms are present. This document is meant to provide echocardiographic standards and does not make recommendations for clinical management. The latter are detailed in the current guidelines for management of adults with heart valve disease.<sup>1,2</sup>

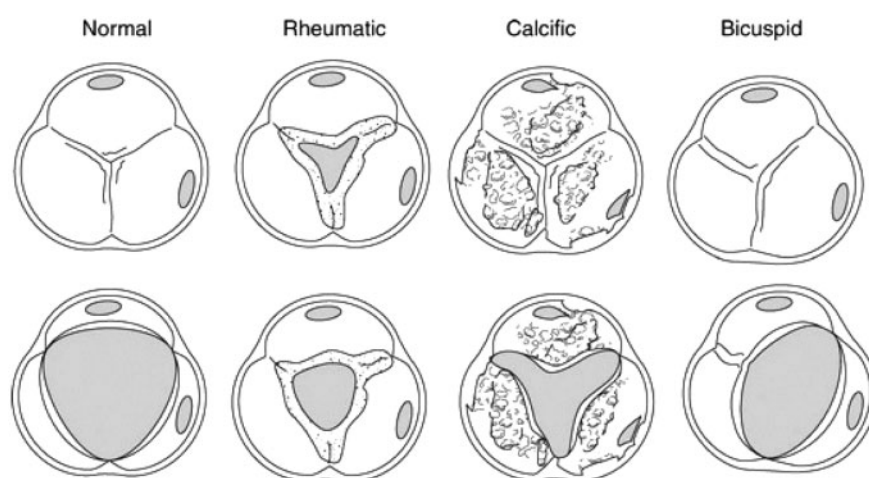
Highlights in this focused update on aortic stenosis document include:

- Optimization of LVOT assessment.
- Low flow, low gradient aortic stenosis with reduced LVEF.
- Low flow, low gradient aortic stenosis with preserved LVEF.
- New classification of AS by gradient, flow and ejection fraction.
- AS grading algorithm- an integrated and stepwise approach.

## Aetiologies and morphologic assessment

The most common causes of valvular AS are calcific stenosis of a tricuspid valve, a bicuspid aortic valve with superimposed calcific changes, and rheumatic valve disease (*Figure 1*). Congenital aortic stenosis owing to a unicuspid aortic valve is rare in adults with usually marked dysmorphic features including severe thickening and calcification and associated with significant concomitant aortic regurgitation (AR). In Europe and North America, calcific AS represents by far the most frequent aetiology with the prevalence of bicuspid vs. tricuspid aortic valves as underlying anatomy being highly age dependent.<sup>5</sup> While tricuspid valves predominate in the elderly (>75 years) bicuspid valves are more common in younger patients (age < 65 years). While rheumatic AS has become rare in Europe and North America, it is still prevalent worldwide.

Anatomic evaluation of the aortic valve is based on a combination of short- and long-axis images to identify the number of cusps, and to describe cusp mobility, thickness, and calcification. In addition, the combination of imaging and Doppler allows the determination of the level



**Figure 1** Aortic stenosis aetiology: morphology of calcific AS, bicuspid valve, and rheumatic AS (adapted from C. Otto, Principles of Echocardiography, 2007).

of obstruction: subvalvular, valvular, or supra- valvular. Transthoracic imaging is usually adequate, although transoesophageal echocardiography (TOE) may be helpful when image quality is suboptimal.

A bicuspid valve most often results from fusion of the right and left coronary cusps, resulting in a larger anterior and smaller posterior cusp with both coronary arteries arising from the anterior cusp (~80% of cases). Fusion of the right and non-coronary cusps resulting in larger right than left cusp, with one coronary artery arising from each cusp is less common (~20% of cases).<sup>6,7</sup> Fusion of the left and non-coronary cusps and valves with two equally sized cusps ("true" bicuspid valve) are rare. Diagnosis is most reliable when the two cusps are seen in systole with only two commissures framing an elliptical systolic orifice. Diastolic images may mimic three cusps when a raphe is present. Long-axis views may show an asymmetric closure line, systolic doming, or diastolic prolapse of one or both of the cusps, but these findings are less specific than a short-axis systolic image. In children, adolescents and young adults, a bicuspid valve may be stenotic without extensive calcification. However, in most adults, stenosis of a bicuspid aortic valve typically results from superimposed calcific changes, which often obscures the number of cusps, making determination of bicuspid vs. tricuspid valve difficult. Geometry and dilatation of the aortic root and ascending aorta may provide indirect hints that a bicuspid valve may be present.

Calcification of a tricuspid aortic valve is most prominent in the central and basal parts of each cusp while commissural fusion is absent, resulting in a stellate-shaped systolic orifice. Calcification of a bicuspid valve is often more asymmetric. The severity of valve calcification can be graded semi-quantitatively, as mild (few areas of dense echogenicity with little acoustic shadowing), moderate (multiple larger areas of dense echogenicity), or severe (extensive thickening and increased echogenicity with a prominent acoustic shadow). The degree of valve calcification is a predictor of clinical outcome including heart failure, need for aortic valve replacement and death.<sup>5,8</sup> Radiation induced aortic stenosis represents a special challenge as the aortic valve is often heavily calcified in a younger population making the assessment of aortic valve morphology and LVOT diameter difficult.<sup>9</sup>

Rheumatic AS is characterized by commissural fusion, resulting in a triangular systolic orifice, with thickening and calcification most prominent along the edges of the cusps. Rheumatic disease nearly always affects the mitral valve too, so that rheumatic aortic valve disease is accompanied by rheumatic mitral valve changes.

Subvalvular and supra- valvular stenosis are distinguished from valvular stenosis based on the site of the increase in velocity seen with colour or pulsed Doppler and on the anatomy of the outflow tract and aorta, respectively. Subvalvular obstruction may be fixed, owing to a discrete membrane or muscular band, with haemodynamics similar to obstruction at the valvular level. Dynamic subaortic obstruction, for example, with hypertrophic cardiomyopathy, refers to obstruction that changes in severity during ventricular ejection, with obstruction developing predominantly in mid-to-late systole, resulting in a late peaking velocity curve. Dynamic obstruction also varies with loading conditions, with increased obstruction when ventricular volumes are smaller and when ventricular contractility is increased.

Supra- valvular stenosis is uncommon and typically results from a congenital condition, such as Williams syndrome with persistent or recurrent obstruction in adulthood. In supra- valvular stenosis flow

acceleration is noted above the valve which confirms the morphologic suspicion of a narrowing typically at the sinotubular junction with or without extension into the ascending aorta.

With the advent of percutaneous aortic valve implantation, anatomic assessment has become increasingly important for patient selection and planning of the intervention. Besides underlying morphology (bicuspid vs. tricuspid) as well as extent and distribution of calcification, the assessment of annulus dimension is critical for the choice of prosthesis size. For the latter, 2D/3D TOE is superior to transthoracic echocardiography (TTE). Because multi-slice computed tomography (MSCT) has not only been shown to provide measurements of the annulus size with high accuracy, but also provides a comprehensive pre-procedural evaluation including aortic root shape, distance between coronary arteries and annulus, and anatomic details of the entire catheter route, it is frequently used now for this purpose.<sup>10,11</sup> Thus, in cases when computed tomography is performed it may not be necessary to undergo TOE. Nevertheless, accurate measurements of the aortic valve annulus can also be made by 3D-TOE. Moreover, CT may not be feasible in patients who have renal insufficiency and TOE is a reliable alternative in such patients. Pre-interventional evaluation and echocardiographic monitoring of aortic valve intervention are not part of this focused update and are covered in separate documents.

## Basic assessment of severity

Recommendations for data recording and measurements are summarized in *Table 1*. Measures of AS severity obtained by Doppler echocardiography are summarized in *Table 2*.

## Recommendations for standard clinical practice

(Level 1 Recommendation = appropriate in all patients with AS).

The primary haemodynamic parameters recommended for clinical evaluation of AS severity are:

- AS peak jet velocity.
- Mean transvalvular pressure gradient.
- Aortic valve area by continuity equation.

### Peak jet velocity

The antegrade systolic velocity across the narrowed aortic valve, or aortic jet velocity, is measured using continuous-wave (CW) Doppler (CWD) ultrasound.<sup>12–14</sup> Accurate data recording mandates the use of multiple acoustic windows in order to determine the highest velocity (apical and right parasternal or suprasternal view most frequently yield the highest velocity; rarely subcostal or supraclavicular windows yield the highest velocities). Careful patient positioning and adjustment of transducer position and angle are crucial as velocity measurement assumes a parallel intercept angle between the ultrasound beam and direction of blood flow, whereas the direction of the aortic jet in three dimensions is unpredictable and usually cannot be visualized. AS jet velocity is defined as the highest velocity signal obtained from any window after a careful examination; lower values from other views are not reported. The acoustic window that provides the highest aortic jet velocity is noted in the report and usually remains constant on sequential

**Table 1** Recommendations for data recording and measurement for AS quantitation

Data element	Recording	Measurement
LVOT diameter	<ul style="list-style-type: none"> <li>• 2D parasternal long-axis view</li> <li>• Zoom mode</li> <li>• Adjust gain to optimize the blood tissue interface</li> </ul>	<ul style="list-style-type: none"> <li>• Inner edge to inner edge</li> <li>• Mid-systole</li> <li>• Parallel and adjacent to the aortic valve or at the site of velocity measurement</li> <li>• Diameter is used to calculate a circular CSA*</li> </ul>
LVOT velocity	<ul style="list-style-type: none"> <li>• Pulsed-wave Doppler</li> <li>• Apical long-axis or five-chamber view</li> <li>• Sample volume positioned just on LV side of valve and moved carefully into the LVOT if required to obtain laminar flow curve</li> <li>• Velocity baseline and scale adjusted to maximize size of velocity curve</li> <li>• Time axis (sweep speed) 50–100 mm/s</li> <li>• Low wall filter setting</li> <li>• Smooth velocity curve with a well-defined peak and a narrow velocity range at peak velocity</li> </ul>	<ul style="list-style-type: none"> <li>• Maximum velocity from peak of dense velocity curve</li> <li>• VTI traced from modal velocity</li> </ul>
AS jet velocity	<ul style="list-style-type: none"> <li>• CW Doppler (dedicated transducer)</li> <li>• Multiple acoustic windows (e.g. apical, suprasternal, right parasternal)</li> <li>• Decrease gain, increase wall filter, adjust baseline, curve and scale to optimize signal</li> <li>• Gray scale spectral display with expanded time scale</li> <li>• Velocity range and baseline adjusted so velocity signal fits but fills the vertical scale</li> </ul>	<ul style="list-style-type: none"> <li>• Maximum velocity at peak of dense velocity curve. Avoid noise and fine linear signals</li> <li>• VTI traced from outer edge of dense signal</li> <li>• Mean gradient calculated from traced velocity curve</li> <li>• Report window where maximum velocity obtained</li> </ul>
Valve anatomy	<ul style="list-style-type: none"> <li>• Parasternal long- and short-axis views</li> <li>• Zoom mode</li> </ul>	<ul style="list-style-type: none"> <li>• Identify number of cusps in systole, raphe if present</li> <li>• Assess cusp mobility and commissural fusion</li> <li>• Assess valve calcification</li> </ul>

\*see text for the limitations of the assumption of a circular LVOT shape.

studies in an individual patient, prior to intervention. Occasionally, colour Doppler is helpful to avoid recording the CWD signal of an eccentric mitral regurgitation (MR) jet, but is usually not helpful for AS jet direction. 'Angle correction' should not be used because it is likely to introduce more error, given the unpredictable jet direction.

A dedicated small dual-crystal CWD transducer (pencil or PEDOF-pulse echo Doppler flow velocity meter probe) is strongly recommended both because of its higher signal-to-noise ratio and because it allows optimal transducer positioning and angulation, particularly when suprasternal and right parasternal windows are used. However, when flow velocity is low (< 3 m/s) and cusp opening is well seen, a combined imaging-Doppler transducer may be adequate.

The spectral Doppler signal is recorded with the spectrogram baseline and the velocity scale adjusted so the signal fills, but fits, on the vertical axis, and with a time scale on the x-axis of 50–100 mm/s. Wall (high-pass) filters are set at a high level and gain is decreased to optimize identification of the velocity curve from the spectrogram envelope. A grayscale signal intensity look-up table is used because this scale maps signal strength using a decibel scale that allows visual separation of noise and transit time effect from the velocity signal. In addition, all of the validation and inter-observer variability studies have been performed using this mode. Colour scales for CW

Doppler have different approaches to matching signal strength to colour hue or intensity and are not recommended unless a decibel scale can be verified. In case of poor acoustic quality, the use of echo contrast media has been suggested<sup>31,32</sup> but is not used in many echocardiography laboratories. In case of its use, proper machine settings (e.g. adequate adjustment gain lowering) are crucial to avoid artefacts and overestimation of velocities.

A smooth velocity curve with a dense outer edge and clear maximum velocity should be recorded. The maximum velocity is measured at the outer edge of the dark signal; fine linear signals at the peak of the curve are owing to transit-time effects and should not be included in measurements. The outer edge of the spectral Doppler envelope is traced (*Figure 2*) to provide both the velocity–time integral (VTI) for the continuity equation and the mean gradient (see below).

Three or more beats should be averaged for patients in sinus rhythm.

Averaging of more beats is mandatory with irregular rhythms (at least 5 consecutive beats). Special care must be taken to select representative sequences of beats and to avoid post-extrasystolic beats.

The shape of the CWD velocity curve is helpful in distinguishing the level and severity of obstruction. Although the time course of the velocity curve is similar for fixed obstruction at any level (valvular,

**Table 2** Measures of AS severity obtained by Doppler-echocardiography

Units	Formula/method	Cut-off for severe	Concept	Advantages	Limitations
AS jet velocity <sup>12-14,15</sup>	Direct measurement	4.0	Velocity increases as stenosis severity increases	Direct measurement of velocity. Strongest predictor of clinical outcome	<ul style="list-style-type: none"> <li>Correct measurement requires parallel alignment of ultrasound beam</li> <li>Flow dependent.</li> <li>Accurate pressure gradients depend on accurate velocity data</li> <li>Flow dependent</li> </ul>
Mean gradient <sup>12-14</sup>	$\Delta P = \Sigma 4v^2 / N$	40	Pressure gradient calculated from velocity using the Bernoulli equation	<ul style="list-style-type: none"> <li>Mean gradient is obtained by tracing the velocity curve</li> <li>Units comparable to invasive measurements</li> <li>Measures effective orifice area</li> <li>Feasible in nearly all patients</li> <li>Relatively flow independent</li> </ul>	<ul style="list-style-type: none"> <li>Requires LVOT diameter and flow velocity data, along with aortic velocity.</li> <li>Measurement error more likely</li> </ul>
Continuity equation valve area <sup>16-18</sup>	$AVA = (CSA_{LVOT} \times VTI_{LVOT}) / VTI_{AV}$	1.0	Volume flow proximal to and in the stenotic orifice is equal		
Simplified continuity equation <sup>18,19</sup>	$AVA = (CSA_{LVOT} \times V_{LVOT}) / V_{AV}$	1.0	The ratio of LVOT to aortic velocity is similar to the ratio of VTIs with native aortic valve stenosis	Uses more easily measured velocities instead of VTIs	Less accurate if shape of velocity curves is atypical
Velocity ratio <sup>19,20</sup>	$VR = \frac{V_{LVOT}}{V_{AV}}$	0.25	Effective AVA expressed as a proportion of the LVOT area	Doppler-only method. No need to measure LVOT size, less variability than continuity equation	Limited longitudinal data. Ignores LVOT size variability beyond patient size dependence
Planimetry of anatomic valve area <sup>21,22</sup>	TTE, TOE, 3D-echo	1.0	Anatomic (geometric) CSA of the aortic valve orifice as measured by 2D or 3D echo	Useful if Doppler measurements are unavailable	Contraction coefficient (anatomic/effective valve area) may be variable. Difficult with severe valve calcification
LV % stroke work loss <sup>23</sup>	$\%SWL = \frac{\Delta P}{\Delta P + SBP} \cdot 100$	25	Work of the LV wasted each systole for flow to cross the aortic valve, expressed	Very easy to measure. Related to outcome in one longitudinal study	Flow-dependent. Limited longitudinal data

Continued

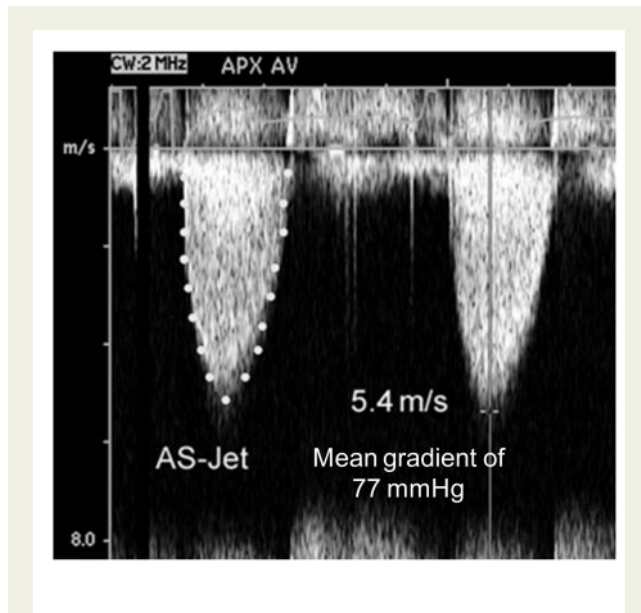
**Table 2** Continued

	Units	Formula/method	Cut-off for severe	Concept	Advantages	Limitations
Recovered pressure gradient <sup>24,25</sup>	mmHg	$P_{\text{distal}} - P_{\text{vc}} = 4 \cdot v^2 \cdot 2 \cdot \frac{\text{AVA}}{\text{AoA}} \cdot \left(1 - \frac{\text{AVA}}{\text{AoA}}\right)$	-	as a % of total systolic work Pressure difference between the LV and the aorta, slightly distal to the vena contracta, where distal pressure has increased	Closer to the global haemodynamic burden caused by AS in terms of adaptation of the cardiovascular system. Relevant at high flow states and in patients with small ascending aorta	Introduces complexity and variability related to the measurement of the AoA. No prospective studies showing real advantages over established methods
Energy loss index <sup>26</sup>	cm <sup>2</sup> /m <sup>2</sup>	$\text{ELI} = \frac{(\text{AVA}_{\text{AoA}}/\text{AoA} - \text{AVA}_{\text{BSA}})}{\text{BSA}}$	0.5	Equivalent to the concept of AVA but correcting for distal recovered pressure in the ascending aorta	(As above) Most exact measurement of AS in terms of flow-dynamics. Increased prognostic value in one longitudinal study	Introduces complexity and variability related to the measurement of the AoA
Valvulo-arterial impedance <sup>27</sup>	mmHg/mL/m <sup>2</sup>	$Z_{\text{VA}} = \frac{\Delta P_{\text{vc}} + \text{SBP}}{\text{SV}}$	5	Global systole load imposed to the LV, where the numerator represents an accurate estimation of total LV pressure	Integrates information on arterial bed to the haemodynamic burden of AS, and systemic hypertension is a frequent finding in calcific-degenerative disease	Although named 'impedance', only the steady-flow component (i.e. mean resistance) is considered. No longitudinal prospective study available
Aortic valve resistance <sup>28,29</sup>	Dynes/cm <sup>2</sup>	$\text{AVR} = \frac{\Delta P}{Q} = \frac{4v^2}{r_{\text{cor}}^3 v_{\text{cor}}}$	280	Resistance to flow caused by AS, assuming the hydrodynamics of a tubular (non flat) stenosis	Initially suggested to be less flow-dependent in low-flow AS, but subsequently shown to not be true	Flow dependence. Limited prognostic value. Unrealistic mathematic modelling of flow-dynamics of AS
Projected valve area at normal flow rate <sup>30</sup>	cm <sup>2</sup>	$\text{AVA}_{\text{proj}} = \text{AVA}_{\text{rest}} + \text{VC} \cdot (250 - Q_{\text{rest}})$	1.0	Estimation of AVA at normal flow rate by plotting AVA vs. flow and calculating the slope of regression (DSE)	Accounts for the variable changes in flow during DSE in low flow, low gradient AS, provides improved interpretation of AVA changes	Clinical impact still to be shown. Outcome of low-flow AS appears closer related to the presence/absence of LV contractility reserve

Recommendation for clinical application: (1) appropriate in all patients with AS (yellow); (2) reasonable when additional information is needed in selected patients (green); and (3) not recommended for clinical use (blue).  
 VR, velocity ratio; TVI, time-velocity integral; LVOT, LV outflow tract; AS, AS jet; TTE and TOE, transthoracic and transoesophageal echocardiography; SWL, stroke work loss; DP, mean transvalvular systolic pressure gradient; SBP, systolic blood pressure;  $P_{\text{distal}}$ , pressure at the ascending aorta;  $P_{\text{vc}}$ , pressure at the vena contracta; AVA, continuity-equation-derived aortic valve area; v, velocity; AoA, cross-sectional area of the ascending aorta; ELI, energy-loss coefficient index; BSA, body-surface area; AVR, aortic valve resistance; Q, mean systolic transvalvular flow-rate;  $\text{AVA}_{\text{proj}}$ , projected aortic valve area;  $\text{AVA}_{\text{rest}}$ , AVA at rest; VC, valve compliance derived as the slope of regression line fitted to the AVA versus Q plot;  $Q_{\text{rest}}$ , flow at rest; DSE, dobutamine stress echocardiography; N, number of instantaneous measurements.

subvalvular, or supra-valvular), the maximum velocity occurs later in systole and the curve is more rounded in shape with more severe obstruction. With mild obstruction, the peak is in early systole with a triangular shape of the velocity curve, compared with the rounded curve with the peak moving towards mid systole in severe stenosis,

reflecting a high gradient throughout systole. The shape of the CWD velocity curve also can be helpful in determining whether the obstruction is fixed or dynamic. Dynamic subaortic obstruction shows a characteristic late-peaking velocity curve, which is usually concave upward in early systole (Figure 3).



**Figure 2** Continuous-wave Doppler of severe aortic stenosis jet showing measurement of maximum velocity and tracing of the velocity curve to calculate mean pressure gradient.

### Mean pressure gradient

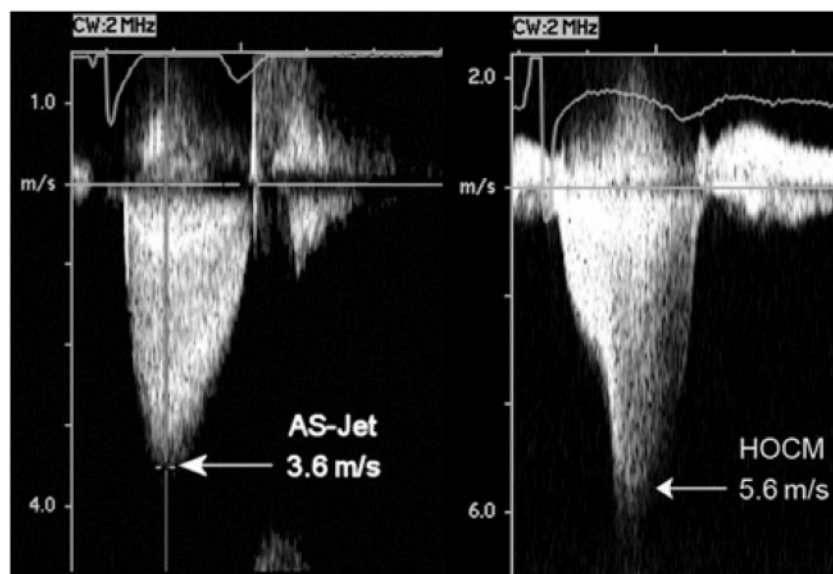
The pressure difference between the left ventricle (LV) and aorta in systole, or transvalvular aortic gradient, is another standard measure of stenosis severity.<sup>12–14</sup> Gradients are calculated from velocity information, and therefore the peak gradient obtained from the peak velocity does not add additional information when compared with peak velocity. However, the calculation of the mean gradient, the average gradient across the valve occurring during the entire systole, has potential advantages and should be reported. Although there is overall good correlation between peak gradient and mean gradient, this relationship depends on the shape of the velocity curve, which varies with stenosis severity and flow rate. Transaortic pressure gradient ( $\Delta P$ ) is calculated from velocity ( $v$ ) using the simplified Bernoulli equation as:

$$\Delta P = 4v^2.$$

The maximum gradient is calculated from maximum velocity:

$$\Delta P_{\max} = 4v^2_{\max}.$$

The mean gradient is calculated by averaging the instantaneous gradients over the ejection period, a function included in currently available clinical instrument measurement packages using the traced velocity curve. Importantly, the mean gradient requires averaging of instantaneous mean gradients and cannot be calculated from the mean velocity.



**Figure 3** An example of moderate aortic stenosis (left) and dynamic outflow obstruction in hypertrophic obstructive cardiomyopathy (right). Note the different shapes of the velocity curves and the later maximum velocity with dynamic obstruction.



This clinical (simplified) equation has been derived from the more complex Bernoulli equation by assuming that viscous losses and acceleration effects are negligible and by using an approximation for the constant that relates to the mass density of blood, a conversion factor for measurement units. In addition, the simplified Bernoulli equation assumes that the proximal velocity can be ignored, a reasonable assumption when this velocity is  $<1$  m/s because squaring a number  $<1$  makes it even smaller. When the proximal velocity is over 1.5 m/s or the transvalvular velocity is  $<3.0$  m/s, the proximal velocity should be included in the Bernoulli equation when calculating maximum gradients so that

$$\Delta P_{\max} = 4(v_{\max}^2 - v_{\text{proximal}}^2).$$

It is more problematic to include proximal velocity in mean gradient calculations as each point on the ejection curve for the proximal and jet velocities would need to be matched and this approach is not used clinically. In this situation, maximum velocity and gradient should be used to grade stenosis severity.

#### Sources of error for pressure gradient calculations

Misalignment of the ultrasound beam with the AS jet results in significant underestimation of jet velocity and an even greater underestimation of pressure gradient, owing to the squared relationship between velocity and pressure difference. This highlights the importance of using multiple acoustic windows (as detailed above) for the CWD assessment of AS. Inadvertent recording of MR jet and neglect of an elevated proximal velocity are other limitations of transaortic pressure gradient calculations. It is important to distinguish the AS jet from MR (see Mitral regurgitation section).

There are two additional concerns, related to comparing pressure gradients calculated from Doppler velocities to pressures measured at cardiac catheterization. First, the peak gradient calculated from the maximum Doppler velocity represents the maximum instantaneous pressure difference across the valve, not the difference between the peak left ventricular (LV) and peak aortic pressure that is commonly measured from the pressure tracings. The peak LV and peak aortic pressure do not occur at the same point in time; so, this difference does not represent a physiological measurement and is less than the maximum instantaneous pressure difference.

The second concern is the phenomenon of pressure recovery (PR). The conversion of potential energy to kinetic energy across a narrowed valve results in a high velocity and a drop in pressure. However, distal to the orifice, flow decelerates again. Although some of the kinetic energy dissipates into heat owing to turbulence and viscous losses, some of the kinetic energy will be reconverted into potential energy, which causes an increase in measured static pressure referred to as PR. PR is greatest in stenoses with gradual distal widening, because occurrence of turbulence is then reduced. In general, aortic stenosis, with its abrupt widening from the small orifice to the larger aorta has an unfavourable geometry for PR. However, PR (in mmHg) can be important for some patients with AS. It can be calculated from the Doppler gradient that corresponds to the initial pressure drop across the valve (i.e.  $4v^2$ ), the effective orifice area (EOA) as given by the continuity equation and the cross-sectional area of the ascending aorta (AoA), by the following equation:  $\text{PR} = 4v^2 \times 2\text{EOA}/\text{AoA} \times (1 - \text{EOA}/\text{AoA})$ .<sup>24</sup> Thus, PR is basically related to the

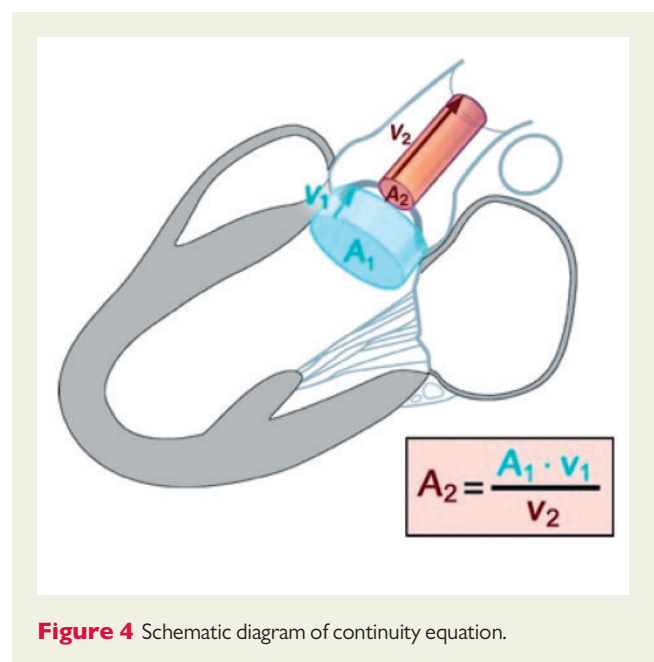
ratio of EOA/AoA. As a relatively small EOA is required to create a relevant gradient, AoA must also be relatively small to end up with a ratio favouring PR. For clinical purposes, aortic size, therefore, is an important determinant and PR should be taken into account primarily in patients with a diameter of the ascending aorta  $<30$  mm.<sup>24</sup> In most adults with native AS, the magnitude of PR is small and can be ignored as long as the diameter of the ascending aorta (at its maximally imaged point) is  $>30$  mm. However, when the ascending aorta is  $<30$  mm, one should be aware that the initial pressure drop from LV to the vena contracta, as reflected by Doppler measurement, may be significantly higher than the actual net pressure drop between the LV and the ascending aorta, which represents the pathophysiologically relevant measurement.<sup>24</sup> Therefore, if the magnitude of PR is significant, the aortic valve gradient may be overestimated by echo as it does not incorporate PR. PR may be clinically relevant particularly in congenital AS. Another clinical scenario where PR can be important is in the presence of bileaflet mechanical valves where it can account for falsely elevated prosthetic valve gradients.

#### Aortic valve area

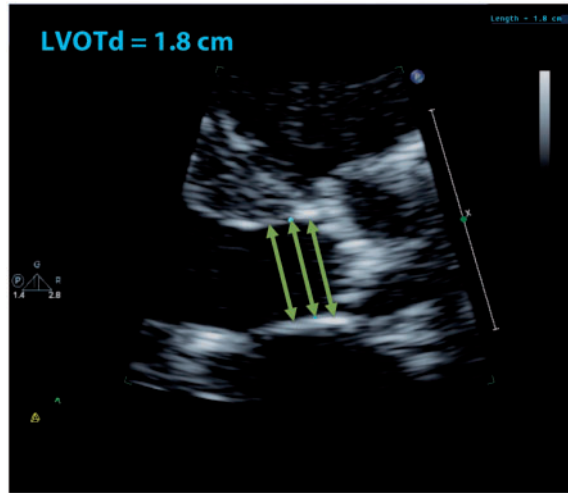
Doppler velocity and pressure gradients are flow dependent. For a given orifice area, velocity, and gradient increase with an increase in transaortic flow rate, and decrease with a decrease in flow rate. Calculation of the stenotic orifice area or effective aortic valve area (AVA) is particularly important when flow rates are very low or very high, although even the degree of valve opening varies to some degree with flow rate (see below).

AVA is calculated by using the continuity-equation (Figure 4) which is based on the concept that the stroke volume (SV) ejected through the LV outflow tract (LVOT) all passes through the stenotic orifice (AVA) and thus SV at valve orifice level is equal to the LVOT SV:

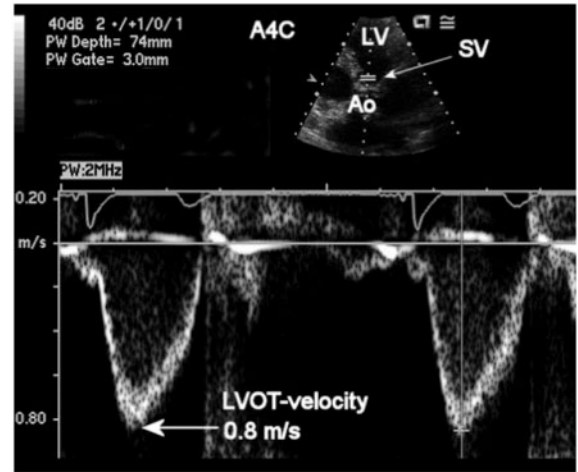
$$\text{SV}_{\text{AV}} = \text{SV}_{\text{LVOT}}.$$



**Figure 4** Schematic diagram of continuity equation.



**Figure 5** Left ventricular outflow tract diameter (LVOTd) is measured in a zoomed parasternal long-axis view in mid-systole from the white-black interface (inner-to-inner) of the septal endocardium to the anterior mitral leaflet, parallel to the aortic valve plane. Some experts prefer to measure within 0.3–1.0 cm of the valve orifice whereas others prefer the measurement at the annulus level (see text). Note that in many patients, as in this case, the LV outflow tract is relatively rectangular within 1 cm of the aortic annulus. Green double headed arrows show the LVOTd measurement at the annulus and with different distances from it yielding identical measurements in this patient.



**Figure 6** Left ventricular outflow tract (LVOT) velocity is measured from the apical approach either in an apical long-axis view or an anteriorly angulated four-chamber view (as shown here). Using pulsed-Doppler the sample volume (SV), with a length (or gate) of 3–5 mm, is positioned on the LV side of the aortic valve, just proximal to the region of flow acceleration into the jet. An optimal signal shows a smooth velocity curve with a narrow velocity range at each time point. Maximum velocity is measured as shown. The VTI is measured by tracing the modal velocity (middle of the dense signal) for use in the continuity equation or calculation of SV.

Because volume flow through any cross-sectional area (CSA) is equal to the CSA times flow velocity over the ejection period (the VTI of the systolic velocity curve), this equation can be rewritten as:

$$AVA \times VTI_{AV} = CSA_{LVOT} \times VTI_{LVOT}.$$

Solving for AVA yields the continuity equation<sup>20,33</sup>

$$AVA = \frac{CSA_{LVOT} \times VTI_{LVOT}}{VTI_{AV}}.$$

Standard calculation of continuity-equation valve area requires three measurements:

- AS jet velocity by CWD.
- LVOT diameter for calculation of the CSA.
- LVOT velocity recorded with pulsed Doppler.

AS jet velocity should be recorded with CWD and the VTI is measured as described above.

*LV outflow tract SV*

Accurate SV calculations depend on precisely measuring the cross-sectional LVOT area and LVOT velocity. The current standard approach to estimate the LVOT CSA that is still commonly used is based on LVOT diameter measurements. LVOT diameter is measured in a parasternal long-axis view from the inner edge to inner

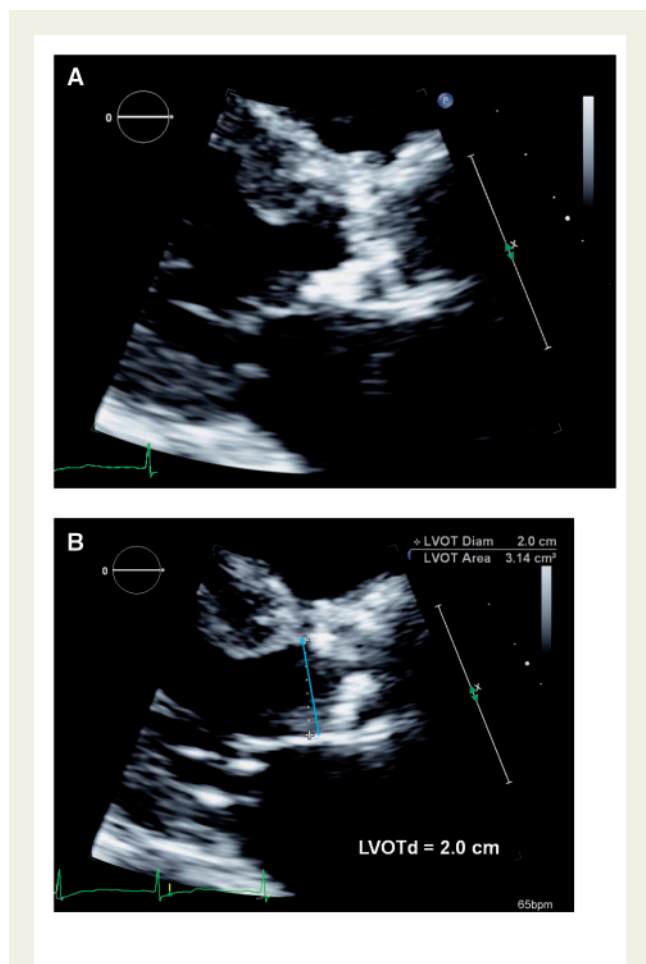
edge of the septal endocardium, and the anterior mitral leaflet in mid-systole (Figure 5). Diameter measurements are most accurate using the zoom mode with careful angulation of the transducer and with gain and processing adjusted to optimize the images. Usually three or more beats are averaged in sinus rhythm, averaging of more beats is appropriate with irregular rhythms (at least five consecutive beats). With careful attention to the technical details, the LVOT diameter can be measured in most patients. In current practice, the CSA of the LVOT is usually calculated as the area of a circle:

$$CSA_{LVOT} = \pi \left( \frac{D}{2} \right)^2$$

where *D* is the LVOT diameter.

Although a circular assumption for LVOT provides a reasonable approach that has been validated in experimental and human studies, 3D echo and CT have shown that the LVOT area is not truly circular but more elliptical (see under Limitations of the ‘standard approach’ continuity-equation valve area section for more details).

LVOT velocity is recorded with pulsed Doppler from an apical approach, in either the anteriorly angulated four-chamber view (5-chamber view) or in the apical long-axis view. The pulsed Doppler sample volume is positioned just proximal to the aortic valve. When the sample volume is optimally positioned, the recording (Figure 6) shows a smooth velocity curve with a well-defined peak, and narrow band of velocities throughout systole. This may not be the case in many patients with significant AS when the sample volume is



**Figure 7** (A) A patient example in which calcification protruding into the LVOT might yield an incorrectly small LVOT diameter, because the calcium may not extend circumferentially around the annulus perimeter. (B) A slightly altered view avoids localized calcification and yields a larger and more accurate diameter. (With permission from Steve Goldstein from ASE's Comprehensive Echocardiography, Ch 95).

positioned at the annulus, owing to flow convergence resulting in spectral dispersion at this level. In many cases, the sample volume must be slowly moved towards the apex until a smooth velocity curve is obtained. The VTI is then measured by tracing the instantaneous dense modal velocities throughout systole.<sup>16</sup> Although the LVOT velocity signal can be seen 'within' the high velocity aortic jet on the CWD recording, this velocity curve is not recommended for calculation of SV or in the continuity equation because higher velocities in the flow convergence region proximal to the stenosis contribute to this signal.

Ideally, the LVOT diameter measurement should be made at the same anatomic level as the velocity recording. When a smooth velocity curve can be obtained at the aortic annulus, this site is preferred (i.e. particularly in congenital AS with a doming valve). However, flow acceleration at the annulus level and even more proximally may occur, particularly in patients with calcific AS, so that it may be necessary to move the sample volume apically by 0.5–1.0 cm to obtain a laminar flow curve without spectral dispersion. In this situation, the

LVOT diameter can be measured at the same distance from the valve as the Doppler sample volume position (Figure 5). Fortunately, in most patients the LVOT diameter does not change much in the 1 cm proximal to the valve so that results are similar with either measurement location (Figure 5). The advantages of diameter measurement at the annulus level are (i) higher measurement reproducibility owing to clear anatomic landmarks, (ii) easier to ensure diameter and Doppler data are recorded at the same level by showing the aortic closing click in the Doppler signal, and (iii) better correlation with the annulus measurement needed for sizing transcatheter valves. However, there is no general consensus and many laboratories measure the diameter routinely at the annulus level whereas others measure more apically in the LVOT, depending on the flow pattern in each patient.

Challenges in measurement of LVOT diameter include: (i) in some patients calcium may extend from the aortic annulus to the base of the anterior mitral leaflet. Figure 7A illustrates a case in which calcification protruding into the LVOT might yield an incorrectly small LVOT diameter, because the calcium may not extend circumferentially around the annulus perimeter. Figure 7B illustrates how a slightly altered view avoids localized calcification and yields a larger and more accurate diameter. (ii) In patients with a 'sigmoid septum' the LVOT diameter measured apically from the annulus will often appear smaller than the flow area at the annulus. (iii) Ideally, LVOT diameter should be measured in mid-systole, at the same time in the cardiac cycle as the maximum LVOT velocity. However, sometimes image quality is suboptimal in mid-systole, and the outflow tract is imaged more clearly at end-diastole.<sup>34</sup> A practical approach is to measure the LVOT in the systolic frame that yields the largest diameter.

#### Limitations of the 'standard approach' continuity-equation valve area

The clinical measurement variability for continuity-equation effective AVA depends on the variability in each of the three measurements, including both the variability in acquiring the data and variability in measuring the recorded data. AS jet and LVOT velocity measurements have a very low intra- and inter-observer variability (~3–4%) both for data recording and measurement in an experienced laboratory. However, the measurement variability for LVOT diameter ranges from 5 to 8%. When LVOT diameter is squared for the calculation of CSA, it becomes the greatest potential source of measurement error in the continuity equation. When transthoracic images are not adequate for the measurement of LVOT diameter, TOE measurement is recommended if this information is needed for clinical decision-making.

Another important limitation is the assumption of a circular shape of the LVOT. Although, it has long been recognized that the LVOT is somewhat elliptical, rather than circular resulting in underestimation of LVOT CSA and in consequence underestimation of SV and eventually AVA (on average 0.2 cm<sup>2</sup> in one study),<sup>17</sup> more attention has been focused on this issue with the advent of transcatheter aortic valve implantation, particularly for selection of valve type and size prior to implantation. MSCT studies have now confirmed that the aortic valve annulus as well as LVOT are elliptical in most patients, which has led to the use of this approach for valve sizing at most institutions. However, echocardiography remains the standard for the measurement of AS severity because these parameters have been shown to be strong predictors of clinical outcomes, despite assuming a circular LVOT shape in the continuity equation. Recent data suggest

that more precise measurement of AVA using MSCT LVOT area may be of particular importance in low gradient AS to avoid misclassification of AS severity but further validation of this approach is needed.<sup>35</sup> 3D echocardiography may also provide more accurate assessment of LVOT area as it can be directly planimetered and thus avoid the underestimation of AVA when using a circular assumption for LVOT.<sup>36–39</sup> 3D echo measurement of LVOT area can thus be an alternative to MSCT to provide more accurate LVOT and AVA calculation. An additional advantage of 3D echo is that it can be readily acquired at the time of the 2D echo study, avoiding the need for obtaining an alternate imaging study to assess the LVOT. A limitation of 3D echo, however, remains decreased spatial resolution compared with 2D echo and MSCT.

Accuracy of SV measurements in the outflow tract also assumes laminar flow with a spatially flat profile of flow (e.g. velocity is the same in the centre and at the edge of the flow stream). When subaortic flow velocities are abnormal, for example, with dynamic subaortic obstruction or a subaortic membrane, SV calculations at this site are not accurate. With combined stenosis and regurgitation, high subaortic flow rates may result in a skewed flow profile across the outflow tract that may limit the accuracy. When LVOT velocity must be measured with some distance to annulus owing to flow convergence, the velocity profile may no longer be flat but rather skewed with highest velocities present at the septum. Placement of the sample volume in the middle of the LVOT cross-section may nevertheless give a measurement reasonably close to the average. Placement closer to the septum or the mitral anterior leaflet, will yield higher or lower measurements, respectively.

In the rather rare patient with a dilated LVOT, centrally measured velocities may also be significantly higher than the average velocity across the LVOT, which may result in SV and AVA overestimation. An unexpected high SV that appears discrepant to the other findings in such a patient may be an indication that LVOT dilatation is contributing to an erroneous measurement.

Despite all these limitations continuity-equation valve area calculations have been well validated in both clinical and experimental studies.<sup>19,20,33</sup> In addition, continuity-equation valve areas have been reported as a valuable parameter for prediction of clinical outcome and for clinical decision-making.<sup>15,40</sup> Of course, valve area calculations are dependable only when there is careful attention to technical aspects of data acquisition and measurement as detailed above.

In addition, there are some theoretical concerns about continuity-equation valve areas.

First, the continuity-equation measures the effective valve area—the area of the flow stream as it passes through the valve (the vena contracta)—not the anatomic valve area. The effective AVA is smaller than the anatomic valve area owing to contraction of the flow stream in the orifice, as determined by the contraction and discharge coefficients for a given orifice geometry.<sup>41</sup> Although, the difference between effective and anatomic valve area may account for some of the discrepancies between Doppler continuity equation and catheterization Gorlin equation valve areas, there now are ample clinical-outcome data validating the use of the continuity equation. The weight of the evidence now supports the concept that effective, not anatomic, orifice area is the primary predictor of clinical outcome.

The second potential limitation of valve area, as a measure of stenosis severity, is the observed change in valve area with change in flow

rate.<sup>42,43</sup> In adults with AS and normal LV function, the effects of flow rate are minimal and resting effective valve area calculations are accurate. However, this effect may be significant when concurrent LV dysfunction results in decreased cusp opening and a small EOA even though severe stenosis is not present. The most extreme example of this phenomenon is the lack of aortic valve opening when a ventricular assist device is present. Another example is the decreased opening of normal cusps seen frequently with severe LV systolic dysfunction and low flow state. However, the effect of flow rate on valve area can be used in this condition to identify those with severe AS, as discussed below.

#### Serial measurements

When serial measurements are performed during follow-up, any significant changes in results should be checked in detail:

- Make sure that aortic jet velocity is recorded from the same window with the same quality (always report the window where highest velocities can be recorded).
- When effective AVA changes, look for changes in the different components incorporated in the equation. LVOT size rarely changes over time in adults under baseline stable haemodynamic conditions. This is a common source of error and may be an argument for using the same LVOT diameter.

## Key points

- (1) The three primary haemodynamic parameters recommended for clinical evaluation of AS severity are (i) AS peak jet velocity, (ii) mean aortic transvalvular pressure gradient, and (iii) valve area by continuity equation.
- (2) AS peak jet velocity:
  - A peak gradient  $\geq 4$  m/s is consistent with severe aortic stenosis.
  - AS peak jet velocity should be obtained in multiple views.
  - A dedicated small dual-crystal CWD transducer is strongly recommended.
- (3) Mean aortic transvalvular pressure gradient:
  - A mean gradient of  $\geq 40$  mmHg is consistent with severe aortic stenosis.
  - The mean gradient is calculated by averaging the instantaneous gradients over the ejection period. Importantly, the mean gradient requires averaging of instantaneous mean gradients and cannot be calculated from the mean velocity.
- (4) A common source of error for gradient measurement is misalignment of the beam, highlighting the importance of using multiple acoustic windows for the CW Doppler assessment of AS.
- (5) AVA:
  - An AVA of  $< 1.0$  is consistent with severe aortic stenosis.
  - AVA by continuity-equation calculation has been well validated in both clinical and experimental studies and has been reported as a valuable parameter for prediction of clinical outcome and for clinical decision-making.
  - LVOT diameter is measured in a parasternal long-axis view from the inner edge to inner edge of the septal endocardium, and the anterior mitral leaflet in mid-systole (Figure 5).
  - LVOT velocity is recorded with pulsed Doppler from an apical approach, in either the anteriorly angulated four-chamber view (five-chamber view) or in the apical long-axis view. The pulsed Doppler sample volume is positioned just proximal to the aortic valve (Figure 6).

- When a smooth velocity curve can be obtained at the aortic annulus, this site is preferred for LVOT measurement. However, flow acceleration at the annulus level may occur so that it may be necessary to move the sample volume apically by 0.5–1.0 cm to obtain a laminar flow curve without spectral dispersion.
- One major limitation of the standard continuity equation is the assumption of a circular outflow tract shape. Because it is more or less elliptical LVOT area may be underestimated and as consequence flow and AVA will be underestimated, too. Direct planimetry of the LVOT (3D TEE or MSCT) can avoid this source of error.

## Alternative measures of stenosis severity

(Level 2 recommendation = reasonable when additional information is needed in selected patients).

### Simplified continuity equation

The simplified continuity equation is based on the concept that in native aortic valve stenosis the shapes of the velocity curves in the LVOT and aorta are similar, so that the ratio of LVOT VTI to aortic jet VTI is nearly identical to the ratio of the LVOT maximum velocity to aortic jet maximum velocity ( $V$ ).<sup>28,34</sup> Thus, the continuity equation may be simplified to

$$AVA = CSA_{LVOT} \times V_{LVOT}/V_{AV}.$$

This method is less well accepted because of concerns that results are more variable when using velocities as opposed to using VTIs in the equation. In addition, SV assessment has become standard and is of utmost importance in low gradient AS, requiring VTI measurements.

### Velocity ratio and VTI ratio (dimensionless index)

Another approach to reducing error related to LVOT area measurements is removing LVOT CSA from the continuity equation. This dimensionless velocity or VTI ratio expresses the size of the valve effective area as a proportion of the CSA of the LVOT:

$$\text{Velocity ratio} = \frac{V_{LVOT}}{V_{AV}}$$

$$\text{VTI ratio} = \frac{VTI_{LVOT}}{VTI_{AV}}.$$

In the absence of valve stenosis, the velocity ratio approaches 1, with smaller numbers indicating more severe stenosis. Severe stenosis is suggested when the velocity ratio is 0.25 or less, corresponding to a valve area 25% of normal.<sup>19</sup> To some extent, the velocity ratio is normalized for body size because it reflects the ratio of the actual valve area to the expected valve area in each patient, regardless of body size. However, this measurement ignores the variability in LVOT size beyond variation in body size.

### AVA planimetry

Multiple studies have evaluated the method of measuring anatomic (geometric) AVA by direct visualization of the valve orifice, by TTE or TOE, as an alternative to Doppler estimation of flow velocities (Table

2). However, planimetry becomes particularly difficult when valve calcification causes shadows or reverberations limiting identification of the orifice. This is particularly true for TTE. If planimetry is used it should be done with TOE which has been shown to provide valve areas correlating with invasive data (Gorlin equation), Doppler data (continuity equation), and planimetry by MSCT.<sup>21,22,42–46</sup> Caution is also needed to ensure that the minimal orifice area is identified rather than the larger area proximal to the cusp tips, particularly in congenital AS with a doming valve. In addition, as stated previously, effective, rather than anatomic, orifice area is the primary predictor of outcome. In this context it has to be pointed out again that the EOA is significantly smaller than the anatomic AVA because of flow contraction.

## Experimental descriptors of stenosis severity

(Level 3 recommendation, not recommended for routine clinical use)

Other haemodynamic measurements of severity such as valve resistance, LV percentage stroke-work loss, and the energy-loss coefficient are based on different mathematical derivations of the relationship between flow and the trans-valve pressure drop.<sup>23,27–30</sup> Accounting for PR in the ascending aorta has shown improved agreement between invasively and non-invasively derived measurements of the transvalvular pressure gradient, and is particularly useful in the presence of a high output state, a moderately narrowed valve orifice and, most importantly, a non-dilated ascending aorta.<sup>24,25</sup>

A common limitation of most of these new indices is that long-term longitudinal data from prospective studies are lacking. Consequently, a robust validation of clinical-outcome efficacy of all these indices is pending, and they are seldom used for clinical decision-making.<sup>23</sup>

## Advanced assessment of AS severity

### Basic grading criteria

There is a continuous spectrum of aortic valve disease from aortic sclerosis without haemodynamic consequences to very severe flow obstruction. The measures of disease severity need therefore to be viewed as a continuum. Definitions of grades of severity of AS are to some extent arbitrary. In clinical practice, peak transaortic jet velocities, mean gradients and valve areas (calculated by the continuity equation) are in general used to grade the severity of AS. The

**Table 3** Recommendations for grading of AS severity

	Aortic sclerosis	Mild	Moderate	Severe
Peak velocity (m/s)	≤2.5 m/s	2.6–2.9	3.0–4.0	≥4.0
Mean gradient (mmHg)	–	<20	20–40	≥40
AVA (cm <sup>2</sup> )	–	> 1.5	1.0–1.5	<1.0
Indexed AVA (cm <sup>2</sup> /m <sup>2</sup> )	–	>0.85	0.60–0.85	<0.6
Velocity ratio	–	> 0.50	0.25–0.50	<0.25

prognostic importance of peak aortic jet velocity across the whole spectrum of AS and even beyond the threshold of severe stenosis has been demonstrated.

Current recommendations<sup>1,2</sup> for haemodynamic classification of AS severity are demonstrated in Table 3. Any one of the three criteria: a valve area  $<1.0 \text{ cm}^2$ , a peak velocity  $\geq 4.0 \text{ m/s}$ , or a mean gradient  $\geq 40 \text{ mmHg}$  can be considered to suggest severe AS. Ideally, there should be concordance with all criteria in the severe range. In cases where there is discordance of criteria, it is important to integrate these criteria with additional imaging findings and clinical data before a final judgement (see Special considerations of difficult subgroups and Integrated and stepwise approach to grade AS severity sections). Because velocities and gradients are flow dependent, some patients with low volume flow across the aortic valve [e.g. SV index (SVi)  $<35 \text{ mL/m}^2$ ] may have severe AS with only a small valve area, and not a high velocity or mean gradient. It has been suggested to index AVA to body surface area (cut-off  $0.6 \text{ cm}^2/\text{m}^2$  for severe AS) for patients with either unusually small or large body surface area. The role of indexing for body size is, however, controversial, primarily because the current algorithms for defining body size [such as body-surface area (BSA)] do not necessarily reflect the normal AVA in obese patients, and because valve area does not increase with excess body weight. However, indexing valve area for BSA is important in children, adolescents, and small adults, as valve area may seem severely narrowed when only moderate stenosis is present.

When velocity ratio is used, a ratio  $<0.25$  is considered to indicate severe AS.

Hypertension can alter the peak velocity/mean gradient and should therefore be recorded for every examination. Ideally the evaluation of aortic stenosis should be carried out when the patient's blood pressure is normal.

### Special considerations of difficult subgroups

While haemodynamic classification of AS severity is easy when measurements of velocity/gradient and valve area are concordant (Table 3), it becomes challenging when discordant measurements are present.

Valve area may be  $\geq 1.0 \text{ cm}^2$  despite a peak velocity  $\geq 4 \text{ m/s}$  and mean gradient  $\geq 40 \text{ mmHg}$  in the presence of a high transvalvular flow. This may be owing to concomitant AR or shunt lesions. Although valve area may be larger than normally expected for severe AS, haemodynamics remain consistent with severe LV pressure overload and therefore severe aortic valve disease in this situation. For clinical decision-making, reversible causes of increased flow in case of high cardiac output (fever, anaemia, hyperthyroidism, atrioventricular shunts for dialysis, etc.) must be excluded.

More challenging is the discordant finding of a valve area  $<1.0 \text{ cm}^2$  in the presence of a peak velocity  $<4 \text{ m/s}$  and mean gradient  $<40 \text{ mmHg}$ . In this situation, measurement errors for all components (transaortic velocity, LVOT velocity, LVOT area) need to be carefully excluded, in particular the underestimation of LVOT area and thus underestimation of flow rate (see Aortic valve area section). The first step is to review the original images and Doppler tracings to ensure the data quality is high and that measurements have been made correctly.

It also has to be emphasized that current cut-offs for valve area and velocity/gradient are not consistent. To generate a mean gradient

of  $40 \text{ mmHg}$  at a normal flow rate, the valve area must be closer to  $0.8$  than to  $1.0 \text{ cm}^2$ .<sup>47,48</sup> This discrepancy seems to affect especially patients with a small LVOT diameter.<sup>49</sup> Finally, small stature of the patient may be another reason for the finding of a small valve area and low gradient.

After exclusion of these reasons for discordant valve area/gradient measurements, the following entities must be considered.

#### Low flow, low gradient AS with reduced ejection fraction

When LV systolic dysfunction with reduced SV co-exists with severe AS, the AS velocity, and gradient may be low, despite a small valve area.<sup>50,51</sup> A widely used definition of low flow, low gradient AS with reduced EF includes the following conditions:

- Effective AVA  $<1.0 \text{ cm}^2$ .
- Mean aortic transvalvular pressure gradient  $<40 \text{ mmHg}$ .
- LV ejection fraction  $<50\%$ .
- SVi  $<35 \text{ mL/m}^2$ .


Dobutamine stress-echocardiography provides information on the changes in aortic velocity, mean gradient, and valve area as flow rate increases, and also provides a measure of the contractile response to dobutamine and presence of flow reserve, measured by the change in ejection fraction and increase in SV.<sup>30,50–53</sup> These data may be helpful to differentiate two clinical situations:

- Severe AS causing LV systolic dysfunction (i.e. true severe AS): the transaortic velocity is flow dependent; so, LV failure can lead to a patient with severe AS having an apparently moderate transaortic peak velocity and mean pressure gradient associated with a small EOA. In this situation, aortic valve replacement will relieve afterload and may allow the LV ejection fraction to increase towards normal.
- Moderate AS (i.e. pseudosevere AS) with another cause of LV dysfunction (e.g. myocardial infarct or a primary cardiomyopathy): The EOA is then low because the LV does not generate sufficient energy to overcome the inertia required to open the aortic valve to its maximum possible extent. In this situation, aortic valve replacement may not lead to a significant improvement in LV systolic function. Valve replacement has not been shown to be of benefit in this group and medical heart failure treatment is recommended.<sup>54</sup> Thus, this diagnostic distinction has important clinical relevance.

A patient with a low ejection fraction but a resting AS velocity  $\geq 4.0 \text{ m/s}$  or mean gradient  $\geq 40 \text{ mmHg}$  generally does not have impaired LV systolic function. The ventricle is demonstrating a normal response to high afterload (severe AS), and ventricular function will improve after relief of stenosis. This patient does not need a stress echocardiogram.

The protocol for dobutamine stress echocardiography for evaluation of AS severity in the setting of LV dysfunction uses a low-dose protocol, starting at  $2.5$  or  $5 \text{ }\mu\text{g/kg/min}$  with an incremental increase in the infusion every  $3$ – $5 \text{ min}$  to a maximum dose of  $10$ – $20 \text{ }\mu\text{g/kg/min}$  (see Table 4). There is a risk of arrhythmia so there must be medical supervision and high doses of dobutamine should be avoided. The infusion should be stopped as soon as a positive result is obtained ( $>20\%$  increase in SV from baseline or an increase in AS jet velocity  $\geq 4.0 \text{ m/s}$  or a mean gradient  $\geq 30$ – $40 \text{ mmHg}$  provided that valve area does not exceed  $1.0 \text{ cm}^2$  at any flow rate) or when the heart rate begins to rise more than  $10$ – $20 \text{ bpm}$  over baseline or exceeds  $100 \text{ bpm}$ , on the assumption that the maximum inotropic effect has been reached. In addition, dobutamine

**Table 4** Low dose dobutamine protocol

Starting dobutamine dose of 2.5 to 5 mcg/kg/min

Increase dose 2.5 to 5 mcg/kg/min every 3-5 minutes
Maximum dobutamine dose of 20 mcg/kg/min
Infusion stopped when:
<ol style="list-style-type: none"> <li>1) Maximum dobutamine dose reached (20 mcg/kg/min)</li> <li>2) Positive result obtained</li> <li>3) Heart rate rises 10-20 bpm over baseline or exceeds 100 bpm</li> <li>4) Symptoms, blood pressure fall, or significant arrhythmias</li> </ol>
Positive Result:
<ul style="list-style-type: none"> <li>• An increase in effective AVA to a final valve area <math>&gt;1.0 \text{ cm}^2</math> suggests that stenosis is not severe [47].</li> <li>• Severe stenosis is suggested by an AS jet velocity <math>\geq 4.0 \text{ m/s}</math> or a mean gradient <math>&gt; 30\text{--}40 \text{ mmHg}</math> provided that valve area does not exceed <math>1.0 \text{ cm}^2</math> at any flow rate [50,51].</li> <li>• Absence of contractile reserve (failure to increase SV by <math>&gt;20\%</math>) is a predictor of a high surgical mortality and poor long-term outcome although valve replacement may improve LV function and outcome even in this subgroup [52].</li> </ul>

administration should also be terminated when symptoms, blood pressure fall, or significant arrhythmias occur.

Doppler data are recorded at each stage including LVOT velocity recorded from the apical approach. AS jet velocity is recorded from the window that yields the highest velocity signal but some laboratories prefer to use comparative changes from an apical window to facilitate rapid data acquisition. The LVOT diameter is measured at baseline and the same diameter is used to calculate the continuity-equation valve area at each stage. Measurement of biplane ejection fraction at each stage is helpful to assess the improvement in LV contractile function. The dimensionless index can be tracked during stages as an alternate measure corroborating changes in AVA.

The report of the dobutamine stress echocardiographic study should include AS velocity, mean gradient, SV and valve area at each stage. EF should be measured at least at baseline and peak effect. The role of dobutamine stress echocardiography in decision-making in adults with AS is controversial and beyond the scope of this document. The findings we recommend as reliable are:

- An increase in effective AVA to a final valve area  $>1.0 \text{ cm}^2$  suggests that stenosis is not severe.<sup>26</sup>
- $>20\%$  increase in SV from baseline suggests presence of contractile reserve.
- Severe stenosis is suggested by an AS jet velocity  $\geq 4.0 \text{ m/s}$  or a mean gradient  $>30\text{--}40 \text{ mmHg}$  provided that valve area does not exceed  $1.0 \text{ cm}^2$  at any flow rate.<sup>51</sup>
- Absence of contractile reserve (failure to increase SV by  $>20\%$ ) is a predictor of a high surgical mortality and poor long-term outcome although valve replacement may improve LV function and outcome even in this subgroup.<sup>52</sup>

The changes in gradient and AVA during DSE largely depend on the magnitude of flow augmentation, which may vary considerably from one patient to another. Therefore, it would be ideal to compare

AVA in different patients at a standardized normal flow rate. With this purpose, a new parameter, the projected AVA at a normal flow rate of  $250 \text{ mL/s}$ , has been proposed.<sup>30,53</sup>

## Key points

- (1) Low flow, low gradient AS with reduced ejection fraction is defined as (i) AVA  $<1.0 \text{ cm}^2$ , (ii) mean aortic transvalvular pressure gradient  $<40 \text{ mmHg}$ , (iii) LV ejection fraction  $<50\%$ , and (iv) SVi  $<35 \text{ mL/m}^2$ .
- (2) Low-dose DSE can help distinguish between pseudo severe AS vs. true severe AS.
  - An increase in effective AVA to a final valve area  $>1.0 \text{ cm}^2$  suggests that stenosis is not severe.
  - Severe stenosis is suggested by an AS jet velocity  $\geq 4 \text{ m/s}$  or a mean gradient  $>30\text{--}40 \text{ mmHg}$  provided that valve area does not exceed  $1.0 \text{ cm}^2$  at any flow rate.
  - Absence of contractile reserve (failure to increase SV by  $>20\%$ ) is a predictor of a high surgical mortality and poor long-term outcome although valve replacement may improve LV function and outcome even in this subgroup.

## Low flow, low gradient AS with preserved ejection fraction

The most challenging finding in clinical practice is a valve area  $<1 \text{ cm}^2$  with a peak velocity  $<4 \text{ m/s}$  and a mean pressure gradient  $<40 \text{ mmHg}$  despite normal LVEF. The entity of 'paradoxical' low flow, low gradient AS with preserved EF has been introduced in this setting and refers to patients with hypertrophied, small ventricles resulting in reduced transvalvular flow (for which SVi  $< 35 \text{ mL/m}^2$  is a surrogate) despite normal EF.<sup>55,56</sup> However, this entity has to be diagnosed with particular care because other more frequent reasons for the finding of a small valve area and low gradient in the presence of normal EF may be more likely such as technical factors in AVA calculation (see Aortic valve area section) and have to be carefully excluded. Severe

**Table 5** Criteria that increase the likelihood of severe AS in patients with AVA  $<1.0 \text{ cm}^2$  and mean gradient  $<40 \text{ mmHg}$  in the presence of preserved EF

(1) Clinical criteria:		
Physical examination consistent with severe aortic stenosis		
Typical symptoms without other explanation		
Elderly patient ( $>70$ years)		
(2) Qualitative imaging data:		
LVH (additional history of hypertension to be considered)		
Reduced LV longitudinal function without other explanation		
(3) Quantitative imaging data:		
Mean gradient $30\text{--}40 \text{ mmHg}^*$		
AVA $\leq 0.8 \text{ cm}^2$		
Low flow (SVi $<35 \text{ mL/m}^2$ ) confirmed by other techniques than standard		
Doppler technique (LVOT measurement by 3D TEE or MSCT; CMR, invasive data)		
Calcium score by MSCT**		
Severe AS likely:	men $\geq 2000$	women $\geq 1200$
Severe AS very likely:	men $\geq 3000$	women $\geq 1600$
Severe AS unlikely:	men $<1600$	women $<800$

\*Haemodynamics measured when the patient is normotensive

\*\*Values are given in arbitrary units using Agatston method for quantification of valve calcification

AS, aortic stenosis; AVA, aortic valve area; EF, ejection fraction; LVOT, left ventricular outflow tract; CMR, cardiac magnetic resonance imaging; MSCT, multislice computed tomography; SVi, stroke volume index; TOE, transesophageal echocardiography.

AS must, in particular be questioned when peak velocity is  $<3.0 \text{ m/s}$  and mean pressure gradient  $<20 \text{ mmHg}$ . Severe 'paradoxical' low flow, low gradient AS with preserved EF has in general been described in elderly patients with hypertrophied ventricles of small volume. Reduced longitudinal LV function and fibrosis have been found in many cases. However, the vast majority of these patients had a history of hypertension that may also have caused the LV pathology.<sup>55,56</sup> In addition, it remains so far unclear how to distinguish between pseudosevere and true severe AS in this setting. DSE may be less helpful in these ventricles with small volumes and normal EF. So far, only one small study has suggested that dobutamine echo may be helpful in this setting.<sup>57</sup> Further research is required to define its definite role in paradoxical low flow, low gradient AS. The degree of valve calcification assessed by non-contrast CT may in this situation be a final important hint to identify true severe AS.<sup>58,59</sup> However, only a high calcium score can ascertain severe AS while a low score makes severe AS highly unlikely (Table 5). Thus, in a relatively wide intermediate grey zone, a calcium score can also not give the final answer by itself and can only be one important piece of information within an integrated approach (see Integrated and stepwise approach to grade AS severity section). In addition, calcium load must be differently interpreted in men and women, mainly because of differences in body size. It has, therefore, been proposed to index calcium scores to BSA or relate it to the LVOT area.<sup>59,60</sup>

In summary, the following conditions must be considered when AVA is calculated smaller than  $1 \text{ cm}^2$  with a peak velocity  $<4 \text{ m/s}$  and mean gradient  $<40 \text{ mmHg}$  despite normal LV EF:

- Measurement errors (most importantly, underestimation of LVOT area and thus flow) in moderate AS (true valve area  $\geq 1.0 \text{ cm}^2$ ).
- Severe hypertension during examination.
- Inconsistency between AVA and velocity/gradient cut-offs in the range of AVAs between  $0.8$  and  $1.0 \text{ cm}^2$ .
- Clinically moderate AS (despite an AVA  $<1.0 \text{ cm}^2$ ) in a patient with small body size.
- Severe paradoxical low flow, low gradient AS (true severe or pseudosevere).

For guidance how to deal with these patients in clinical practice see Integrated and stepwise approach to grade AS severity in clinical practice section.

## Key points

- (1) Low flow, low gradient AS with preserved ejection fraction is defined as (i) AVA  $<1 \text{ cm}^2$ , (ii) peak velocity  $<4 \text{ m/s}$ , (iii) mean pressure gradient  $<40 \text{ mmHg}$ , and (iv) normal LVEF ( $\geq 50\%$ ).
- (2) When considering low flow, low gradient AS with preserved ejection fraction, important to exclude:
  - Measurement errors (most importantly, underestimation of LVOT area and thus flow).
  - Severe hypertension during examination.
  - Inconsistency between AVA and velocity/gradient cut-offs in the range of AVAs between  $0.8$  and  $1.0 \text{ cm}^2$ .
  - Clinically moderate AS (despite an AVA  $<1.0 \text{ cm}^2$ ) in a patient with small body size.

## Normal flow, low gradient AS with preserved ejection fraction

A calculated valve area below  $1 \text{ cm}^2$  and a mean gradient below  $40 \text{ mmHg}$  ( $V_{\max}$  below  $4 \text{ m/s}$ ) may be encountered even in the presence of calculated normal flow in clinical practice. Although the entity of 'severe normal flow, low gradient AS' has been suggested<sup>61</sup> this does not make sense by fluid dynamics principles. It is more likely that this composition of measurements is a result of the inconsistent cut-off values for valve area and velocity/gradient (see above) or of measurement errors—in particular underestimation of valve area by above-mentioned reasons—and indicates clinically moderate AS. This hypothesis is supported by studies that have demonstrated that patients with 'normal flow, low gradient AS' have the same outcome as those with moderate AS.<sup>62,63</sup> Patients with this constellation should therefore not be diagnosed to have severe AS. They should however be carefully followed and re-evaluated, particularly when they are symptomatic.

## New classification of AS by gradient, flow, and ejection fraction

As discussed in Special considerations of difficult subgroups section, a valve area  $<1.0 \text{ cm}^2$  is a sensitive marker to identify severe AS but has a low specificity when velocity is  $<4 \text{ m/s}$  and mean gradient  $<40 \text{ mmHg}$ . Patients with a valve area  $<1.0 \text{ cm}^2$  and a velocity  $<4 \text{ m/s}$  may have only moderate AS, depending on flow status and ventricular function. Thus, in patients with a valve area  $<1.0 \text{ cm}^2$ , further classification based on the combination of velocity (gradient), transvalvular SV, and LV ejection fraction is recommended as follows:



- high gradient (velocity  $\geq 4$  m/s or mean gradient  $\geq 40$  mmHg) vs. low gradient (mean gradient  $< 40$  mmHg);
- normal flow (SVi  $\geq 35$  mL/m<sup>2</sup>) vs. low flow (SVi  $< 35$  mL/m<sup>2</sup>);
- preserved ejection fraction ( $\geq 50\%$ ) vs. reduced ejection fraction ( $< 50\%$ ).

As discussed above, the assumption of a circular LVOT shape may result in underestimation of transaortic SV measured using Doppler data so that many patients classified to have low flow, low gradient AS may indeed have normal flow and thus only moderate AS. Although 2D and 3D echocardiographic measurement of LV end-diastolic and end-systolic volumes to calculate SV is not affected by LVOT geometry, this approach also can underestimate SV. In clinical practice, the diagnosis of low flow AS is most secure if multiple approaches to calculation of SVi yield similar results and there is an explanation for the low flow state—most often a small hypertrophied ventricle with small LV volumes or LV systolic dysfunction with a reduced ejection fraction. Furthermore—although widely accepted—the definition of the flow status by SV has intrinsic limitations. With increasing severity of AS, the ejection time may prolong and even patients with a normal SV may indeed have reduced transvalvular flow.<sup>64</sup>

For these reasons, the new classification has to be viewed with caution. For clinical decision-making, it is strongly recommended to follow the integrated approach of AS assessment described in Integrated and stepwise approach to grade AS severity in clinical practice section. The diagnosis of severe AS requires clinical judgment with integration of several types of data including patient symptoms, valve anatomy, haemodynamics, and LV anatomy and function as summarized in the ACC/AHA guidelines recommendation for disease stages.<sup>1</sup>

## Key points

In patients with a valve area  $< 1.0$  cm<sup>2</sup>, further classification based on the combination of velocity (gradient), transvalvular SV, and LV ejection fraction is recommended as follows:

- high gradient (velocity  $\geq 4$  m/s or mean gradient  $\geq 40$  mmHg) vs. low gradient (mean gradient  $< 40$  mmHg);
- normal flow (SVi  $\geq 35$  mL/m<sup>2</sup>) vs. low flow (SVi  $< 35$  mL/m<sup>2</sup>);
- preserved ejection fraction ( $\geq 50\%$ ) vs. reduced ejection fraction ( $< 50\%$ ).

## Assessment of the LV in AS

LV hypertrophy and changes in LV function in response to AS are important for AS grading and the definition of the pathophysiologic stage of disease. In addition, LV abnormalities (hypertrophy, dysfunction) caused by concomitant disease such as arterial hypertension, LV dysfunction from coronary artery disease or cardiomyopathy may significantly affect AS assessment.

## Conventional parameters of LV function

Conventional parameters of LV function include the measurement of LV end-diastolic and end-systolic diameters providing fractional shortening, and end-diastolic and end-systolic volumes providing SV and ejection fraction. EF is load dependent and the increase in LV afterload associated with AS may result in a decrease in EF despite

preserved myocardial function (i.e. afterload mismatch). In this case, EF will improve after relief of obstruction.

## Novel parameters of LV function

Global longitudinal strain (GLS) measurements in severe AS may detect impairment of LV systolic function when EF is still normal and may predict prognosis although further studies are needed to confirm its prognostic value.<sup>65–68</sup> In addition, myocardial fibrosis is associated with unfavourable outcomes in AS patients and may be reflected in reduced GLS.<sup>69–72</sup> However, limitations to the clinical utility of GLS include inter-vendor differences in strain measurements,<sup>73</sup> afterload dependence, and outcome data largely limited to studies of symptomatic patients. Thus, the role of GLS in asymptomatic AS for the detection of early myocardial dysfunction and as a parameter that may improve timing of intervention remains insufficiently defined. Nevertheless, its use as an additional piece of information within an integrated approach to assess AS can be helpful in selected patients.

## LV hypertrophy

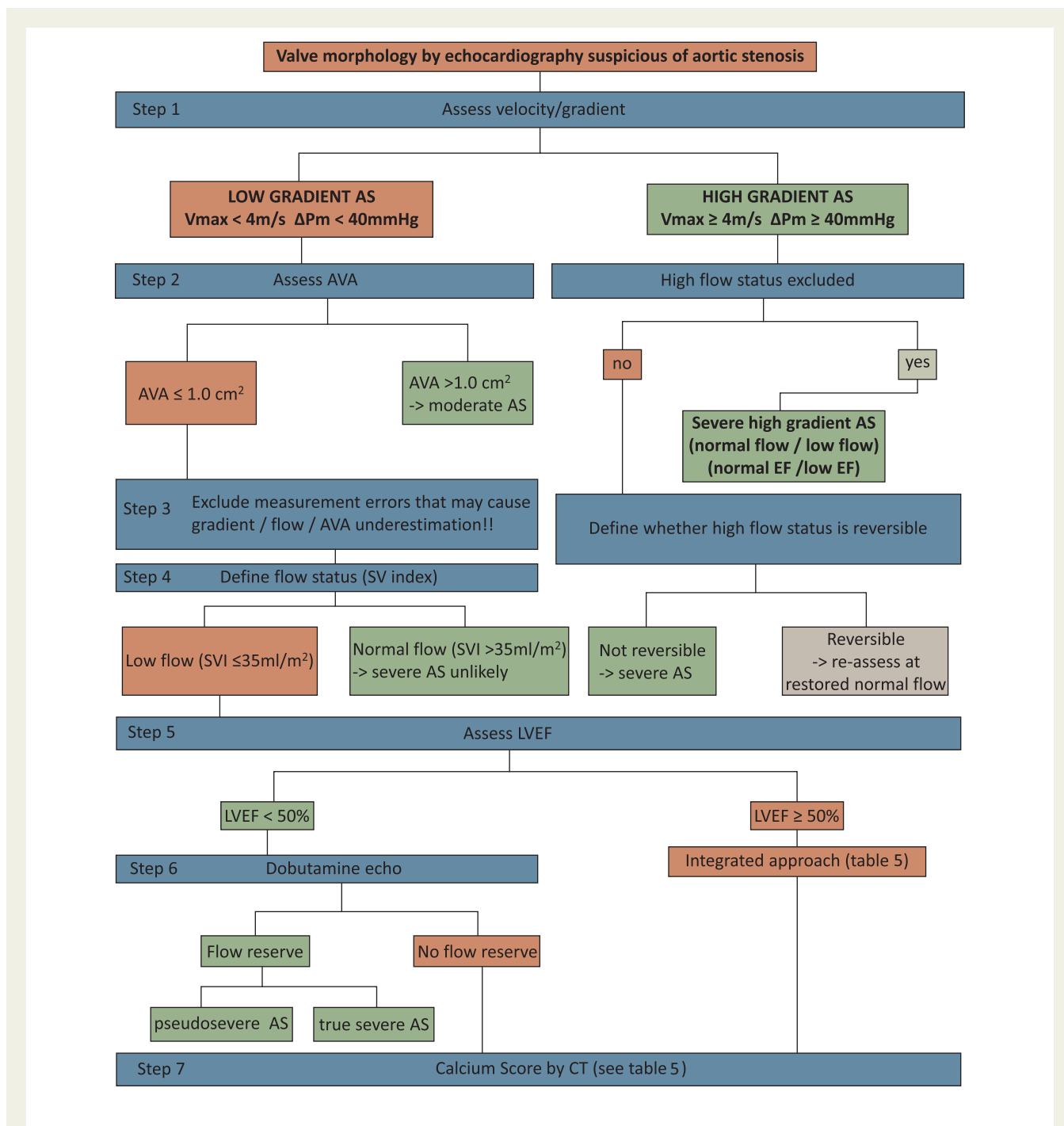
LV hypertrophy commonly accompanies AS either as a consequence of valve obstruction or owing to chronic hypertension, which is frequently present in the elderly with AS. Ventricular hypertrophy typically results in a small ventricular cavity with thick walls and diastolic dysfunction, particularly in elderly women with AS. The small LV ejects a small SV so that, even when severe stenosis is present, the AS velocity and mean gradient may be lower than expected for a given valve area. Continuity-equation valve area is accurate in this situation. Many women with small LV size also have a small body size (and LVOT diameter), so indexing valve area to body size may be helpful. Excessive LV hypertrophy as assessed by echocardiography has been shown to be a predictor of outcome.<sup>74</sup> Assessment of LV fibrosis by echocardiography remains limited and requires magnetic resonance imaging (CMR).

## Integrated and stepwise approach to grade AS severity

Considering all the newly defined entities of AS discussed above, the definition of severe AS has become more and more challenging over recent years. Current guidelines emphasize that the diagnosis in clinical practice must be based on an integrated approach including transvalvular velocity/gradient, valve area, valve morphology, flow rate, LV morphology and function, blood pressure and symptoms.<sup>1,2</sup> The following step-by-step approach can help to deal with the current challenge of defining severe AS in clinical practice and is illustrated in Figure 8.

2D echocardiography provides the morphology of the aortic valve. Thickening and calcification of aortic cusps with reduced motion (calcific AS) or doming of a pliable aortic valve (congenital AS) or fused commissures (rheumatic AS) indicate the presence of stenotic aortic valve disease and requires further assessment of its severity by the following steps.

Step 1. Assessment of transvalvular peak velocity and mean gradient



**Figure 8** Integrated, stepwise approach to grading AS severity.

Carefully performed CW-Doppler interrogation provides transvalvular peak velocity and mean gradient. Several major sources of error need to be avoided (see Peak jet velocity and Mean gradient sections). A velocity of  $\geq 4$  m/s and a mean gradient of  $\geq 40$  mmHg indicate high gradient AS while measurements below these cut-offs define low gradient AS. This distinction determines the following steps of evaluation. It has to be emphasized that velocity/gradient measurements—as long as properly performed—represent the most robust variables for severity assessment in clinical practice.

### High gradient AS track

This track may be considered the ‘easy track’. A high gradient generally indicates severe AS. Whether severe high gradient AS is associated with normal flow or low flow and normal LVEF or reduced LVEF has prognostic implications but does not require further evaluation to confirm AS severity.

The only diagnostic condition to consider for assessment of AS severity is the patient with abnormally high flow across the valve (SVI  $> 58$  mL/m<sup>2</sup>).<sup>48</sup> In this situation, even non-severe AS as defined

by  $AVA \geq 1.0 \text{ cm}^2$ , may present with a high gradient. The high gradient will nevertheless indicate severe pressure overload of the left ventricle. In some settings, high flow and therefore the severity of pressure overload may be reversible such as in anaemia, hyperthyroidism, arterio-venous shunts. These conditions need to be identified and correctly addressed. Assessment should then be repeated when flow status has normalized. In other settings such as additional AR of haemodynamic significance or patients on haemodialysis with no option to reduce the shunt, the high flow cannot be changed but then the high gradient again indicates severe pressure overload owing to aortic valve disease and high gradients remain an essential prognostic factor<sup>75</sup> consistent with severe valve disease that may indicate intervention on the aortic valve.

The next step in high gradient AS is therefore to *exclude a high flow state* and if present to determine the reason for the high flow and whether it is reversible. High flow can—in most instances—be easily recognized from high LVOT velocity that can be quickly recognized by colour Doppler or velocity ratio.

## Low gradient AS track

This is considered the 'difficult track'.

In low gradient AS, the next step must always be to assess AVA.

*Step 2.* Effective AVA calculation indicates moderate AS when it is  $\geq 1.0 \text{ cm}^2$ . In patients with a large LVOT, overestimation of flow and therefore AVA should be excluded.

A calculated effective AVA  $< 1.0 \text{ cm}^2$  only suggests, but does not confirm severe AS. This setting requires the most extensive further evaluation.

*Step 3.* Exclusion of measurement errors (see Peak jet velocity, Mean gradient, Aortic valve area and Special considerations of difficult subgroups sections).

All components that contribute to AVA calculation must be checked. In particular underestimation of AVA by flow underestimation owing to underestimation of the LVOT area must be carefully excluded.

*Step 4.* Define flow status (normal flow =  $SV_i \geq 35 \text{ mL/m}^2$ ; low flow =  $SV_i < 35 \text{ mL/m}^2$ ).

If normal flow is present, severe AS is very unlikely even if AVA is calculated  $< 1 \text{ cm}^2$ . These patients will in general have moderate AS and AVA is likely to be miscalculated. The inconsistency of the cut-offs for AVA and velocity/gradient may be another explanation for this constellation of measurements as well as a very small body size.

*Step 5.* If low flow is present, further evaluation depends on LV ejection fraction and patients with preserved EF must be separated from those with reduced EF.

In low flow, low gradient AS with reduced LVEF (i.e.  $< 50\%$ ), dobutamine echo should be performed to assess contractile/flow reserve (increase in SV on DSE by 20% or more) and to distinguish between true severe and pseudosevere AS (see Low flow, low gradient AS with reduced EF section). In patients without contractile reserve, this distinction may not be possible and the degree of valve calcification (best determined by MSCT) may be the primary clue as to whether AS is severe or moderate (see Table 5).

Low flow, low gradient AS with preserved LVEF represents the most challenging subgroup and clear distinction between severe and non-severe AS remains difficult. Measurement errors must be excluded with particular care in this setting. Because flow

measurements in the LVOT tend to underestimate the real flow when assuming a circular shape, additional attempts to account for this source may be required to make sure that flow is indeed reduced and  $AVA < 1.0 \text{ cm}^2$ . 3D echo and MSCT may provide a more accurate LVOT area and SV calculation. Magnetic resonance imaging (CMR) and invasive evaluation may be alternatives. When measurements are confirmed, Table 5 summarizes criteria that increase the likelihood of severe AS in this setting. Extent of valve calcification again is an important piece of information, but an integrated approach that includes in addition a number of clinical, morphologic and haemodynamic variables is essential.

## Key points

- The diagnosis of severe aortic stenosis in clinical practice must be based on an integrated approach including transvalvular velocity/gradient, valve area, valve morphology, flow rate, LV morphology and function, blood pressure and symptoms.
- A step-by-step approach can help to deal with the current challenge of defining severe AS particularly in the setting of low gradient AS in clinical practice (Figure 8).

## Associated pathologies

### Aortic regurgitation

About 80% of adults with AS also have AR but regurgitation is usually only mild or moderate in severity and measures of AS severity are not significantly affected. When severe AR accompanies AS, measures of AS severity remain accurate including maximum velocity, mean gradient, and valve area. However, because of the high trans-aortic volume flow rate, maximum velocity, and mean gradient will be higher than expected for a given valve area. In this situation, reporting accurate quantitative data for the severity of both stenosis and regurgitation<sup>76</sup> is helpful for clinical decision-making. The combination of moderate AS and moderate AR is consistent with severe combined valve disease. Velocity and mean gradient remain the major predictors of outcome.<sup>75</sup>

### Mitral regurgitation

MR is common in elderly adults with AS either as a consequence of LV pressure overload, LV remodelling or owing to concurrent mitral valve disease. It is essential to distinguish regurgitation owing to a primary abnormality of the mitral valve from secondary regurgitation related to AS. LV size, hypertrophy, and systolic and diastolic function should be evaluated using standard approaches, and pulmonary systolic pressure should be calculated from the peak tricuspid regurgitant jet velocity and estimated right atrial pressure. MR severity does not affect evaluation of AS severity except for two possible confounders. First, with severe MR, transaortic flow rate may be low resulting in a low gradient even when severe AS is present; valve area calculations remain accurate in this setting as long as flow is calculated in the LVOT and not by volumetry. Second, a high-velocity MR jet may be mistaken for the AS jet as both are systolic signals directed away from the apex. Timing of the signal is the most reliable way to distinguish the CWD velocity curve of MR from AS; MR is longer in duration, starting with mitral valve closure and continuing until mitral valve opening. The shape of the MR velocity curve also may be helpful

with chronic regurgitation, but can appear similar to AS with acute severe MR. High driving pressure (high LV pressure owing to AS) may cause MR severity overestimation if jet size is primarily used to evaluate MR. The high driving pressure will also disproportionately increase the regurgitant volume for a given regurgitant orifice area. Careful evaluation of the mechanism(s) of MR is crucial for the decision whether the mitral valve requires intervention in addition to aortic valve intervention.

## Mitral stenosis

In patients with rheumatic AS, the mitral valve is usually also affected with the rheumatic process and has some degree of stenosis, or possibly predominantly regurgitation. Mitral stenosis may result in low cardiac output and, therefore, low flow, low gradient AS.

## Dilatation of the ascending aorta

In addition to evaluation of AS aetiology and haemodynamic severity, the echocardiographic evaluation of adults with aortic valve disease should always include careful evaluation of the aorta with measurement of diameters at the sinuses of Valsalva, the sinotubular junction and the ascending aorta. Dilation of the aortic root and/or the tubular ascending aorta is associated with bicuspid aortic valve disease and aortic size may impact the timing and type of intervention. In some cases, additional imaging with TOE, CT or CMR may be needed to fully assess the aorta.

## Arterial hypertension

Hypertension accompanied AS in 35–45% of patients in earlier studies. However, in elderly patients with low flow, low gradient AS it was present in the vast majority.<sup>55,56</sup> Although an *in vitro* study has demonstrated that systemic pressure may not directly affect gradient and valve area measurements,<sup>77</sup> increasing LV pressure load may cause changes in ejection fraction and flow. The presence of hypertension may therefore primarily affect flow and gradients but less AVA measurements. Nevertheless, evaluation of AS severity<sup>78,79,80</sup> with uncontrolled hypertension may not accurately reflect disease severity. Thus, control of blood pressure is recommended before echocardiographic evaluation, whenever possible. The echocardiographic report should always include a blood pressure measurement recorded at the time of the examination, to allow comparison between serial echocardiographic studies and with other clinical data.

## Prognostic markers

A number of echocardiographic predictors of outcome have been reported in asymptomatic severe AS. They have been of particular interest with regard to the improvement of timing of surgery in asymptomatic patients. In this context, it has to be emphasized that these factors have, in general, been demonstrated to be predictors of event-free survival, which was driven by development of symptoms requiring intervention in the majority of cases. It remains uncertain whether patients benefit from early surgery before symptom onset in the presence of these risk factors.

Echocardiographic predictors of symptom development and adverse outcomes in AS are as follows:

- peak aortic jet velocity;<sup>8,15,81</sup>
- severity of valve calcification;<sup>8</sup>
- LV ejection fraction;<sup>71,82</sup>
- rate of haemodynamic progression;<sup>8</sup>
- increase in gradient with exercise;<sup>43,83</sup>
- excessive LV hypertrophy;<sup>74</sup>
- abnormal longitudinal LV function (in particular GLS);<sup>70–72</sup>
- pulmonary hypertension.<sup>84–88</sup>

Of these, the following have been considered in clinical practice guidelines to impact the decision for surgery in asymptomatic AS:<sup>2</sup>

- peak aortic jet velocity >5.5 m/s;
- combination of severe valve calcification with a rapid increase in peak transvalvular velocity of  $\geq 0.3$  m/s/year;
- increase of mean pressure gradient with exercise by > 20 mmHg.

## Key points

The following prognostic markers have been considered to impact decision for surgery in asymptomatic severe aortic stenosis patients.

- peak aortic jet velocity >5.5 m/s;
- combination of severe valve calcification with a rapid increase in peak transvalvular velocity of  $\geq 0.3$  m/s/year;
- increase of mean pressure gradient with exercise by > 20 mmHg.

## Follow-up assessment

Follow-up assessment of AS by echocardiography focuses on the progression of stenosis severity (increase in velocity/gradient and decrease in AVA) and the occurrence of secondary changes in response to AS (increase in LV hypertrophy, decrease in LVEF, increase in secondary MR and TR, increase in pulmonary artery pressure) as well as changes in the size of the ascending aorta.

With regard to changes in velocity/gradient and AVA, it is essential to use exactly the same methods to avoid artificial changes (see above). For example, an increase in peak velocity  $\geq 0.3$  m/s that may drive surgical treatment can be caused by comparison of a spectrum recorded from a right parasternal approach with previous measurements only obtained from an apical approach. Velocity and gradient may remain constant or even decrease despite progression of AS when flow has decreased at the same time.

Thus, follow-up assessment requires methodological precision and careful interpretation.

**Disclaimer:** This report is made available by EACVI and ASE as a courtesy reference source for members. This report contains recommendations only and should not be used as the sole basis to make medical practice decisions or for disciplinary action against any employee. The statements and recommendations contained in this report are frequently based on the opinions of experts, rather than on scientifically verified data. EACVI and ASE make no express or implied warranties regarding the completeness or accuracy of the information in this report, including the warranty of merchantability or fitness for a particular purpose. In no event shall EACVI or ASE be liable to you, your patients, or any other third parties for any decision made or action taken by you or such other parties in reliance on this information. Nor does your use of this information constitute the offering of

medical advice by EACVI/ASE or create any physician-patient relationship between EACVI/ASE and your patients or anyone else.

**Conflict of interest:** None declared.

## References

- Nishimura RA, Otto CM, Bonow RO, Carabello BA, Erwin JP III, Guyton RA et al. 2014 AHA/ACC guideline for the management of patients with valvular heart disease: a report of the American College of Cardiology/American Heart Association Task Force on Practice Guidelines. *Circulation* 2014;**129**:e521–643.
- Joint Task Force on the Management of Valvular Heart Disease of the European Society of Cardiology (ESC), European Association for Cardio-Thoracic Surgery (EACTS), Vahanian A, Alfieri O, Andreotti F, Antunes MJ, Barón-Esquivias G, Baumgartner H et al. Guidelines on the management of valvular heart disease (version 2012). *Eur Heart J* 2012;**33**:2451–9.
- Chambers J, Bach D, Dumesnil J, Otto C, Shah P, Thomas J. Crossing the aortic valve in severe aortic stenosis: no longer acceptable? *J Heart Valve Dis* 2004;**13**:344–6.
- Baumgartner H, Hung J, Bermejo J, Chambers JB, Evangelista A, Griffin BP et al. Echocardiographic assessment of valve stenosis: EAE/ASE recommendations for clinical practice. *J Am Soc Echocardiogr* 2009;**22**:1–23.
- Roberts WC, Ko JM. Frequency by decades of unicuspid, bicuspid, and tricuspid aortic valves in adults having isolated aortic valve replacement for aortic stenosis, with or without associated aortic regurgitation. *Circulation* 2005;**111**:920–5.
- Nistri S, Sorbo MD, Marin M, Palisi M, Scognamiglio R, Thiene G. Aortic root dilatation in young men with normally functioning bicuspid aortic valves. *Heart* 1999;**82**:19–22.
- Schaefer BM, Lewin MB, Stout KK, Byers PH, Otto CM. Usefulness of bicuspid aortic valve phenotype to predict elastic properties of the ascending aorta. *Am J Cardiol* 2007;**99**:686–90.
- Rosenhek R, Binder T, Porenta G, Lang I, Christ G, Schemper M et al. Predictors of outcome in severe, asymptomatic aortic stenosis. *N Engl J Med* 2000;**343**:611–7.
- Lee MS, Finch, W, Mahmud E. Cardiovascular complications of radiotherapy. *Am J Cardiol* 2013;**2013**:1688–96.
- Pontone G, Andreini D, Bartorelli AL, Bertella E, Cortinovis S, Mushtaq S et al. Aortic annulus area assessment by multidetector computed tomography for predicting paravalvular regurgitation in patients undergoing balloon-expandable transcatheter aortic valve implantation: a comparison with transthoracic and transesophageal echocardiography. *Am Heart J* 2012;**164**:576–84.
- Nguyen G, Leipsic J. Cardiac computed tomography and computed tomography angiography in the evaluation of patients prior to transcatheter aortic valve implantation. *Curr Opin Cardiol* 2013;**28**:497–504.
- Currie PJ, Seward JB, Reeder GS, Vlietstra RE, Bresnahan DR, Bresnahan JF et al. Continuous-wave Doppler echocardiographic assessment of severity of calcific aortic stenosis: a simultaneous Doppler-catheter correlative study in 100 adult patients. *Circulation* 1985;**71**:1162–9.
- Smith MD, Kwan OL, DeMaria AN. Value and limitations of continuous-wave Doppler echocardiography in estimating severity of valvular stenosis. *J Am Med Assoc* 1986;**255**:3145–51.
- Burwash IG, Forbes AD, Sadahiro M, Verrier ED, Pearlman AS, Thomas R et al. Echocardiographic volume flow and stenosis severity measures with changing flow rate in aortic stenosis. *Am J Physiol* 1993;**265**:1734–43.
- Otto CM, Burwash IG, Legget ME, Munt BI, Fujioka M, Healy NL et al. Prospective study of asymptomatic valvular aortic stenosis. Clinical, echocardiographic, and exercise predictors of outcome. *Circulation* 1997;**95**:2262–70.
- Evangelista A, Garcia-Dorado D, Garcia del Castillo H, Gonzalez-Alujas T, Soler-Soler J. Cardiac index quantification by Doppler ultrasound in patients without left ventricular outflow tract abnormalities. *J Am Coll Cardiol* 1995;**25**:710–6.
- Baumgartner H, Kratzer H, Helmreich G, Kuehn P. Determination of aortic valve area by Doppler echocardiography using the continuity equation: a critical evaluation. *Cardiology* 1990;**77**:101–11.
- Otto CM, Pearlman AS. Doppler echocardiography in adults with symptomatic aortic stenosis. Diagnostic utility and cost-effectiveness. *Arch Intern Med* 1988;**148**:2553–60.
- Oh JK, Taliario CP, Holmes DR Jr, Reeder GS, Bailey KR, Seward JB et al. Prediction of the severity of aortic stenosis by Doppler aortic valve area determination: prospective Doppler-catheterization correlation in 100 patients. *J Am Coll Cardiol* 1988;**11**:1227–34.
- Otto CM, Pearlman AS, Comess KA, Reamer RP, Janko CL, Huntsman LL et al. Determination of the stenotic aortic valve area in adults using Doppler echocardiography. *J Am Coll Cardiol* 1986;**7**:509–17.
- Kim CJ, Bertlund H, Nishioka T, Luo H, Siegel RJ. Correspondence of aortic valve area determined from transesophageal echocardiography, transthoracic echocardiography and cardiac catheterization. *Am Heart J* 1996;**132**:1163–72.
- Klass O, Walker MJ, Olszewski ME, Bahner J, Feuerlein S, Hoffmann MH, Lang A. Quantification of aortic valve area at 256-slice computed tomography: comparison with transesophageal echocardiography and cardiac catheterization in subjects with high-grade aortic valve stenosis prior to percutaneous valve replacement. *Eur J Radiol* 2011;**80**:151–7.
- Bermejo J, Odreman R, Feijoo J, Moreno MM, Gomez-Moreno P, Garcia-Fernandez MA. Clinical efficacy of Doppler echocardiographic indices of aortic valve stenosis: a comparative test-based analysis of outcome. *J Am Coll Cardiol* 2003;**41**:142–51.
- Baumgartner H, Stefenelli T, Niederberger J, Schima H, Maurer G. 'Overestimation' of catheter gradients by Doppler ultrasound in patients with aortic stenosis: a predictable manifestation of pressure recovery. *J Am Coll Cardiol* 1999;**33**:1655–61.
- Niederberger J, Schima H, Maurer G, Baumgartner H. Importance of pressure recovery for the assessment of aortic stenosis by Doppler ultrasound. Role of aortic size, aortic valve area, and direction of the stenotic jet *in vitro*. *Circulation* 1996;**94**:1934–40.
- Takeda S, Rimington H, Chambers J. The relation between transaortic pressure difference and flow during dobutamine stress echocardiography in patients with aortic stenosis. *Heart* 1999;**82**:11–4.
- Briand M, Dumesnil JG, Kadem L, Tongue AG, Rieu R, Garcia D et al. Reduced systemic arterial compliance impacts significantly on left ventricular afterload and function in aortic stenosis: implications for diagnosis and treatment. *J Am Coll Cardiol* 2005;**46**:291–8.
- Bermejo J, Garcia-Fernandez MA, Torrecilla EG, Bueno H, Moreno MM, San Roman D et al. Effects of dobutamine on Doppler echocardiographic indexes of aortic stenosis. *J Am Coll Cardiol* 1996;**28**:1206–13.
- Burwash IG, Thomas DD, Sadahiro M, Pearlman AS, Verrier ED, Thomas R et al. Dependence of Gorlin formula and continuity equation valve areas on transvalvular volume flow rate in valvular aortic stenosis. *Circulation* 1994;**89**:827–35.
- Blais C, Burwash IG, Mundigler G, Dumesnil JG, Loho N, Rader F et al. Projected valve area at normal flow rate improves the assessment of stenosis severity in patients with low-flow, low-gradient aortic stenosis: the multicenter TOPAS (Truly or Pseudo-Severe Aortic Stenosis) study. *Circulation* 2006;**113**:711–21.
- Nakatani S, Imanishi T, Terawawa A, Beppu S, Nagata S, Miyatake K. Clinical application of transpulmonary contrast-enhanced Doppler technique in the assessment of severity of aortic stenosis. *J Am Coll Cardiol* 1992;**20**:973–8.
- Mulvagh SL, Rakowski H, Vannan MA, Abdelmoneim SS, Becher H, Bierig SM et al. American Society of Echocardiography Consensus Statement on the Clinical Applications of Ultrasonic Contrast Agents in Echocardiography. *J Am Soc Echocardiogr* 2008;**21**:1179–201.
- Zoghbi WA, Farmer KL, Soto JG, Nelson JG, Quinones MA. Accurate non-invasive quantification of stenotic aortic valve area by Doppler echocardiography. *Circulation* 1986;**73**:452–9.
- Skjaerpe T, Hegrehaes L, Hatle L. Noninvasive estimation of valve area in patients with aortic stenosis by Doppler ultrasound and two-dimensional echocardiography. *Circulation* 1985;**72**:810–8.
- Kamperidis V, van Rosendaal PJ, Katsanos S, van der Kley F, Regeer M, Al Amri I et al. Low gradient severe aortic stenosis with preserved ejection fraction: reclassification of severity by fusion of Doppler and computed tomographic data. *Eur Heart J* 2015;**36**:2087–96.
- Khaw AV, von Bardeleben RS, Strasser C, Mohr-Kahaly S, Blankenbarg S, Espinola-Klein C et al. Direct measurement of left ventricular outflow tract by transthoracic real-time 3D-echocardiography increases accuracy in assessment of aortic valve stenosis. *Int J Cardiol* 2009;**136**:64–71.
- Gaspar T, Adawi S, Sachner R, Asmer I, Ganaem M, Rubinshtein R et al. Three-dimensional imaging of the left ventricular outflow tract: impact on aortic valve area estimation by the continuity equation. *J Am Soc Echocardiogr* 2012;**25**:749–57.
- Mehrotra P, Flynn AW, Jansen K, Tan TC, Mak G, Julien HM et al. Differential left ventricular outflow tract remodeling and dynamics in aortic stenosis. *J Am Soc Echocardiogr* 2015;**28**:1259–66.
- Jainandunsing JS, Mahmood F, Matyal R, Shakil O, Hess PE, Lee J et al. Impact of three-dimensional echocardiography on classification of the severity of aortic stenosis. *Ann Thorac Surg* 2013;**96**:1343–8.
- Rosenhek R, Klaar U, Schemper M, Scholten C, Heger M, Gabriel H et al. Mild and moderate aortic stenosis. Natural history and risk stratification by echocardiography. *Eur Heart J* 2004;**25**:199–205.
- Gilon D, Cape EG, Handschumacher MD, Song JK, Solheim J, VanAuker M et al. Effect of three-dimensional valve shape on the hemodynamics of aortic stenosis: three-dimensional echocardiographic stereolithography and patient studies. *J Am Coll Cardiol* 2002;**40**:1479–86.
- Otto CM, Pearlman AS, Kraft CD, Miyake-Hull CY, Burwash IG, Gardner CJ. Physiologic changes with maximal exercise in asymptomatic valvular aortic stenosis assessed by Doppler echocardiography. *J Am Coll Cardiol* 1992;**20**:1160–7.

43. Lancellotti P, Lebois F, Simon M, Tombeux C, Chauvel C, Pierard LA. Prognostic importance of quantitative exercise Doppler echocardiography in asymptomatic valvular aortic stenosis. *Circulation* 2005;**112**(9 Suppl):1377–82.
44. Okura H, Yoshida K, Hozumi T, Akasaka T, Yoshikawa J. Planimetry and trans-thoracic two-dimensional echocardiography in noninvasive assessment of aortic valve area in patients with valvular aortic stenosis. *J Am Coll Cardiol* 1997;**30**:753–9.
45. Cormier B, lung B, Porte JM, Barbant S, Vahanian A. Value of multiplane transe-sophageal echocardiography in determining aortic valve area in aortic stenosis. *Am J Cardiol* 1996;**77**:882–5.
46. Stoddard MF, Aree J, Liddell NE, Peters G, Dillon S, Kupersmith J. Two-dimen-sional transeophageal echocardiographic determination of aortic valve area in adults with aortic stenosis. *Am Heart J* 1991;**122**:1415–22.
47. Carabello BA. Aortic stenosis. *NEJM* 2002;**346**:677–82.
48. Minners J, Allgeier M, Gohlke-Baerwolf C, Kienzle RP, Neumann FJ, Jander N. Inconsistent grading of aortic valve stenosis by current guidelines: haemodynamic stud-ies in patients with apparently normal left ventricular function. *Heart* 2010;**96**:1463–8.
49. Michelena HI, Margaryan E, Miller FA, Eleid M, Maalouf J, Suri R et al. Inconsistent echocardiographic grading of aortic stenosis: is the left ventricular outflow tract important? *Heart* 2013;**99**:921–31.
50. Monin JL, Monchi M, Gest V, Duval-Moulin AM, Dubois-Rande JL, Gueret P. Aortic stenosis with severe left ventricular dysfunction and low transvalvular pressure gradients: risk stratification by low-dose dobutamine echocardiography. *J Am Coll Cardiol* 2001;**37**:2101–7.
51. Nishimura RA, Grantham JA, Connolly HM, Schaff HV, Higano ST, Holmes DR Jr. Low-output, low-gradient aortic stenosis in patients with depressed left ven-tricular systolic function: the clinical utility of the dobutamine challenge in the catheterization laboratory. *Circulation* 2002;**106**:809–13.
52. Monin JL, Quéré J-P, Monchi M, Petit H, Baleynaude S, Chauvel C et al. Low-gradi-ent aortic stenosis operative risk stratification and predictors for long-term out-come: a multicenter study using dobutamine stress hemodynamics. *Circulation* 2003;**108**:319–24.
53. Clavel M-A, Burwash IG, Mundigler G, Dumesnil JG, Baumgartner H, Bergler-Klein J et al. Validation of conventional and simplified methods to calculate pro-jected valve area at normal flow rate in patients with low flow, low gradient aor-tic stenosis: the multicenter TOPAS (True or Pseudo Severe Aortic Stenosis) study. *J Am Soc Echocardiogr* 2010;**23**:380–6.
54. Fougeres E, Tribouilloy C, Monchi M, Petit-Eisenmann H, Baleynaude S, Pasquet A et al. Outcomes of pseudo-severe aortic stenosis under conservative treatment. *Eur Heart J* 2012;**33**:2426–33.
55. Hachicha Z, Dumesnil JG, Bogaty P, Pibarot P. Paradoxical low-flow, low-gradient severe aortic stenosis despite preserved ejection fraction is associated with higher afterload and reduced survival. *Circulation* 2007;**115**:2856–64.
56. Pibarot P, Dumesnil JG. Low-flow, low-gradient aortic stenosis with normal and depressed left ventricular ejection fraction. *J Am Coll Cardiol* 2012;**60**:1845–53.
57. Clavel M-A, Ennezat PV, Maréchaux S, Dumesnil JG, Capoulade R, Hachicha Z et al. Stress echocardiography to assess stenosis severity and predict outcome in patients with paradoxical low-flow, low-gradient aortic stenosis and preserved LVEF. *JACC Cardiovasc Imaging* 2013;**6**:175–83.
58. Cueff C, Serfaty J-M, Cimadevilla C, Laissy JP, Himbert D, Tubach F et al. Measurement of aortic valve calcification using multislice computed tomography: correlation with haemodynamic severity of aortic stenosis and clinical implication for patients with low ejection fraction. *Heart* 2011;**97**:721–6.
59. Clavel M-A, Messika-Zeitoun D, Pibarot P, Aggarwal SR, Malouf J, Araoz PA et al. The complex nature of discordant severe calcified aortic valve disease grading: new insights from combined Doppler echocardiographic and computed tomographic study. *J Am Coll Cardiol* 2013;**62**:2329–38.
60. Aggarwal SR, Clavel M-A, Messika-Zeitoun D, Cuff C, Malouf J, Araoz PA et al. Sex differences in aortic valve calcification measured by multidetector computed tomography in aortic stenosis. *Circ Cardiovasc Imaging* 2013;**6**:40–7.
61. Ozkan A, Hachamovitch R, Kapadia SR, Tuzcu EM, Marwick TH. Impact of aortic valve replacement on outcome of symptomatic patients with severe aortic stenosis with low gradient and preserved left ventricular ejection fraction. *Circulation* 2013;**128**:622–31.
62. Mehrotra P, Jansen K, Flynn AW, Tan TC, Elmariah S, Picard MH et al. Differential left ventricular remodelling and longitudinal function distinguishes low flow from normal-flow preserved ejection fraction low-gradient severe aor-tic stenosis. *Eur Heart J* 2013;**34**:1906–14.
63. Eleid MF, Sorajja P, Michelena HI, Malouf JF, Scott CG, Pellikka PA. Flow-gradient patterns in severe aortic stenosis with preserved ejection fraction: clinical char-acteristics and predictors of survival. *Circulation* 2013;**128**:1781–9.
64. Chahal NS, Drakopoulou M, Gonzalez-Gonzalez AM, Manivarmane R, Khattar R, Senior R. Resting aortic valve area at normal transaortic flow rate reflects true valve area in suspected low-gradient severe aortic stenosis. *JACC Cardiovasc Imaging* 2015;**8**:1133–9.
65. Lancellotti P, Donal E, Magne J, O'Connor K, Moonen ML, Cosyns B et al. Impact of global left ventricular afterload on left ventricular function in asymptomatic severe aortic stenosis: a two-dimensional speckle-tracking study. *Eur J Echocardiogr* 2010;**11**:537–43.
66. Delgado V, Tops LF, van Bommel RJ, van der Kley F, Marsan NA, Klautz RJ et al. Strain analysis in patients with severe aortic stenosis and preserved left ventricu-lar ejection fraction undergoing surgical valve replacement. *Eur Heart J* 2009;**30**:3037–47.
67. Kempny A, Diller GP, Kaleschke G, Orwat S, Funke A, Radke R et al. Longitudinal left ventricular 2D strain is superior to ejection fraction in predicting myocardial recovery and symptomatic improvement after aortic valve implanta-tion. *Int J Cardiol* 2013;**167**:2239–43.
68. Maciver DH, Townsend M. A novel mechanism of heart failure with normal ejec-tion fraction. *Heart* 2008;**94**:446–9.
69. Weidemann F, Herrmann S, Stork S, Niemann M, Frantz S, Lange V et al. Impact of myocardial fibrosis in patients with symptomatic severe aortic stenosis. *Circulation* 2009;**120**:577–84.
70. Lancellotti P, Moonen M, Magne J, O'Connor K, Cosyns B, Attenu E et al. Prognostic effect of long-axis left ventricular dysfunction and B-type natriuretic peptide levels in asymptomatic aortic stenosis. *Am J Cardiol* 2010;**105**:383–8.
71. Kearney LG, Lu K, Ord M, Patel SK, Proffits K, Matalanis G et al. Global longitu-dinal strain is a strong independent predictor of all-cause mortality in patients with aortic stenosis. *Eur Heart J Cardiovasc Imaging* 2012;**13**:827–33.
72. Dahl JS, Videbaek L, Poulsen MK, Rudbaek TR, Pellikka PA, Moller JE. Global strain in severe aortic valve stenosis: Relation to clinical outcome after aortic valve replacement. *Circ Cardiovasc Imaging* 2012;**5**:613–20.
73. Voigt JU, Pedrizzetti G, Lysyansky P, Marwick TH, Houle H, Baumann R et al. Definitions for a common standard for 2D speckle tracking echocardiography: consensus document of the EACVI/ASE/Industry Task Force to standardize de-formation imaging. *Eur Heart J Cardiovasc Imaging* 2015;**16**:1.
74. Cioffi G, Faggiano P, Vizzardi E, Tarantini L, Cramariuc D, Gerdtts E et al. Prognostic value of inappropriately high left ventricular mass in asymptomatic se-vere aortic stenosis. *Heart* 2011;**97**:301–7.
75. Zilberszac R, Gabriel H, Schemper M, Zahler D, Czerny M, Maurer G et al. Outcome of combined stenotic and regurgitant aortic valve disease. *J Am Coll Cardiol* 2013;**61**:1489–95.
76. Zoghbi WA, Adams D, Bonow RO, Enriquez-Sarano M, Foster E, Grayburn PA et al. Recommendations for non-invasive evaluation of native valvular regurgita-tion: A report from the American Society of Echocardiography developed in col-laboration with the Society for Cardiovascular Magnetic Resonance. *J Am Soc Echocardiogr* doi:10.1016/j.echo.2017.01.007.
77. Mascherbauer J, Fuchs C, Stoiber M, Schima H, Pernicka E, Maurer G et al. Systemic pressure does not directly affect pressure gradient and valve area esti-mates in aortic stenosis *in vitro*. *Eur Heart J* 2008;**29**:2049–57.
78. Kadem L, Dumesnil JG, Rieu R, Durand LG, Garcia D, Pibarot P. Impact of systemic hypertension on the assessment of aortic stenosis. *Heart* 2005;**91**: 354–61.
79. Little SH, Chan KL, Burwash IG. Impact of blood pressure on the Doppler echo-cardiographic assessment of severity of aortic stenosis. *Heart* 2007;**93**:848–55.
80. Otto CM. Valvular aortic stenosis: disease severity and timing of inter-vention. *J Am Coll Cardiol* 2006;**47**:2141–51.
81. Rosenhek R, Zilberszac R, Schemper M, Czerny M, Mundigler G, Graf S et al. Natural history of very severe aortic stenosis. *Circulation* 2010;**121**:151–6.
82. Henkel DM, Malouf JF, Connolly HM, Michelena HI, Sarano ME, Schaff HV et al. Asymptomatic left ventricular systolic dysfunction in patients with severe aortic stenosis: Characteristics and outcomes. *J Am Coll Cardiol* 2012;**60**:2325–9.
83. Maréchaux S, Hachicha Z, Bellouin A, Dumesnil JG, Meimoun P, Pasquet A et al. Usefulness of exercise-stress echocardiography for risk stratification of true asymptomatic patients with aortic valve stenosis. *Eur Heart J* 2010;**31**: 1390–7.
84. Zuern CS, Eick C, Rizas K, Stoleriu C, Woernle B, Wildhirt S et al. Prognostic value of mild-to-moderate pulmonary hypertension in patients with severe aortic valve stenosis undergoing aortic valve replacement. *Clin Res Cardiol* 2012;**101**:81–8.
85. Lancellotti P, Magne J, Donal E, O'Connor K, Dulgheru R, Rosca M et al. Determinants and prognostic significance of exercise pulmonary hypertension in asymptomatic severe aortic stenosis. *Circulation* 2012;**126**:851–9.
86. Mutlak D, Aronson D, Carasso S, Lessick J, Reiser SA, Agmon Y. Frequency, de-terminants and outcome of pulmonary hypertension in patients with aortic valve stenosis. *Am J Med Sci* 2012;**343**:397–401.
87. Zlotnick DM, Ouellette ML, Malenka DJ, DeSimone JP, Leavitt BJ, Helm RE et al. Effect of preoperative pulmonary hypertension on outcomes in patients with se-vere aortic stenosis following surgical aortic valve replacement. *The Am J Cardiol* 2013;**112**:1635–40.
88. Miceli A, Varone E, Gilmanov D, Murzi M, Simeoni S, Conciatrè G et al. Impact of pulmonary hypertension on mortality after operation for isolated aortic valve stenosis. *Int J Cardiol* 2013;**168**:3556–9.