

THE PRESENT AND FUTURE

STATE-OF-THE-ART REVIEW

Prosthetic Heart Valve Thrombosis

George D. Dangas, MD, PhD,^a Jeffrey I. Weitz, MD,^b Gennaro Giustino, MD,^a Raj Makkar, MD,^c
Roxana Mehran, MD^a



JACC JOURNAL CME

This article has been selected as the month's JACC Journal CME activity, available online at <http://www.acc.org/jacc-journals-cme> by selecting the CME tab on the top navigation bar.

Accreditation and Designation Statement

The American College of Cardiology Foundation (ACCF) is accredited by the Accreditation Council for Continuing Medical Education (ACCME) to provide continuing medical education for physicians.

The ACCF designates this Journal-based CME activity for a maximum of 1 *AMA PRA Category 1 Credit(s)*. Physicians should only claim credit commensurate with the extent of their participation in the activity.

Method of Participation and Receipt of CME Certificate

To obtain credit for JACC CME, you must:

1. Be an ACC member or JACC subscriber.
2. Carefully read the CME-designated article available online and in this issue of the journal.
3. Answer the post-test questions. At least 2 out of the 3 questions provided must be answered correctly to obtain CME credit.
4. Complete a brief evaluation.
5. Claim your CME credit and receive your certificate electronically by following the instructions given at the conclusion of the activity.

CME Objective for This Article: Upon completion of this activity, the learner should be able to: 1) describe the types of prosthetic heart valves; 2) understand the thrombogenic mechanisms of prosthetic heart valves; 3) classify types of medical therapy to prevent prosthetic heart valve thrombosis; and 4) understand clinical outcomes after heart valve replacement.

CME Editor Disclosure: JACC CME Editor Ragavendra R. Baliga, MD, has reported that he has no relationships to disclose.

Author Disclosures: Dr. Dangas is a consultant to Janssen Pharmaceuticals (spouse), CSL Behring (spouse), AstraZeneca (spouse), Medtronic, Abbott Vascular (spouse), Bayer, Boston Scientific, and Daiichi-Sankyo; his institution has received research grant support from Bayer, Janssen, and The Medicines Company; and reports minor stock options from Claret Medical (spouse). Dr. Weitz has served as a consultant and has received honoraria from Bayer, Janssen Pharmaceuticals, Bristol-Myers Squibb, Pfizer, Boehringer Ingelheim, Daiichi-Sankyo, Merck, Portola, and Ionis Pharmaceuticals. Dr. Makkar is the principal investigator for the St. Jude Medical Portico trial; has received research grants from Edwards Lifesciences, St. Jude Medical, and Medtronic; and has received consulting fees from Abbott Vascular, Cordis, Edwards Lifesciences, and Medtronic. Dr. Mehran has received institutional grant support from The Medicines Company, Bristol-Myers Squibb, Sanofi, Eli Lilly & Company, OrbusNeich, Bayer, CSL Behring, and Daiichi-Sankyo; is a consultant to Janssen Pharmaceuticals, Osprey Medical, Watermark Research Partners, Medscape, AstraZeneca, Abbott Vascular, and CSL Behring; is on the scientific advisory board of Abbott Laboratories; and reports minor stock options from Claret Medical. Dr. Giustino has reported that he has no relationships relevant to the contents of this paper to disclose. Deepak L. Bhatt, MD, MPH, served as Guest Editor-in-Chief for this paper.

Medium of Participation: Print (article only); online (article and quiz).

CME Term of Approval

Issue Date: December 20, 2016

Expiration Date: December 19, 2017

From ^aThe Zena and Michael A. Wiener Cardiovascular Institute, The Icahn School of Medicine at Mount Sinai, New York, New York; ^bDepartments of Medicine and Biochemistry and Biomedical Sciences, McMaster University, Hamilton, Ontario, Canada; Thrombosis and Atherosclerosis Research Institute, Hamilton, Ontario, Canada; and the ^cDepartment of Cardiology, Cedars-Sinai Medical Center, Los Angeles, California. Dr. Dangas is a consultant to Janssen Pharmaceuticals (spouse), CSL Behring (spouse), AstraZeneca (spouse), Medtronic, Abbott Vascular (spouse), Bayer, Boston Scientific, and Daiichi-Sankyo; his institution has received research grant support from Bayer, Janssen, and The Medicines Company; reports minor stock options from Claret Medical (spouse). Dr. Weitz has served as a consultant and has received honoraria from Bayer, Janssen Pharmaceuticals, Bristol-Myers Squibb, Pfizer, Boehringer Ingelheim, Daiichi-Sankyo, Merck, Portola, and Ionis Pharmaceuticals. Dr. Makkar is the principal investigator for the St. Jude Medical Portico trial; has received research grants from Edwards Lifesciences, St. Jude Medical, and Medtronic; and has received consulting fees from Abbott Vascular, Cordis, Edwards Lifesciences, and Medtronic. Dr. Mehran has received institutional grant support from The Medicines Company, Bristol-Myers Squibb, Sanofi, Eli Lilly & Company, OrbusNeich, Bayer, CSL Behring, and Daiichi-Sankyo; is a consultant to Janssen Pharmaceuticals, Osprey Medical, Watermark Research Partners, Medscape, AstraZeneca, Abbott Vascular, and CSL Behring; is on the scientific advisory board of Abbott Laboratories; and reports minor stock options from Claret Medical. Dr. Giustino has reported that he has no relationships relevant to the contents of this paper to disclose. Deepak L. Bhatt, MD, MPH, served as Guest Editor-in-Chief for this paper.

Manuscript received May 24, 2016; revised manuscript received September 19, 2016, accepted September 20, 2016.



Listen to this manuscript's audio summary by JACC Editor-in-Chief Dr. Valentin Fuster.



Prosthetic Heart Valve Thrombosis

George D. Dangas, MD, PhD,^a Jeffrey I. Weitz, MD,^b Gennaro Giustino, MD,^a Raj Makkar, MD,^c Roxana Mehran, MD^a

ABSTRACT

Although surgery was the mainstay of treatment for valvular heart disease, transcatheter valve therapies have grown exponentially over the past decade. Two types of artificial heart valve exist: mechanical heart valves (MHV), which are implanted surgically, and bioprosthetic heart valves (BHV), which can be implanted via a surgical or transcatheter approach. Whereas long-term anticoagulation is required to prevent thromboembolism after MHV replacement, its value in patients receiving BHVs is uncertain. Patients undergoing transcatheter BHV replacement are at risk for thromboembolism in the first few months, and recent data suggest that the risk continues thereafter. BHV thrombosis provides a substrate for subsequent thromboembolism and may identify a reversible cause of prosthesis dysfunction. Hereafter, the authors: 1) review the data on prosthetic valve thrombosis; 2) discuss the pathophysiological mechanisms that may lead to valve thrombus formation; and 3) provide perspective on the implications of these findings in the era of transcatheter valve replacement. (J Am Coll Cardiol 2016;68:2670-89) © 2016 by the American College of Cardiology Foundation.

PROSTHETIC HEART VALVE THROMBOSIS: BACKGROUND AND DEFINITIONS

Valvular heart disease affects more than 100 million persons worldwide, and is associated with significant morbidity and mortality (1). In the last 50 years, the epidemiology of valvular disorders has drastically changed, with a marked reduction in the incidence and prevalence of rheumatic heart disease and a substantial increase in the prevalence of degenerative valve diseases. Currently, the overall age-adjusted prevalence of mitral or aortic valvular heart disease is estimated to be 2.5% in the general population of the United States, with a prevalence exceeding 10% in subjects over 75 years of age (1). Given the aging of the population worldwide, the prevalence of such pathologies is expected to rise exponentially (1).

Surgical valve replacement (or repair of mitral valves) is currently the standard of care for treatment of valvular heart disease in patients at low and intermediate risk for surgery (2). However, in the last 10 years, a proliferation of transcatheter technologies now offers alternatives to surgery, especially in patients at high or prohibitive risk. Transcatheter valve therapies for aortic stenosis and mitral regurgitation are currently an established treatment option in patients not suitable for conventional surgical treatment (2), or of at least intermediate risk for aortic surgery.

On the basis of the leaflet material, 2 different types of surgical prosthetic heart valves exist (Figure 1): mechanical and biological (3). Mechanical heart valves (MHVs) are more thrombogenic, yet more durable. These valves have evolved from the early caged ball and tilting disc design to the contemporary bileaflet

valves mounted on a Teflon- or Dacron-covered sewing ring (3). Bioprosthetic heart valves (BHVs) are less thrombogenic than MHV and exhibit more natural hemodynamic properties, but are less durable (3). Surgical BHVs are either of porcine origin or are synthesized from a sheet of bovine pericardium that is mounted on a frame or stent and covered by fabric, which serves as a sewing ring (3). Stentless BHVs have also been developed; these provide greater effective orifice areas and lower transprosthetic gradients than stented prosthetic valves (PVs) (3). Conversely, all of the transcatheter aortic and mitral PVs consist of a porcine or bovine pericardial tissue trileaflet mounted on a self-expandable or balloon-expandable metallic frame (4). Initial forms of these valves included equine tissue leaflets.

All foreign bodies (including PVs) implanted within the human cardiovascular system are thrombogenic, potentially implying the need for short- or long-term anticoagulation to prevent thrombosis, which can lead to disabling or fatal stroke. PV thrombosis is a pathological entity characterized by thrombus formation on the prosthetic structures, with subsequent PV dysfunction with or without thromboembolism (TE) (5). PV dysfunction is a complication of mechanical or biological prostheses, which can cause reduced leaflet motion or impaired leaflet coaptation, leaflet thickening, reduced or increased effective prosthesis orifice area (leading to either stenosis or insufficiency as the primary valve defect, respectively), increased transvalvular gradient or transvalvular regurgitation, with or without development of valve-related symptoms (6,7). At least 4 main etiologies may account for PV dysfunction: 1) PV

ABBREVIATIONS AND ACRONYMS

AF	= atrial fibrillation
BHV	= biological heart valve
CI	= confidence interval
DAPT	= dual antiplatelet therapy
f	= factor
INR	= international normalized ratio
MHV	= mechanical heart valve
PV	= prosthetic valve
RR	= relative risk
TAVR	= transcatheter aortic valve replacement
TE	= thromboembolism
VKA	= vitamin K antagonist

thrombosis; 2) fibrotic pannus ingrowth; 3) PV degeneration; and 4) PV endocarditis with vegetation formation (6,7). These pathological entities may occur simultaneously, and a component of thrombus formation is often observed in concert with fibrotic pannus ingrowth, PV degeneration, or PV endocarditis (8). However, determination of the main etiology of PV dysfunction is crucial because the treatment differs for each of these conditions.

The type of PV, its anatomical location and patient-specific risks of TE and bleeding risks influence the specific intensity and duration of antithrombotic treatment to prevent PV thrombosis with subsequent PV dysfunction and/or TE (2). Recent data from computed tomography imaging studies suggest that

reduced leaflet motion and leaflet thickening after BHV implantation are relatively common phenomena that might be associated with an increased risk of stroke (9). Of note, reduced leaflet motion more commonly occurs in patients not receiving oral anticoagulants, and therapeutic anticoagulation is associated with resolution of reduced leaflet motion and hypoattenuated leaflet thickening, supporting a thrombotic origin (9,10). Given the exponential rise in transcatheter valve replacement and repair therapies, it is important to identify the optimal antithrombotic therapies/strategies to prevent PV thrombosis. Therefore, we set out to review the incidence, mechanisms, and clinical implications of PV thrombosis in the surgical era, and to translate this information to provide perspective on optimal long-term antithrombotic management in the era of transcatheter valve therapies.

SEARCH STRATEGY

We searched MEDLINE (from inception to April 2016) for papers using the search terms *prosthesis* or *valve* in combination with the terms *thrombosis*, *dysfunction*, *fibrosis*, *thromboembolism*, *stroke*, or *complications*. We mostly selected papers published between January 1, 2010, and April 2016, but did not exclude commonly referenced and highly regarded articles published before 2010. We also searched the reference lists of articles identified by this search strategy, and included those judged to be relevant.

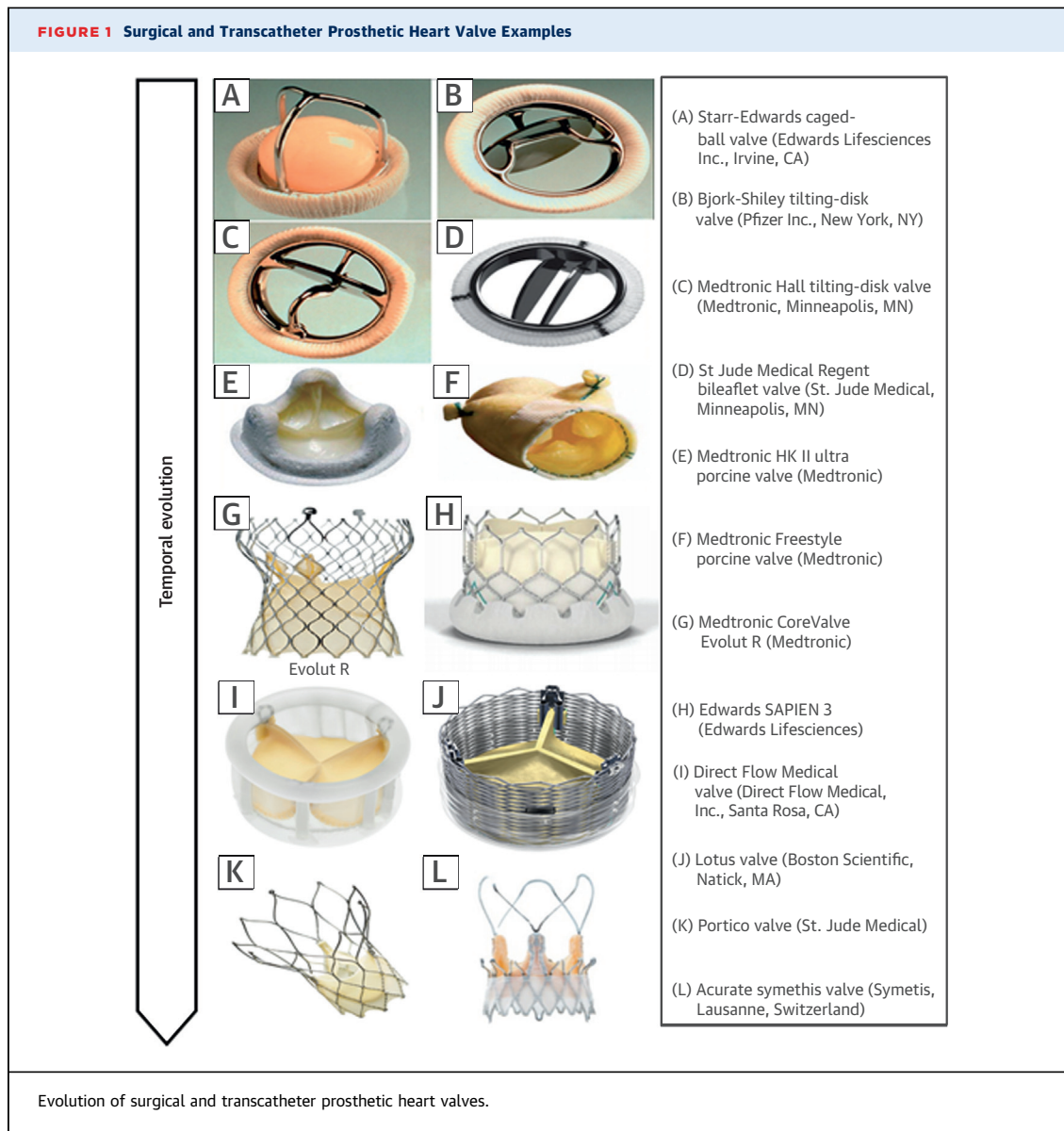
PROSTHETIC HEART VALVE THROMBOSIS: INCIDENCE

SURGICAL PVs. The reported rates of PV thrombosis are highly variable and most likely underestimate the

true incidence of this phenomenon because valve imaging is not performed routinely, and even if the valve is imaged, the technique may be suboptimal. A distinction should also be made between accumulation of small amounts of mural thrombus on the leaflets early after in vivo implantation, which may resolve with ensuing endothelialization, and progressive thrombosis on the leaflets, which may have hemodynamic or clinical consequences. Current American College of Cardiology (ACC)/American Heart Association (AHA) guidelines assign a Class I recommendation to transthoracic echocardiography or transesophageal echocardiography imaging in patients with PV only in the presence of clinical symptoms or signs of valve dysfunction. Conversely, in the absence of a change in clinical status, annual transthoracic echocardiography or transesophageal echocardiography imaging surveillance is only recommended starting 10 years after PV implantation (Class IIa recommendation). However, most PV thrombosis occurs/commences within months or a year after the index procedure (3,8,11).

The risk of PV thrombosis and TE events is higher with MHVs than with BHVs, higher for PVs implanted in the mitral position versus the aortic position, and higher for right-sided PVs than left-sided PVs (5). The annual rate of PV thrombosis with MHVs ranges from 0.1% to 5.7%, with higher rates observed with specific valve types, in the early perioperative period, with MHVs implanted in the mitral and tricuspid position, and in association with subtherapeutic anticoagulation (12). When considered in terms of MHV obstruction, the annual incidence ranges from 0.5% to 6.0% (12). In patients with MHVs, TE, which may or may not originate from the prosthesis, has an estimated annual incidence of 2.5% to 3.7% (12). Fibrotic pannus ingrowth with MHVs, manifesting as PV dysfunction, occurs with an estimated annual incidence of 0.2% to 4.5% (12). The reported incidence is influenced by the intensity and timing of serial imaging follow-up, and it is likely that many cases of thrombus formation remain undetected. In fact, in a study that included 680 consecutive patients undergoing mechanical mitral valve replacement, routine transesophageal echocardiography performed at day 9 identified thrombus in 64 patients (9.4%). Of these patients, 2 underwent early surgical intervention, whereas the others were managed with anticoagulant therapy. Outcomes varied depending on thrombus size; patients whose thrombus had a maximum size ≥ 5 mm had a significantly higher risk of TE, including stroke, than those with smaller thrombi (13).

In patients with BHVs, a meta-analysis that included 5,837 patients with a total follow-up of



31,874 patient-years reported annual rates of PV thrombosis and TE of 0.03% and 0.38%, respectively (2,14). In a recent single-center study that included 397 consecutive explanted BHVs, PV thrombosis was identified in 46 valves (11.6%). Of these, 29 were aortic (10.9%), 9 were mitral (12.7%), 7 were tricuspid (12.1%), and 1 was pulmonic. On the basis of the total number of valves implanted during the study interval, the estimated annual incidence of PV thrombosis was 0.74%, with the highest annual incidence observed with BHVs implanted in the tricuspid position (1.00%) (2). The type of surgical BHV also appears to influence the risk of PV thrombosis; thus, the risk of thrombosis is higher with stented porcine BHVs than with stentless BHVs (15). The risk of PV thrombosis in

these patients is highest in the first 3 months after implantation, and absence of therapeutic anticoagulation is reported to be an independent predictor of TE with both surgically implanted MHVs and BHVs (16,17). However, there is evidence that the risk of BHV thrombosis may persist beyond 1 year after valve implantation, which underscores the importance of serial imaging follow-up, and a careful evaluation of the risks and benefits of long-term anticoagulation (18).

TRANSCATHETER PVs. The incidence of overt PV thrombosis and TE after transcatheter aortic valve replacement (TAVR) is uncertain. There were no cases of PV thrombosis in the PARTNER (Placement of Aortic Transcatheter Valves) and CoreValve trials

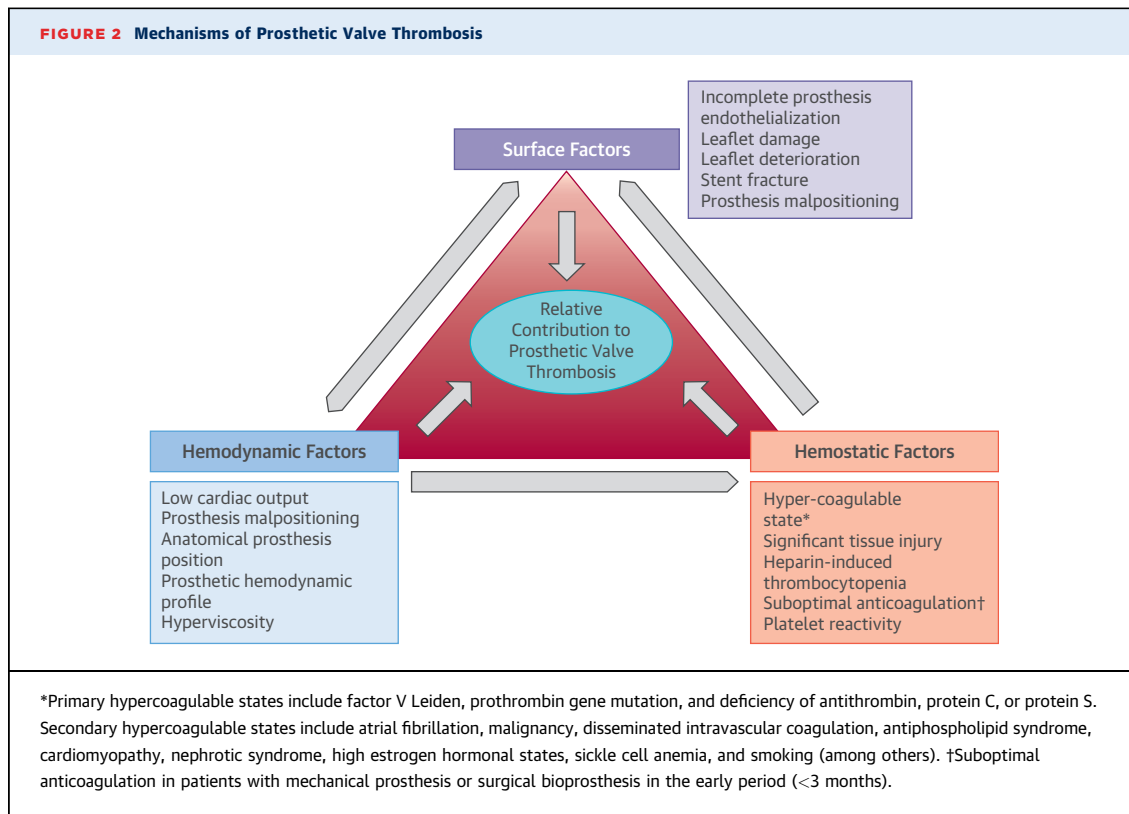
(19-21), and only a single case of PV thrombosis was reported in the 130 TAVR patients enrolled in the PARTNER EU registry. In 4,266 patients undergoing TAVR in 12 centers between January 2008 and September 2013, Latib et al. (22) reported 26 cases of PV thrombosis (0.61%) within a median of 181 days (interquartile range: 45 to 313 days) of implantation. The risk of TE and PV thrombosis after TAVR is highest in the first 3 months after valve replacement; the risk thereafter appears to decrease to match that in the general population (23). This early timeframe largely coincides with that observed with surgical BHVs, and currently, an initial 3- to 6-month course of oral anticoagulation therapy is generally recommended for patients with surgically implanted BHVs (2,24,25). In fact, histopathological studies with the CoreValve system suggest that physiological neointimal tissue proliferation and device endothelialization are completed approximately 3 months after the index procedure (26-30). With surgical MHVs or BHVs and with transcatheter BHVs, the incidence of thrombus formation with or without PV dysfunction is likely influenced by the intensity and timing of screening. Analysis of computed tomography imaging data, obtained at a median of 32 days after valve replacement in 55 patients enrolled in the PORTICO IDE trial (Portico Re-sheathable Transcatheter Aortic Valve System US IDE Trial), identified reduced leaflet motion in 40%. In 132 patients undergoing transcatheter or surgical BHV implantation enrolled in the SAVORY (Subclinical Aortic Valve Bioprosthesis Thrombosis Assessed With 4D CT) or RESOLVE (Assessment of Transcatheter and Surgical Aortic Bioprosthetic Valve Thrombosis and Its Treatment with Anticoagulation) registries (9), computed tomography imaging performed within 3 months identified reduced leaflet motion in 13% of patients, including 14% with transcatheter BHVs and 7% with surgical BHVs (9). In both patient populations, the prevalence of reduced leaflet motion was lower in patients already on anticoagulants, and initiation of therapeutic anticoagulation was associated with resolution of reduced leaflet motion at follow-up, supporting the concept that reduced leaflet motion reflects thrombosis (9). Of concern, in the pooled registries, the risk of stroke or transient ischemic attack was higher in those with reduced leaflet motion than in those without (9). The study of Pache et al. (10) supports this concept; these investigators followed 156 consecutive patients who underwent TAVR with the SAPIEN 3 (Edwards Lifesciences, Irvine, California). Multidetector computed tomography scanning performed at a median of 5 days after the procedure revealed leaflet thickening with

hypoattenuation in 16 patients (10.3%). Although these patients were asymptomatic, they had higher mean transvalvular gradients, and therapeutic anticoagulation resulted in complete resolution of the leaflet thickening. Patients with leaflet thickening were less frequently taking dual antiplatelet therapy (DAPT) than those without this finding (37.5% and 50%, respectively), but this difference did not reach statistical significance (10). Leetmaa et al. (26) reported similar findings. Recently, Hansson et al. (27) investigated the incidence and predictors of PV thrombosis in patients undergoing TAVR with balloon-expandable valves (the Edwards Sapien XT or Sapien 3 valves). Patients received transthoracic or transesophageal echocardiography and multidetector computed tomography to screen for PV thrombosis at 1 to 3 months. PV thrombosis verified with multidetector computed tomography was present in 7% of patients. Of these, 18% had clinically overt PV thrombosis, and the remainder had subclinical PV thrombosis. By multivariable analysis, the 2 independent predictors of PV thrombosis were lack of post-TAVR warfarin treatment and larger PV size (27).

PROSTHETIC HEART VALVE THROMBOSIS: MECHANISMS

PV thrombosis with or without PV dysfunction is a complex multifactorial phenomenon. According to the principles of Virchow's triad (28), the 3 main mechanisms of endovascular thrombus formation involve surface-, hemodynamic-, and hemostasis-related factors (Figure 2).

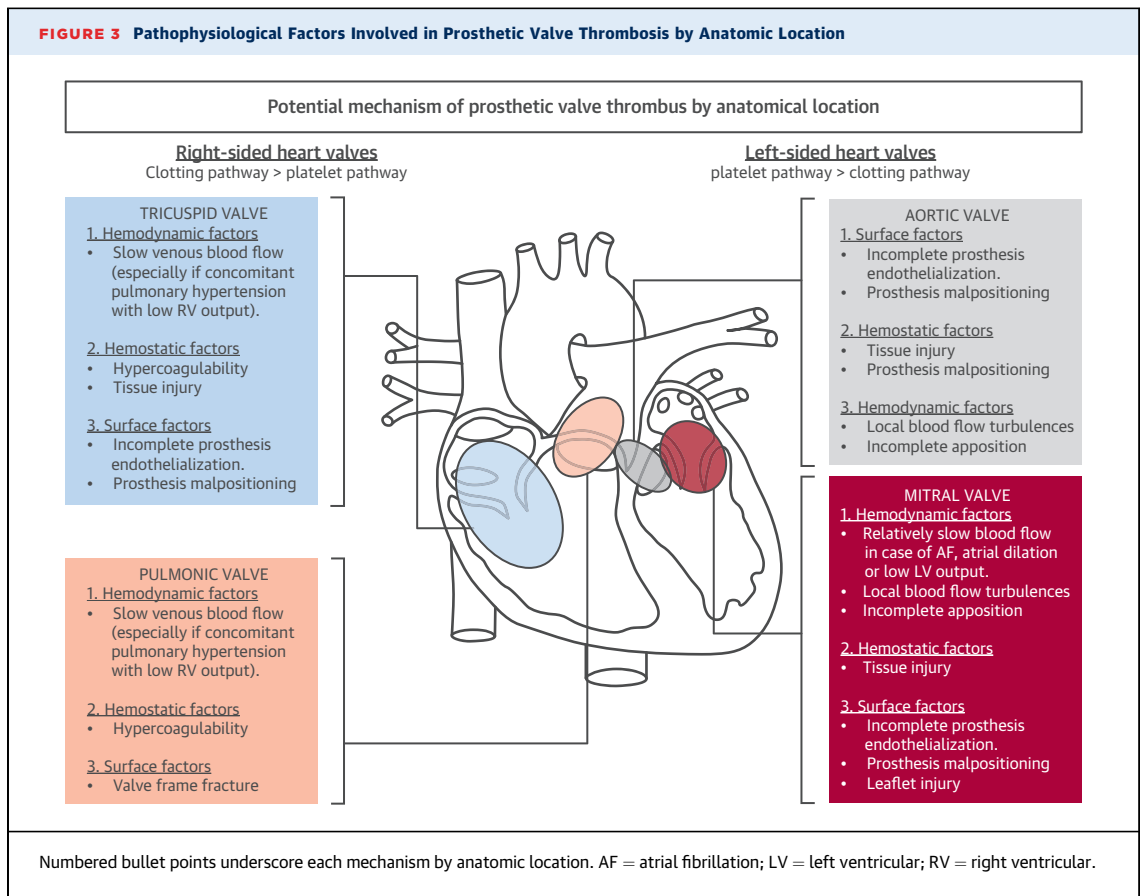
SURFACE FACTORS. In contrast to the healthy endothelium, which actively resists thrombosis, artificial surfaces promote clotting through a complex series of interconnected processes that include protein adsorption; adhesion of platelets, leukocytes, and red blood cells; thrombin generation; and complement activation. Rapid surface adsorption of plasma proteins is thought to be the initiating event in thrombus formation because the protein layer modulates subsequent reactions. Fibrinogen is one of the first plasma proteins to deposit on artificial surfaces. Other adhesive proteins, including fibronectin and von Willebrand factor, also adsorb to the surface and, together with fibrinogen, mediate platelet adhesion. The adherent platelets become activated and release adenosine diphosphate, thromboxane A₂, and other agonists, which recruit additional platelets to the surface. Adsorbed fibrinogen is soon replaced with components of the contact system, including factor (f) XII, high-molecular-weight kininogen, prekallikrein, and fXI (29). Activation of bound fXII not



only triggers thrombin generation via the intrinsic pathway of coagulation, but also induces complement activation. With crosstalk between the complement and coagulation pathways, complement activation amplifies thrombin generation, resulting in the formation of a platelet-fibrin network on the prosthetic surface. After approximately 3 months, the fibrin coat is replaced by a neointima composed of smooth muscle cells, elastic extracellular matrix, and endothelial cells (30). Over time, the neointimal layer matures and becomes more fibrotic. Whereas the sewing ring of a surgical BHV limits neointimal invasion of the leaflets, the leaflets of transcatheter heart valves may be more prone to neointimal coverage and/or pannus formation because these valves lack a sewing ring. Enhanced endothelialization and pannus formation may reduce leaflet motion (30). With transcatheter valves, the native valve leaflets, which are displaced outwards by the stent platform of the new valve, may also trigger thrombosis because stenotic native aortic valve leaflets are rich in tissue factor (31).

HEMODYNAMIC FACTORS. Hemodynamic factors include the host cardiocirculatory hemodynamic status and the intrinsic hemodynamic characteristics of

the prosthesis. Turbulence contributes to neointimal injury or dysfunction, and produces low shear stress conditions, whereas stasis increases blood coagulability (28). Low cardiac output is a predictor of PV thrombosis and reduced leaflet motion with thrombus formation (9,32). Low output states promote hypercoagulability by reducing the washout and dilution of activated clotting factors, and limiting the inflow of inhibitors in the vicinity of the valve (33). Conversely, regional turbulence disrupts laminar flow and promotes platelet adhesion to the valve surface. Turbulence may also delay endothelialization and induce a prothrombotic phenotype, a mechanism that appears to be more important for MPVs and that may particularly affect malpositioned surgical or transcatheter BPVs (5). In particular, incompletely apposed transcatheter heart valves may create areas of stasis between the metallic frame and host tissues that may promote local thrombus formation (34) and delay endothelialization (34). The importance of hemodynamic factors in the pathogenesis of PV thrombosis is evident from the difference in the risk of thrombosis depending on the anatomic position of the prosthesis (Figure 3). Thus, PV thrombosis has been reported nearly 20 times more frequently with the tricuspid valve than with the mitral valve, reflecting the slower



flow in the right-sided cardiac chambers (5). Likewise, mitral PV thrombosis is 2 to 3 times more frequent than aortic PV thrombosis (5).

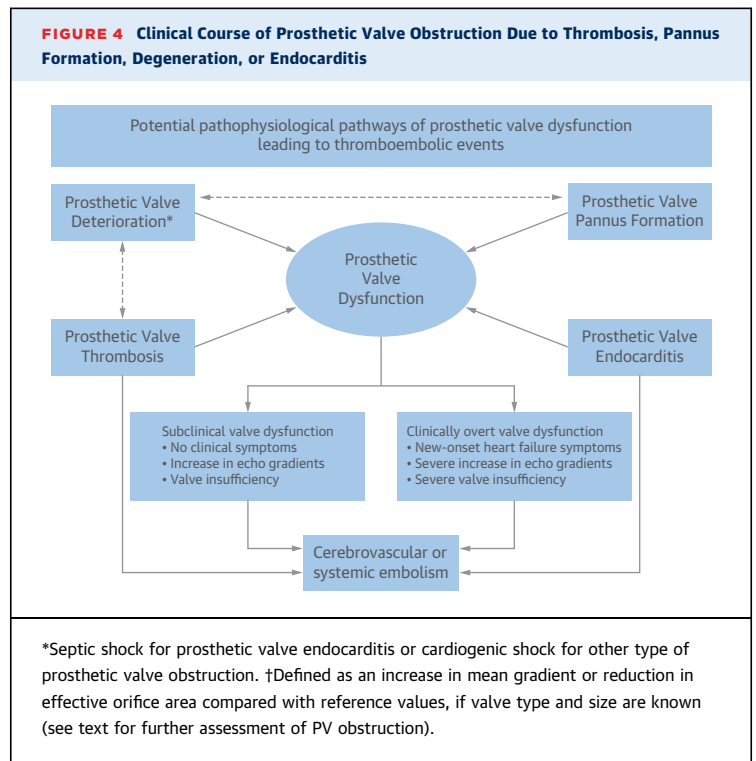
HEMOSTATIC FACTORS. Primary or secondary hypercoagulability is a less frequent mechanism in PV thrombosis, but may be an important contributor in high-risk patients, such as those undergoing transcatheter therapies. Acquired causes of hypercoagulability include comorbidities such as chronic kidney disease, anemia, smoking, and obesity. In addition, local tissue injury during surgical (excessive tissue manipulation) or transcatheter (aggressive pre- or post-dilation, excessive catheter manipulation) valve replacement may expose tissue factor to the blood, thereby inducing local activation of the extrinsic coagulation pathway (31,35). This mechanism may be particularly relevant with severely degenerated native valves (both aortic and mitral), which demonstrate increased tissue factor expression on the endothelial surface (31,35). Because the native diseased valve is not removed, this tissue factor may be responsible for short- to mid-term local thrombogenicity, even after a successful procedure (31,35).

PV thrombosis is usually a subacute or chronic process, rather than an acute phenomenon. Pathological studies suggest that fresh thrombi are less common, and that the main pathological entity is characterized by organized thrombus with multiple clot layers (34,36). Moreover, several studies suggest that thrombosis occurs in conjunction with other mechanisms of PV dysfunction, such as fibrotic pannus ingrowth, structural degeneration, and vegetation in the context of prosthetic valve endocarditis (3,5,8,9). Pannus ingrowth represents a distinct mechanism of PV dysfunction, but can occur in conjunction with thrombus formation (6). Fibrotic pannus ingrowth can be defined as an exaggerated biological reaction to the implanted foreign body, characterized by fibroblast proliferation and extracellular matrix deposition over the prosthetic leaflets, which leads to reduced leaflet motion and manifests clinically with PV dysfunction (6,7). As it is fibrotic in nature, pannus is generally unaffected by routine anticoagulation (6,7). However, a thrombus layer can form either as a consequence of the pannus or in conjunction with it (6,7). Bioprosthetic degeneration,

another mechanism of PV failure, is influenced by host-related factors (younger age, ejection fraction, hypertension, chronic kidney disease, smoking, diabetes, hypercholesterolemia, among others) and valve-related factors (type of valve, correct implantation), and is characterized by structural degeneration with calcium crystal formation, immunological reaction, and in-leaflet atherosclerosis with infiltration of oxidized low-density lipoproteins and foam cell formation (37). The exact mechanisms, timing, and the degree of overlap among these mechanisms of PV dysfunction are currently unclear, and PV thrombosis, fibrotic pannus ingrowth and prosthesis degeneration may, in fact, reflect a continuum of the same pathological process, with subclinical thrombus deposition occurring earlier and fibrotic organization occurring later in time (38).

PROSTHETIC HEART VALVE THROMBOSIS: CLINICAL PRESENTATION AND IMAGING

Certain degrees of thrombosis are commonly observed in patients with fibrotic pannus ingrowth, prosthesis degeneration, or prosthesis endocarditis (6). Patients with PV dysfunction with or without thrombosis may present with progressive dyspnea and signs of heart failure or systemic embolization. Alternatively, PV thrombosis may be an incidental finding at the time of echocardiographic follow-up (Figure 4) (3,5,6,30). PV dysfunction should be suspected in patients with symptoms of acute or subacute onset associated with an increase in transprosthetic gradient compared with the last echocardiographic follow-up (3,5,6,30). PV thrombosis may or may not be associated with subsequent TE. Although arterial TE after surgical or transcatheter heart valve replacement should be considered prosthesis-related until proven otherwise, it may also arise from left-sided aortic or mitral valve thrombus, bacterial leaflet vegetation, or from left atrial thrombus, particularly in patients with atrial fibrillation (AF) (6,31,39). Arterial TE manifests with signs and symptoms related to the arterial territory occluded by the embolism, including stroke or transient ischemic attack, acute peripheral ischemia, acute mesenteric ischemia, or acute ischemic kidney injury (11). Right-sided TE may arise from pulmonary or tricuspid valve thrombus or vegetation, and can cause pulmonary embolism or paradoxical systemic embolism in patients with septal defects, patent foramen ovale, or other right-to-left shunts. Similar clinical and imaging features characterize PV thrombosis after TAVR. In the report from Latib et al.



(22), PV thrombosis post-TAVR most commonly presented as progressive dyspnea with elevated transvalvular gradient and thickened leaflets or thrombotic apposition on the leaflets.

Regardless of the anatomic location of the prosthesis, the first-line imaging test for PV dysfunction is transthoracic echocardiography (6,11). Although transthoracic echocardiography is helpful for evaluating prosthetic valve hemodynamics and valve motion, the test is limited for morphological characterization of the etiology of PV dysfunction. Acoustic shadowing caused by the prosthesis may limit visualization of thrombus, vegetations, and pannus (6,11). Moreover, the diagnostic accuracy of transthoracic echocardiography is influenced by other factors, such as the presence of pericardial effusion, emphysema, obesity, or prior sternotomy (11). Therefore, after initial screening with transthoracic echocardiography, transesophageal echocardiography should be considered to better evaluate the pathological substrate of PV dysfunction. In particular, transesophageal echocardiography should always be performed if the transthoracic echocardiography is technically suboptimal, if the findings are not definitive, or if there is strong clinical suspicion of PV dysfunction. Transesophageal echocardiography is superior to transthoracic echocardiography for evaluating PV dysfunction, regardless of the valve type

TABLE 1 Pathological, Clinical, and Imaging Characteristics of Prosthetic Valve Thrombosis Versus Fibrotic Pannus Ingrowth

	PV Thrombosis	Fibrotic Pannus Ingrowth
Pathogenesis	Platelet aggregation and deposition, thrombin generation and clot formation	Thrombin generation and fibrin deposition Fibroblast proliferation, collagen deposition, and neoangiogenesis
Clinical features	Shorter time from valve replacement to valve dysfunction (weeks to months) Sudden onset of symptoms or subclinical More commonly associated with suboptimal anticoagulation	Longer time from valve replacement to valve dysfunction (months to years) Progressive onset of symptoms or subclinical Less commonly associated with suboptimal anticoagulation
Imaging	Higher total mass volume and area Higher lesion density More commonly located on the atrial side for mitral prostheses and on the aortic side for aortic prostheses Greater leaflet motion restriction	Lower total mass volume and area Lower lesion density More commonly located on the ventricular side for both mitral and aortic prostheses Less leaflet motion restriction

(MHV or BHV), but the diagnostic accuracy of transesophageal echocardiography over transthoracic echocardiography is greater with MHVs than with BHVs (11). Moreover, 3-dimensional transesophageal echocardiography can identify valve pannus overgrowth or vegetations (6,11). Vegetations due to PV endocarditis present as irregularly shaped mobile masses with low echogenicity. Like thrombi, vegetations tend to start in the valve ring area and then spread to the leaflets, leading to valve coaptation defects. It may be difficult to differentiate between vegetations and thrombosis on imaging, so both should be considered in the clinical context (such as the Duke clinical criteria for endocarditis, which are the diagnostic criteria of choice) (40).

Although transesophageal echocardiography is superior to transthoracic echocardiography for identifying the mechanism of PV degeneration, even transesophageal echocardiography cannot reliably discriminate between PV thrombosis and fibrotic pannus ingrowth (11). Instead, a combination of clinical and imaging criteria can be used to distinguish between these entities (Table 1); such distinction is important because their treatments differ. Lin et al. described 4 independent predictors of MHV thrombosis: increased transvalvular gradient (aortic $P_{max} \geq 50$ mm Hg, mitral $P_{mean} \geq 10$ mm Hg); presence of an occlusive mobile mass on the prosthetic valve; and an international normalized ratio (INR) ≤ 2.5 (12). Recently, Egbe et al. (8) compared the clinical and echocardiographic predictors of BHV thrombosis and BHV degeneration in 397 consecutive explanted bioprostheses. Five factors were independently associated with BHV thrombosis: 1) >50% increase in

mean echo-Doppler gradient from baseline within 5 years; 2) paroxysmal AF; 3) subtherapeutic INR; 4) increased valve cusp thickness; and 5) abnormal cusp mobility (8). The presence of all 5 risk factors was associated with a specificity of 93%, a positive predictive value of 85%, and a negative predictive value of 89%. This study underscores the importance of early post-operative echocardiography as a baseline for subsequent imaging and hemodynamic follow-up.

Although BHV thrombosis generally presents with PV degeneration, PV thrombosis may also be associated with new-onset regurgitation or mixed stenosis and regurgitation (11). In fact, in the report of Egbe et al. (8), 25 of 46 cases of BHV thrombosis (54%) presented with isolated stenosis, 5 (11%) with isolated regurgitation, and 15 cases (33%) presented with stenosis and regurgitation. However, prosthesis degeneration more commonly presents with significant regurgitation, together with reduced leaflet motion and leaflet calcification, generally without an increase in valve thickness.

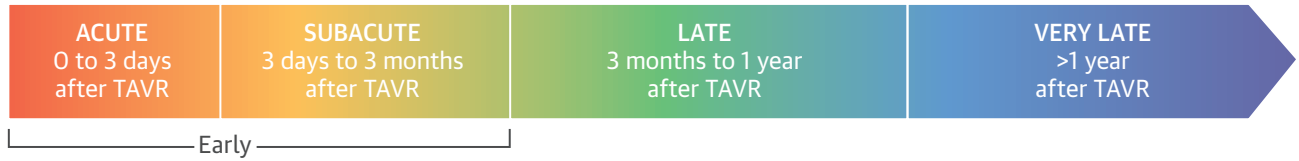
With MHVs, valve mobility can also be assessed using fluoroscopy, which permits accurate assessment of the prosthesis opening angles. However, fluoroscopy is not applicable to BHVs, as these are radiolucent (11).

In patients with inconclusive transthoracic and transesophageal echocardiography findings (which may be rather frequent), multidetector computed tomography could provide an accurate evaluation of the prosthetic valve structure and functional status (9,41). Electrocardiogram-gated multidetector computed tomography scanning enables dynamic leaflet evaluation, and anatomic assessment of the PV in systole and diastole (10,36). Multidetector computed tomography scanning can differentiate between PV thrombosis and fibrotic pannus ingrowth on the basis of Hounsfield units, with PV thrombosis having lower attenuation than fibrotic pannus ingrowth, and the latter having similar attenuation as the ventricular septum (10,36). Therefore, multidetector computed tomography scanning could be used to characterize the etiology of PV thrombosis, especially with BHVs, and to guide subsequent treatment. In several centers, multidetector computed tomography is the test of choice after the initial transthoracic echocardiography.

PV dysfunction should also be considered in the differential diagnosis of patient-prosthesis mismatch (11). Patient-prosthesis mismatch can be defined as a PV too small for the patient's body surface area. Although both PV dysfunction and patient-prosthesis mismatch may produce similar increases in

CENTRAL ILLUSTRATION Bioprosthetic Valve Thrombosis: Proposed Classification

Temporal Classification



Diagnostic Certainty Classification

Definite valve thrombosis	Probable valve thrombosis	Possible valve thrombosis
<p>Clinical criteria</p> <ul style="list-style-type: none"> Regression of new-onset heart failure symptoms after initiation of anticoagulation therapy <p>CTA criteria</p> <ul style="list-style-type: none"> Presence of reduced leaflet motion Presence of hypoattenuated leaflet thickening <p>Echocardiographic criteria</p> <ul style="list-style-type: none"> Direct visualization of valve thrombosis Regression of elevated mean gradient (<10 mm Hg) after oral anticoagulation therapy <p>Pathological criteria</p> <ul style="list-style-type: none"> Evidence of device thrombosis at autopsy or via examination of tissue retrieved during cardiac surgery 	<p>Clinical criteria</p> <ul style="list-style-type: none"> Acute- or subacute-onset heart failure symptoms (i.e., progressive dyspnea, peripheral edema, pulmonary rales, jugular turgor) <p>CTA criteria</p> <ul style="list-style-type: none"> Reduced leaflet motion No hypoattenuated leaflet thickening visible <p>Echocardiographic criteria</p> <ul style="list-style-type: none"> Increase in mean gradient >10 mm Hg No thrombus visible 	<p>Clinical criteria</p> <ul style="list-style-type: none"> Unexplained arterial thromboembolic event at any time after TAVR in patients without prior documented cardioembolic source without culprit epiaortic or carotid atherosclerosis
High diagnostic likelihood	Intermediate diagnostic likelihood	Low diagnostic likelihood

Dangas, G.D. et al. *J Am Coll Cardiol.* 2016;68(24):2670-89.

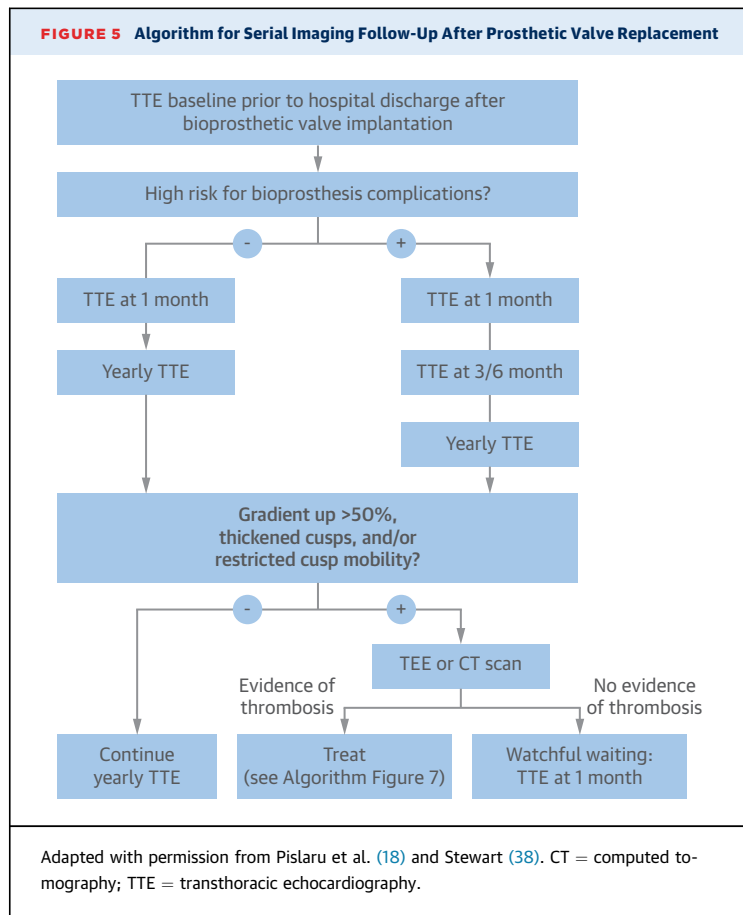
Valve thrombosis is a multifactorial phenomenon determined by the interplay of clinical, anatomic, procedural, and pharmacological factors. Valve thrombosis can be classified according to its timing as early (<3 months), late (3 months to 1 year), or very late (beyond 1 year). Definitive diagnosis of prosthesis thrombosis can be established with clinical, imaging (computed tomography or echocardiography), or pathological criteria. Pathological studies and observational registries suggest that the risk of prosthesis thrombosis and thromboembolism is highest in the first 3 months after implantation. Extension of anticoagulation therapy beyond 3 months requires balancing the risk of bleeding with the risk of thromboembolism. Longitudinal imaging follow-up may be beneficial in high-risk patients for valve dysfunction/thrombosis. CTA = computed tomography angiography; TAVR = transcatheter aortic valve replacement.

transvalvular gradients, evaluation of the effective orifice area is critical for characterization of patient-prosthesis mismatch. The combination of high transvalvular gradient, normal opening angles, and absence of masses on echocardiography supports the diagnosis of patient-prosthesis mismatch (9). Multi-detector computed tomography scanning may also help to differentiate between PV dysfunction and patient-prosthesis mismatch for 2 main reasons: 1) it will detect thrombus, vegetations, or other masses;

and 2) it provides a more accurate assessment of the geometry of the left ventricular outflow tract and the effective orifice area for prostheses implanted in the aortic position.

Finally, incorporating all of the available evidence, as described in the preceding text, we have attempted to introduce a clinical classification for bioprosthetic valve thrombosis (Central Illustration). First, a temporal classification should be applied, differentiating the timing of PV thrombosis into acute, subacute,

FIGURE 5 Algorithm for Serial Imaging Follow-Up After Prosthetic Valve Replacement



late, or very late. Then, depending on the degree of diagnostic certainty, PV thrombosis can be classified as definite (on the basis of clinical, imaging, and pathological or clinical response to initiation of anticoagulation therapy), probable (on the basis of clinical and imaging criteria), or possible (based only on uncertain clinical criteria).

ROUTINE IMAGING SURVEILLANCE. Because PV thrombosis with or without valve dysfunction is a potentially life-threatening complication, serial imaging surveillance is likely to be warranted. Transthoracic echocardiography should be the test of choice for routine screening. Current ACC/AHA guidelines endorse the use of echocardiographic imaging only in the presence of potential valve-related symptoms or annually, starting 10 years after valve implantation. We believe that such management may miss a significant proportion of early PV thrombosis or dysfunction, which mostly occurs in the first 2 years after valve implantation. Consequently, we suggest that baseline transthoracic or transesophageal echocardiograms should be done after valve implantation and before hospital discharge, and

1 to 3 months later (8,38). Annual follow-up is indicated thereafter, although patients at high risk for valve-related complications (such as those requiring a second valve implantation during TAVR or those with highly calcified or degenerated native valves) may benefit from more frequent evaluation (Figure 5). More frequent imaging may result in earlier detection of valve deterioration, with subsequent application of appropriate treatment (such as a trial of anticoagulation if thrombosis is suspected, or percutaneous intervention in the case of deterioration or other mechanical complications). In addition, the work of Egbe et al. (8) suggests that in certain cases, bioprosthetic valve thrombosis may represent an early stage of subclinical valve degeneration that is potentially treatable with a course of therapeutic anticoagulation. However, our suggestions in the preceding text are not currently supported by guideline recommendations, but on our current view of the pathophysiology of true disease; further studies may inform future practice guidelines on this subject.

PREVENTION AND TREATMENT OF PV THROMBOSIS AND THROMBOEMBOLIC EVENTS

GENERAL APPROACH. Three factors influence the intensity and duration of antithrombotic treatment after surgical or transcatheter valve interventions (2,24,25): 1) type of prosthesis; 2) thromboembolic risk; and 3) hemorrhage risk (42,43). The CHA₂DS₂-VASc (Table 2) scoring system may be helpful for evaluation of the risk of stroke. Although it was developed to predict TE events in patients with AF, the score has been validated in other clinical settings, including TAVR (44-46). Several scores have been developed to predict bleeding risk, including HAS-BLED, ATRIA, and HEMORR₂HAGES (Table 2) (47-49). Although these bleeding risk scores were developed in patients with AF on chronic oral anticoagulation with vitamin K antagonists (VKAs), due to the inclusion of common and well-known risk factors for bleeding, they might also be applicable to patients with valvular heart disease (with or without AF) (50); however, this hypothesis requires prospective confirmation.

For clarity, the antithrombotic treatments for prosthetic valve thrombosis and TE events after prosthetic heart valve replacement can be broadly categorized according to their mechanisms of action as antiplatelet-based strategies (aspirin and/or a P2Y₁₂ receptor inhibitor) and anticoagulant-based strategies (using VKAs or direct oral anticoagulants). Due to greater familiarity across all specialties involved and bleeding risk concerns in this

TABLE 2 Risk Scores for Thromboembolic and Bleeding Risk Stratification

Thromboembolic Risk	Score
CHA₂DS₂-VASc	
Congestive heart failure	1
Hypertension	1
Age ≥75 yrs	2
Diabetes mellitus	1
Previous cerebrovascular embolization*	2
Vascular disease†	1
Aged 65 to 74 yrs	1
Female sex	1
Total	9
Bleeding Risk	
HAS-BLED	
Hypertension	1
Abnormal renal and liver function (1 point each)	1 or 2
Previous cerebrovascular embolization	1
Bleeding diathesis	1
Labile INR values (on warfarin)	1
Age >65 yrs	1
Drugs or alcohol abuse (1 point each)	1 or 2
Total	9
ATRIA	
Anemia	3
Severe renal disease (eGFR <45 ml/min)	3
Age ≥75 yrs	2
Prior bleeding	1
Hypertension	1
Total	10
HEMORR₂HAGES	
Hepatic or renal disease	1
Ethanol abuse	1
Malignancy	1
Older age	1
Reduced platelet count or function	1
Prior hemorrhage	2
Hypertension	1
Anemia	1
Genetic factors (CYP 2C9 single-nucleotide polymorphisms)	1
Excessive fall risk	1
Stroke	1
Total	12
*Including stroke or transient ischemic attack. †Including prior myocardial infarction, peripheral artery disease, or aortic plaque. CYP = cytochrome P450; eGFR = estimated glomerular filtration rate; INR = international normalized ratio.	

SURGICAL PROSTHESIS. With MHVs, VKAs are the mainstay for prevention of PV thrombosis. VKAs are dose-adjusted to maintain INRs of 2 to 3 and 2.5 to 3.5 for MHVs implanted in the aortic and mitral positions, respectively (2,24,25). With BHVs, anticoagulation with VKAs is generally recommended for the first 3 months after the procedure, with INRs between 2.0 and 3.0, irrespective of the prosthesis position (aortic, mitral, or right-sided) (2,24,25). After bioprosthetic valve replacement, use of anticoagulation is predicated on the need to reduce the risk of thromboembolic complications while the prosthesis undergoes endothelialization. In a large study from the Society of Thoracic Surgeons (STS) Adult Cardiac Surgery Database, Brennan et al. (51) demonstrated reduced adjusted risk of death (relative risk [RR]: 0.80; 95% confidence interval [CI]: 0.66 to 0.96) and thromboembolic events (RR: 0.52; 95% CI: 0.35 to 0.76) with the use of warfarin plus aspirin compared with aspirin alone in 25,656 patients ≥65 years of age undergoing surgical aortic valve replacement with a bioprosthesis. However, the risk of bleeding was increased with the combination of aspirin plus warfarin compared with aspirin alone (RR: 2.80; 95% CI: 2.18 to 3.60). Of note, there were no differences in the rates of mortality, thromboembolic complications, or bleeding between patients on aspirin alone versus warfarin alone, suggesting that combined attenuation of platelets and coagulation is more effective. Mérie et al. (52) reported similar findings in aortic BHV replacement; compared with aspirin, warfarin was associated with a significantly lower risk of TE, stroke, and cardiovascular death in the first 3 months. Moreover, discontinuation of warfarin between 3 and 6 months was associated with an increase in thromboembolic complications. However, the optimal duration and intensity of VKA therapy after surgical BHV replacement have never been evaluated in prospective, randomized controlled trials, and most of the available evidence stems from large registry studies, with their inherent limitations. On the basis of current evidence, extending anticoagulation beyond 3 months after BHV replacement may be appropriate in patients deemed at high risk for TE (i.e., concomitant AF, history of thromboembolic disease, hypercoagulability, or severe left ventricular dysfunction) and at moderate to low risk for bleeding. In this setting, periodic imaging follow-up can help identify patients with early signs of BHV deterioration who may benefit from more intensified short- or long-term antithrombotic regimens.

The type of BHV may potentially influence the choice of antithrombotic regimen. In a meta-analysis

population, clopidogrel has been the most utilized P2Y₁₂ inhibitor in trials, registries, and clinical practice thus far. Current guidelines for antithrombotic therapy after surgical or transcatheter valve replacement are outlined in Table 3. Antithrombotic strategies according the type of heart valve prosthesis and intervention type are discussed in the following sections.

TABLE 3 ACC/AHA, ACCP, and ESC Recommendations for Antithrombotic Therapy After Valve Replacement

	ACC/AHA	ACCP	ESC
Surgical MHV replacement	Anticoagulation with VKA (INR of 2.5 for AVR and no risk factors for TE; INR of 3.0 for AVR with risk factors for TE or MVR) plus aspirin 75-100 mg daily (Class I)	VKA (INR of 2.5 for AVR and 3.0 for MVR) indicated over no VKA for long-term management (Grade 1B) Aspirin 50-100 mg indicated in patients at low risk of bleeding (Grade 1B)	Anticoagulation with VKA (target INR according to prosthesis thrombogenicity and patient-related risk factors [Table 1]; Class I) Aspirin \leq 100 mg daily if concomitant atherosclerotic disease and/or TE despite adequate INR (Class IIa)
Surgical BHV replacement	Anticoagulation with VKA (INR of 2.5) plus aspirin 75-100 mg for the first 3 months followed by aspirin 75-100 mg daily alone (Class IIa/IIb)	Aspirin 50-100 mg indicated in the first 3 months (Grade 2C) Aspirin 50-100 mg is indicated over VKA and over no APT for the first 3 months after AVR in patients in sinus rhythm (Grade 2C) VKA (INR: 2.5) indicated over no VKA for the first 3 months after MVR (Grade 2C)	Anticoagulation with VKA for the first 3 months after MVR, MVRep, or TVR (Class IIa) Anticoagulation with VKA for the first 3 months after AVR (Class IIb) Aspirin \leq 100 mg daily for the first 3 months after AVR (Class IIa)
TAVR	Clopidogrel 75 mg plus aspirin 75-100 mg for 6 months followed by aspirin 75-100 mg daily alone (Class IIb)	Aspirin 50-100 mg plus clopidogrel 75 mg/dl is indicated over VKA and over no APT for the first 3 months (Grade 2C)	No specific recommendations

ACC = American College of Cardiology; ACCP = American College of Chest Physicians; AHA = American Heart Association; APT = antiplatelet therapy; AVR = aortic valve replacement; BHV = bioprosthetic heart valve; ESC = European Society of Cardiology; INR = international normalized ratio; MHV = mechanical heart valve; MVR = mitral valve replacement; MVRep = mitral valve repair; TAVR = transcatheter aortic valve replacement; TE = thromboembolism; TVR = target vessel revascularization; VKA = vitamin K antagonist.

of randomized and nonrandomized studies, stentless BHVs were associated with a lower risk of prosthesis-patient mismatch, greater effective orifice areas, and lower transvalvular gradients at follow-up compared with stented BHVs (53). Although the improved hemodynamic characteristics of stentless valves may imply a reduced risk of thrombosis, and therefore, avoidance of more intensive antithrombotic regimens, adequately powered randomized trials testing these concepts have yet to be performed.

Use of non-vitamin K oral anticoagulants in surgical prosthesis. The efficacy and safety of dabigatran for stroke prevention in AF prompted its comparison with warfarin in patients with MHVs in the RE-ALIGN (Randomized, Phase II Study to Evaluate the Safety and Pharmacokinetics of Oral Dabigatran Etxilate in Patients after Heart Valve Replacement) study. The study was stopped early because of a trend for more ischemic strokes in patients randomized to dabigatran (54). The negative results of this study prompted black-box warnings against the use of dabigatran and other direct oral anticoagulants in patients with MHVs. Consequently, despite their limitations, VKAs remain the sole option for anticoagulation in patients with MHVs.

Several mechanistic observations help to rationalize the findings of the RE-ALIGN trial. First, what triggers thrombosis on MHVs and why did dabigatran fail for this indication? Blood-contacting medical devices, such as MHVs and catheters, activate the contact system and trigger clotting via the intrinsic pathway: a pathway initiated by contact activation of fXII, propagated by fXIIa-mediated activation of fXI, and culminating in thrombin generation (55). Catheters promote clotting via the intrinsic pathway

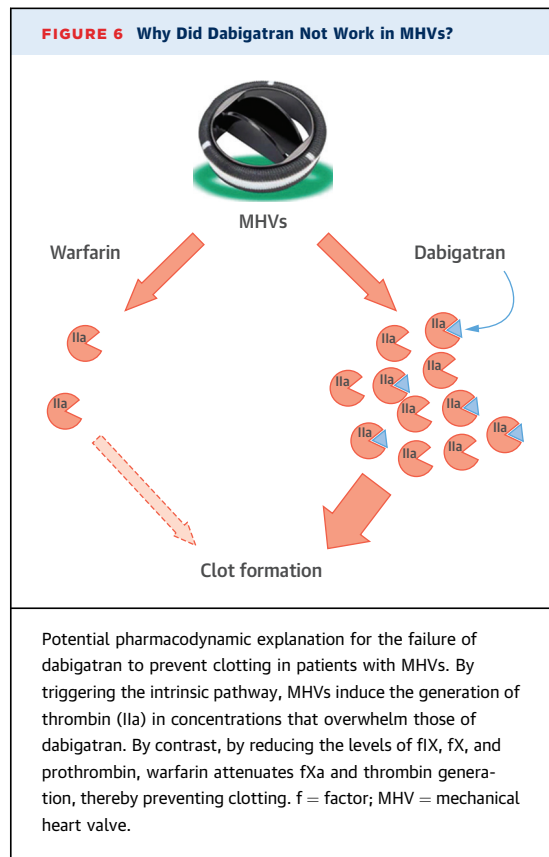
because: 1) they bind and activate fXII, and induce fXI activation; 2) corn trypsin inhibitor, a potent inhibitor of fXIIa, blocks catheter-induced clotting; 3) catheter-induced clotting is attenuated in fXII- or fXI-deficient plasma, key components of the intrinsic pathway, but not in plasma deficient in fVII, which is essential for the extrinsic pathway; and 4) knockdown of fXII or fXI with antisense oligonucleotides prolongs the time to catheter thrombosis in rabbits, whereas fVII knockdown has no effect (56-58). Like the findings with catheters, valve leaflets and sewing ring segments from MHVs promote clotting via the intrinsic pathway because thrombin generation is: 1) attenuated with corn trypsin inhibitor; and 2) reduced in fXII-deficient plasma, eliminated in fXI-deficient plasma, and unchanged in fVII-deficient plasma (59). Therefore, like catheters, MHVs trigger clotting via the intrinsic pathway.

Dacron and Teflon sewing ring segments are more thrombogenic than valve leaflets (60). This finding explains why valve thrombosis starts on the sewing ring in pigs with implanted MHV. It could also explain the apparent benefit of short-term anticoagulation in patients with newly implanted PVs. Thus, a 3- to 6-month course of warfarin anticoagulation in such patients may prevent thrombus formation on the sewing ring while endothelialization occurs.

Why was dabigatran less effective than warfarin at blocking clotting on MHVs? By triggering the intrinsic pathway, MHVs induce the local generation of thrombin in concentrations that exceed those of dabigatran, which inhibits thrombin in a 1:1 manner. By contrast, minimal thrombin is generated in the presence of warfarin because, by reducing the functional levels of fIX, fX, and fII, warfarin attenuates

fXa and thrombin generation via the intrinsic and common pathways, respectively (Figure 6). Supporting the limited capacity of dabigatran to block medical device-induced clotting, dabigatran prevented catheter thrombosis in rabbits at concentrations similar to those found at peak in patients given 150 mg twice daily, but not at trough concentrations (61). The same appears to be true for MHVs because dabigatran had minimal effects on thrombin generation induced by MHVs at concentrations below 200 ng/ml (59). By contrast, thrombin generation was attenuated in plasma from warfarin-treated patients with an INR over 1.5. These findings provide a rational explanation for the trend for more strokes with dabigatran than with warfarin in patients with MHVs in the RE-ALIGN trial (54). Dose-equivalency plots constructed by comparing the effects of varying doses of dabigatran and warfarin on thrombin generation induced by MHVs revealed that dabigatran concentrations of 254 and 488 ng/ml are required to suppress endogenous thrombin potential, a global measure of thrombin generation, to the same extent as warfarin at INR values of 2 and 3.5, respectively (59). Using this information, pharmacokinetic modeling suggests that twice-daily dabigatran doses of 620 mg would be required to maintain the trough concentration at or above 250 ng/ml. This is more than double the twice-daily 300-mg maximum dabigatran dose used in the RE-ALIGN trial, a dose that already produced more bleeding than warfarin. Therefore, it is unlikely that clotting on MHVs can be suppressed with clinically relevant dabigatran doses (54). Oral inhibitors of fXa may be better than dabigatran for preventing thrombosis on MHVs and PVs because they attenuate thrombin generation. Such upstream inhibition at the level of fXa is beneficial because each molecule of fXa generates 1,000 molecules of thrombin. Although rivaroxaban, apixaban, and edoxaban have yet to be evaluated in patients with MHVs, rivaroxaban was more effective than enoxaparin at preventing MHV thrombosis in a pig model (62). Therefore, future studies should evaluate the efficacy of the oral fXa inhibitors for prevention of clotting on MHVs.

TRANSCATHETER PROSTHESIS. In agreement with findings with surgically implanted BHVs, the risk for thromboembolic complications after TAVR is highest in the first 3 months after valve implantation (23). This period coincides with the time required for neointimal coverage of the frame and leaflets. Currently, DAPT with aspirin (80 mg to 325 mg daily) and clopidogrel (75 mg daily) is the most commonly used antithrombotic regimen, and treatment is given for 1 to 6 months (2). The selection of this regimen is on the



basis of expert consensus; there are no relevant randomized controlled trials. In the PARTNER trial, life-long aspirin (75 mg to 100 mg per day) and clopidogrel (75 mg per day) for 6 months were recommended. The ACC/American Association for Thoracic Surgery/Society for Cardiac Angiography and Interventions/STS panel recommends DAPT with aspirin and clopidogrel to reduce the risk of thromboembolic events after TAVR, but the optimal duration of such treatment is not specified (2). Similarly, guidelines from the European Society of Cardiology recommend DAPT with low-dose aspirin and a thienopyridine, but do not specify the duration. Conversely, the Canadian Cardiovascular Society statement on transcatheter aortic valve implantation recommends the use of aspirin indefinitely and clopidogrel for 1 to 3 months (25,63). Because it is unclear whether thrombi formed during and after TAVR are predominantly composed of platelets and fibrin, an antiplatelet-based strategy alone may not provide optimal prevention in this subset of patients. Van Mieghem et al. (64) reported that more than one-half of the cerebral emboli that occur during TAVR are platelet-fibrin thrombi, with the remainder reflecting calcified debris. The recent observations that subclinical leaflet thrombosis can

occur soon after TAVR, and is less common in patients receiving oral anticoagulants than in those given DAPT, suggest that antiplatelet therapy alone may be insufficient to prevent TE complications in all patients. In a collaborative, patient-level pooled analysis of all available studies (both randomized and non-randomized) comparing aspirin with DAPT, Hassell et al. (65) found no differences in all-cause mortality, stroke, and net adverse clinical events at 30 days. However, this study has several limitations, including the relatively low statistical power, the inclusion of randomized and nonrandomized studies, and the short duration of follow-up. Although more potent adenosine diphosphate receptor antagonists, such as ticagrelor or prasugrel, may be superior to clopidogrel, they have yet to be evaluated for this indication, and their safety profile is unknown in the often-frail TAVR population. Additionally, long-term oral anticoagulation may be associated with an unfavorable risk/benefit ratio in the frail TAVR population compared with an antiplatelet-based strategy with DAPT or single-antiplatelet therapy with aspirin, prasugrel, or ticagrelor.

First, without a sewing ring and much less mechanical prosthetic surface, TAVR devices are less thrombogenic than MHVs. The absence of a sewing ring is an advantage over surgically implanted BHVs, although the latter do not have the exposed metallic stent-based support structure of the TAVR devices. The sewing ring also limits the actual orifice area of the prosthesis, and its absence may further explain the lower risk of patient-prosthesis mismatch and the better hemodynamic performance of transcatheter bioprosthetic valves compared with stentless or stented surgical bioprostheses (66). These differences may translate to a lower need for intensified antithrombotic regimens to prevent valve-related thromboembolic complications.

The intraprocedural safety and efficacy of heparin versus bivalirudin, a parenteral direct thrombin inhibitor, were compared in the BRAVO 2/3 (Effect of Bivalirudin on Aortic Valve Intervention Outcomes 2/3) trial. There were no differences in ischemic and bleeding events at 48 h and 30 days in patients undergoing TAVR (67), including in rates of cerebral embolization assessed with magnetic resonance imaging (68). However, the safety and efficacy of anticoagulant-based strategies in preventing TE complications mid- to long-term after TAVR have yet to be evaluated. To address this, the GALILEO (Global Study Comparing a rivAroxaban-based Antithrombotic Strategy to an antiPlatelet-based Strategy After Transcatheter aortic valve replacement to Optimize Clinical Outcomes) trial (NCT02556203) will

compare low-dose rivaroxaban with antiplatelet therapy in patients without an established indication for long term oral anticoagulation (69), whereas the ATLANTIS (Anti-Thrombotic Strategy After Trans-Aortic Valve Implantation for Aortic Stenosis) trial (NCT02664649) will compare apixaban with standard-of-care antithrombotic therapy in 1,509 patients undergoing successful TAVR with or without indications for long-term anticoagulation (70). Another clinical trial, the ENVISAGE-TAVI AF (EdoxabaN Versus standard of care and theIr effectS on clinical outcomes in pAtients havinG undergonE Transcatheter Aortic Valve Implantation [TAVI] – Atrial Fibrillation) underway will compare edoxaban to warfarin in patients with oral anticoagulation indication after TAVR [NCT02943785]. Finally, the value (benefit-risk ratio) of adding clopidogrel to aspirin or to an anticoagulant has not been tested in any way yet and is not part of any of these 3 trials.

The rapid onset of action of the novel oral anticoagulants and their reduced bleeding risk compared with VKAs render them attractive options. Although dabigatran was less effective than warfarin in reducing the risk of thromboembolic events in patients with MHVs in the RE-ALIGN trial, these findings may not apply to the transcatheter BHV population (54). First, without a sewing ring, TAVR devices are less thrombogenic than MHVs and surgically implanted BHVs. Secondly, the RE-ALIGN trial enrolled patients who underwent surgical valve replacement, which is associated with a greater inflammatory response, and possibly enhanced platelet activation and thrombogenicity compared with TAVR. Nonetheless, microthrombi can form on the valve leaflets and may compromise valve function. Oral fXa inhibitors may be superior to VKAs for preventing this problem because they produce a more rapid and predictable anticoagulant response, and because the oral fXa inhibitors can be given in prophylactic or treatment doses. By contrast, to be effective, warfarin must be dose-adjusted to an INR of 2 or higher, which increases the risk of bleeding. Additionally, the implementation of short- (\approx 3 months) or even mid-term ($>$ 3 months) anticoagulation after TAVR should not only prevent leaflet thrombosis, but would attenuate thrombotic complications secondary to AF. This is important, considering the high prevalence of baseline AF (25% to 30%), new onset permanent AF (15% to 20%), and paroxysmal AF. The range of potential antithrombotic therapies for PVT and TE prevention is listed in Table 4.

Transcatheter mitral valve replacement is emerging as a new therapeutic modality for the treatment of severe mitral valve regurgitation. In late

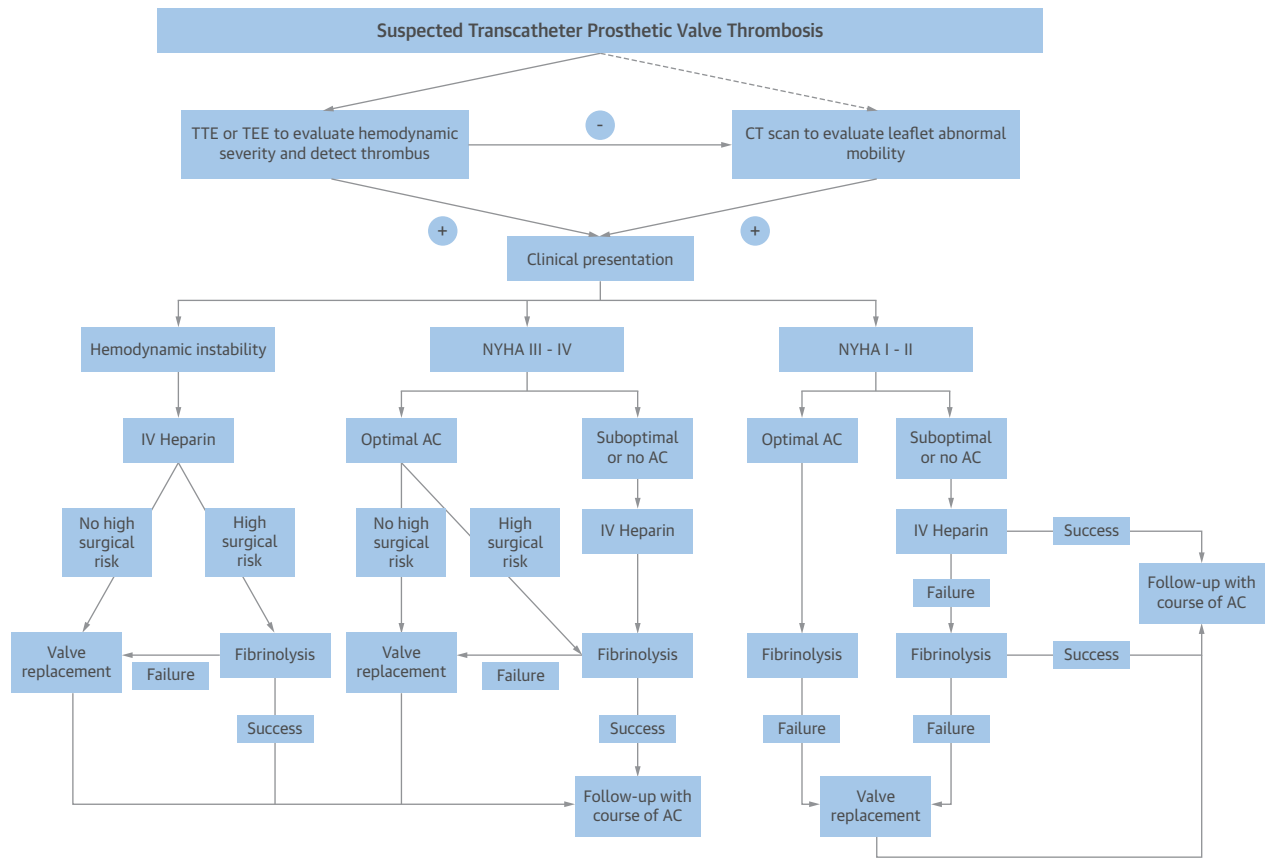
TABLE 4 Potentially Useful Antithrombotic Agents After Transcatheter Valve Replacement

	Pharmacokinetics	Pharmacodynamics	Clinical Indication	Potential Advantages	Potential Disadvantages
Antiplatelet agents					
Aspirin	Direct-acting Action onset ≈1-3 h Action offset ≈7-10 days	Irreversible COX-1 inhibitor	Indicated for primary and secondary prevention of atherothrombotic disease (stroke, stable CAD, post-ACS, peripheral vascular disease)	Inexpensive, effective, and well-tolerated	GI bleeding risk
Clopidogrel	Prodrug (CYP-450 metabolism) Action onset ≈2-8 h Action offset ≈7-10 days	Irreversible P2Y ₁₂ -inhibitor	Indicated for primary and secondary prevention of atherothrombotic disease (stroke, stable CAD, post-ACS, peripheral artery disease)	Inexpensive, extensive clinical data evaluating safety and efficacy	Inconsistent platelet inhibition Bleeding risk
Ticagrelor	Direct-acting Action onset ≈0.5-2 h Action offset ≈3-5 days	Reversible P2Y ₁₂ -inhibitor	Indicated for secondary prevention after ACS, and secondary prevention in patients with history of MI	More consistent and potent platelet inhibition	Currently only available as brand Higher bleeding risk May cause dyspnea
Prasugrel	Prodrug (CYP-450 metabolism) Action onset ≈0.5-4 h Action offset ≈7-10 days	Irreversible P2Y ₁₂ -inhibitor	Indicated for secondary prevention after ACS	More consistent and potent platelet inhibition	Currently only available as brand Higher bleeding risk Contraindicated if age >75 yrs, weight <60 kg, or history of stroke
Anticoagulant agents					
Warfarin	Action onset ≈3-4 days	Vitamin K antagonist	Reduction of risk of stroke and systemic embolism in surgical Reduction of risk of stroke and systemic embolism in AF Prophylaxis of DVT after hip or knee surgery Treatment and prophylaxis of DVT and PE	Reversal agents available	High interindividual variability Higher bleeding risk Dietary restrictions INR monitoring Many drug interactions
Apixaban	Rapid action onset	Factor Xa inhibitor	Reduction of risk of stroke and systemic embolism in AF Thromboprophylaxis after hip or knee arthroplasty Treatment of DVT and PE	Lower bleeding risk and higher antithrombotic efficacy Monitoring not required	No reversal agents available
Rivaroxaban	Rapid action onset	Factor Xa inhibitor	Reduction of risk of stroke and systemic embolism in AF Thromboprophylaxis after hip or knee arthroplasty Treatment of DVT and PE	Lower bleeding risk Monitoring not required	No reversal agents available
Edoxaban	Rapid action onset	Factor Xa inhibitor	Reduction of risk of stroke and systemic embolism in AF Treatment of DVT and PE	Lower bleeding risk Monitoring not required	No reversal agents available
Dabigatran	Prodrug Rapid action onset	Thrombin inhibitor	Reduction of risk of stroke and systemic embolism in AF Treatment and prophylaxis of DVT and PE	Lower bleeding risk Monitoring not required Reversal agent available	Results from the RE-ALIGN trial
<p>ACS = acute coronary syndrome; AF = atrial fibrillation; CAD = coronary artery disease; DVT = deep vein thrombosis; GI = gastrointestinal; INR = international normalized ratio; MI = myocardial infarction; PE = pulmonary embolism; RE-ALIGN = Randomized, Phase II Study to Evaluate the Safety and Pharmacokinetics of Oral Dabigatran Etexilate in Patients after Heart Valve Replacement.</p>					

2014, Cheung et al. (71) reported the first cases of human implantation of the TIARA device (Neovasc, Richmond, British Columbia, Canada) via a transapical approach in 2 patients deemed at extreme risk for surgery (72). Treatment of mitral valve diseases involves different challenges, including highly heterogeneous pathological substrate, reduced left ventricular function, concomitant AF, technical feasibility interaction with surrounding structures, more severe course of paravalvular leak, and higher thromboembolic risk (71,72). Surgical studies suggest

that mitral valve replacement is associated with a higher risk of thromboembolic complications than aortic valve replacement with both mechanical valves and bioprostheses, despite adequate levels of anticoagulation (53). Moreover, BPVs implanted in the mitral position are prone to earlier structural deterioration than BPVs in the aortic position (53). Therefore, adequate thromboprophylaxis is of particular importance in patients with mitral valves (target INR 3.5 on warfarin). The relative efficacy and safety of transcatheter MVR versus surgical MVR, surgical or

FIGURE 7 Management of Transcatheter Bioprosthetic Valve Thrombosis



Transthoracic or transesophageal echocardiography (TEE) should be the first-line imaging tool in patients with suspected PV thrombosis. If echocardiography is negative, cardiac CT to assess leaflet anatomy and motility should be considered. The severity of clinical presentation may guide treatment options. In patients in whom conservative measures (i.e., instauration of therapeutic anticoagulation [AC] or fibrinolysis in patients already on therapeutic AC) fail, repeat valve replacement should be considered. Following PV thrombosis resolution, patients should be discharged on a regimen of AC. IV = intravenous; NYHA = New York Heart Association functional class; other abbreviations as in [Figure 5](#).

percutaneous MV repair, and optimal medical therapy are unknown, but future studies should take into account the higher risk of TE of BPVs in the mitral position and the potential need for intensified combination antithrombotic regimens in certain patients.

MANAGEMENT OF PV OBSTRUCTION WITH OR WITHOUT THROMBOSIS: AN INTEGRATED APPROACH

PV dysfunction is a life-threatening condition and prompt treatment is mandatory. Determination of the etiology of the PV dysfunction is the first step in defining subsequent treatment. Treatment options for PV thrombosis include surgery, thrombolytic therapy, and anticoagulation. The 2014 ACC/AHA guidelines recommend thrombolytic therapy for

right-sided PV thrombosis if clots persist despite intravenous heparin (2). The approach to left-sided PV thrombosis treatment involves clinical and imaging evaluation of the thrombus burden. In patients presenting with hemodynamic instability, a regimen of intravenous heparin should be started as soon as possible, followed by either thrombolysis (if prohibitive surgical risk) or surgery (if acceptable surgical risk). Emergency surgery is recommended for patients with New York Heart Association (NYHA) functional class III to IV status and/or a large thrombus (thrombus area ≥ 0.8 cm²). Heparin is recommended as the initial approach for patients with NYHA functional class I to II status and/or a small thrombus (<0.8 cm²); thrombolytic therapy is recommended if the valve thrombosis persists. Following thrombus resolution and restoration of normal hemodynamics, a

regimen of long-term oral anticoagulation could be started to prevent recurrent valve thrombosis. Current guidelines can be adapted to obstructive transcatheter BHV thrombosis, as illustrated in **Figure 7**. PV thrombosis and fibrotic pannus ingrowth may be both present. Therefore, once there is improvement in the valve hemodynamics and/or valve motion, serial follow-up is important because residual thrombus may promote recurrent thrombosis. Early detection and treatment of thrombus formation on BHVs may lead to a short-term reduction in the risk of TE events and long-term prevention of PV degeneration; however, this hypothesis requires testing in prospective, randomized studies.

CONCLUSIONS

Although there is a body of evidence supporting the use of VKAs for thromboprophylaxis in patients with MHVs, the optimal antithrombotic regimen for PVs is uncertain. Pathological studies and observational registries indicate that the risk of valve thrombosis and TE events is highest in the first 3 months after surgical implantation of PVs, suggesting that anticoagulant thromboprophylaxis in this time frame may be beneficial. Extension of anticoagulation therapy

beyond 3 months requires balancing the risk of bleeding with the risk TE (43). The risk of TE is influenced by the CHA₂DS₂-VASc score, the position of the valve, and other risk factors, such as subclinical valve thrombosis, new-onset of paroxysmal or persistent AF, and device-related factors that may influence long-term thrombogenicity (valve positioning, traumatic leaflet post-dilation, or incomplete metallic strut apposition). Although several ongoing randomized controlled trials are evaluating various antithrombotic strategies, until these data are available, the choice of the appropriate antithrombotic regimen, outside of MVR, should be dynamic and on the basis of a careful evaluation of the ongoing individual thromboembolic and hemorrhagic risk. With the increasing use of transcatheter valvular therapies, defining the optimal antithrombotic regimen is of paramount importance.

REPRINT REQUESTS AND CORRESPONDENCE: Dr. George D. Dangas, The Zena and Michael A. Wiener Cardiovascular Institute, Icahn School of Medicine at Mount Sinai, One Gustave L. Levy Place, Box 1030, New York, New York 10029. E-mail: george.dangas@mountsinai.org OR gdangas@crf.org.

REFERENCES

1. Jung B, Vahanian A. Epidemiology of valvular heart disease in the adult. *Nat Rev Cardiol* 2011;8:162-72.
2. Nishimura RA, Otto CM, Bonow RO, et al. 2014 AHA/ACC guideline for the management of patients with valvular heart disease: a report of the American College of Cardiology/American Heart Association Task Force on Practice Guidelines [Published correction appears in *J Am Coll Cardiol* 2014;63:2489]. *J Am Coll Cardiol* 2014;63:e57-185.
3. Sun JC, Davidson MJ, Lamy A, et al. Antithrombotic management of patients with prosthetic heart valves: current evidence and future trends. *Lancet* 2009;374:565-76.
4. Taramasso M, Pozzoli A, Latib A, et al. New devices for TAVI: technologies and initial clinical experiences. *Nat Rev Cardiol* 2014;11:157-67.
5. Roudaut R, Serri K, Lafitte S. Thrombosis of prosthetic heart valves: diagnosis and therapeutic considerations. *Heart* 2007;93:137-42.
6. Zoghbi WA, Chambers JB, Dumesnil JG, et al. Recommendations for evaluation of prosthetic valves with echocardiography and Doppler ultrasound. *J Am Soc Echocardiogr* 2009;22:975-1014.
7. Deviri E, Sareli P, Wisenbaugh T, et al. Obstruction of mechanical heart valve prostheses: clinical aspects and surgical management. *J Am Coll Cardiol* 1991;17:646-50.
8. Egbe AC, Pislaru SV, Pelliikka PA, et al. Bioprosthetic valve thrombosis versus structural failure: clinical and echocardiographic predictors. *J Am Coll Cardiol* 2015;66:2285-94.
9. Makkar RR, Fontana G, Jilaihawi H, et al. Possible subclinical leaflet thrombosis in bioprosthetic aortic valves. *N Engl J Med* 2015;373:2015-24.
10. Pache G, Schoechlin S, Blanke P, et al. Early hypo-attenuated leaflet thickening in balloon-expandable transcatheter aortic heart valves. *Eur Heart J* 2016;37:2263-71.
11. Habets J, Budde RP, Symersky P, et al. Diagnostic evaluation of left-sided prosthetic heart valve dysfunction. *Nat Rev Cardiol* 2011;8:466-78.
12. Lin SS, Tiong IY, Asher CR, et al. Prediction of thrombus-related mechanical prosthetic valve dysfunction using transesophageal echocardiography. *J Am Coll Cardiol* 2000;86:1097-101.
13. Laplace G, Lafitte S, Labèque JN, et al. Clinical significance of early thrombosis after prosthetic mitral valve replacement: a postoperative monocentric study of 680 patients. *J Am Coll Cardiol* 2004;43:1283-90.
14. Puvimanasinghe JP, Steyerberg EW, Takkenberg JJ, et al. Prognosis after aortic valve replacement with a bioprosthesis: predictions based on meta-analysis and microsimulation. *Circulation* 2001;103:1535-41.
15. Brown ML, Park SJ, Sundt TM, et al. Early thrombosis risk in patients with biologic valves in the aortic position. *J Thorac Cardiovasc Surg* 2012;144:108-11.
16. Heras M, Chesebro JH, Fuster V, et al. High risk of thromboemboli early after bioprosthetic cardiac valve replacement. *J Am Coll Cardiol* 1995;25:1111-9.
17. Le Tourneau T, Lim V, Inamo J, et al. Achieved anticoagulation vs prosthesis selection for mitral mechanical valve replacement: a population-based outcome study. *Chest* 2009;136:1503-13.
18. Pislaru SV, Hussain I, Pelliikka PA, et al. Misconceptions, diagnostic challenges and treatment opportunities in bioprosthetic valve thrombosis: lessons from a case series. *Eur J Cardiothorac Surg* 2015;47:725-32.
19. Kapadia SR, Leon MB, Makkar RR, et al., PARTNER trial investigators. 5-Year outcomes of transcatheter aortic valve replacement compared with standard treatment for patients with inoperable aortic stenosis (PARTNER 1): a randomised controlled trial. *Lancet* 2015;385:2485-91.
20. Mack MJ, Leon MB, Smith CR, et al., PARTNER 1 trial investigators. 5-Year outcomes of transcatheter aortic valve replacement or surgical aortic valve replacement for high surgical risk patients with aortic stenosis (PARTNER 1): a randomised controlled trial. *Lancet* 2015;385:2477-84.

21. Reardon MJ, Adams DH, Kleiman NS, et al. 2-year outcomes in patients undergoing surgical or self-expanding transcatheter aortic valve replacement. *J Am Coll Cardiol* 2015;66:113-21.
22. Latib A, Naganuma T, Abdel-Wahab M, et al. Treatment and clinical outcomes of transcatheter heart valve thrombosis. *Circ Cardiovasc Interv* 2015;8:e001779.
23. Stortecky S, Windecker S. Stroke: an infrequent but devastating complication in cardiovascular interventions. *Circulation* 2012;126:2921-4.
24. Whitlock RP, Sun JC, Frenes SE, et al. Antithrombotic and thrombolytic therapy for valvular disease: Antithrombotic Therapy and Prevention of Thrombosis, 9th ed: American College of Chest Physicians Evidence-Based Clinical Practice Guidelines. *Chest* 2012;141:e576S-600.
25. Vahanian A, Alferi O, Andreotti F, et al. Guidelines on the management of valvular heart disease (version 2012). *Eur Heart J* 2012;33:2451-96.
26. Leetmaa T, Hansson NC, Leipsic J, et al. Early aortic transcatheter heart valve thrombosis: diagnostic value of contrast-enhanced multidetector computed tomography. *Circ Cardiovasc Interv* 2015;8:e001596.
27. Hansson NC, Grove EL, Andersen HR, et al. Transcatheter aortic heart valve thrombosis: incidence, predisposing factors, and clinical implications. *J Am Coll Cardiol* 2016;68:2059-69.
28. Wolberg AS, Aleman MM, Leiderman K, et al. Procoagulant activity in hemostasis and thrombosis: Virchow's triad revisited. *Anesth Analg* 2012;114:275-85.
29. Turbill P, Beugeling T, Poot AA. Proteins involved in the Vroman effect during exposure of human blood plasma to glass and polyethylene. *Biomaterials* 1996;17:1279-87.
30. Noble S, Asgar A, Cartier R, et al. Anatomopathological analysis after CoreValve Revalving system implantation. *EuroIntervention* 2009;5:78-85.
31. Luszczyk J, Undas A, Gissel M, et al. Activated factor XI and tissue factor in aortic stenosis: links with thrombin generation. *Blood Coagul Fibrinolysis* 2011;22:473-9.
32. Seiler C. Management and follow up of prosthetic heart valves. *Heart* 2004;90:818-24.
33. Freudenberger RS, Hellkamp AS, Halperin JL, et al. Risk of thromboembolism in heart failure: an analysis from the Sudden Cardiac Death in Heart Failure Trial (SCD-HeFT). *Circulation* 2007;115:2637-41.
34. Mylotte D, Andalib A, Thériault-Lauzier P, et al. Transcatheter heart valve failure: a systematic review. *Eur Heart J* 2015;36:1306-27.
35. Leiria TL, Lopes RD, Williams JB, et al. Antithrombotic therapies in patients with prosthetic heart valves: guidelines translated for the clinician. *J Thromb Thrombolysis* 2011;31:514-22.
36. Latib A, Messika-Zeitoun D, Maisano F, et al. Reversible Edwards Sapien XT dysfunction due to prosthesis thrombosis presenting as early structural deterioration. *J Am Coll Cardiol* 2013;61:787-9.
37. Pibarot P, Dumesnil JG. Prosthetic heart valves: selection of the optimal prosthesis and long-term management. *Circulation* 2009;119:1034-48.
38. Stewart WJ. Thrombosis of bioprosthetic valves: can we afford to ignore it? *J Am Coll Cardiol* 2015;66:2295-7.
39. Barbetseas J, Pitsavos C, Aggeli C, et al. Comparison of frequency of left atrial thrombus in patients with mechanical prosthetic cardiac valves and stroke versus transient ischemic attacks. *Am J Cardiol* 1997;80:526-8.
40. Baddour LM, Wilson WR, Bayer AS, et al. American Heart Association Committee on Rheumatic Fever, Endocarditis, and Kawasaki Disease of the Council on Cardiovascular Disease in the Young, Council on Clinical Cardiology, Council on Cardiovascular Surgery and Anesthesia, and Stroke Council. Infective endocarditis in adults: diagnosis, antimicrobial therapy, and management of complications: a scientific statement for healthcare professionals from the American Heart Association. *Circulation* 2015;132:1435-86.
41. Habets J, Mali WP, Budde RP. Multidetector CT angiography in evaluation of prosthetic heart valve dysfunction. *Radiographics* 2012;32:1893-905.
42. Dangas GD, Giustino G. Art and science of cerebrovascular event prevention after transcatheter aortic valve replacement. *Circ Cardiovasc Interv* 2016;9:e004307.
43. Giustino G, Dangas GD. Stroke prevention in valvular heart disease: from the procedure to long-term management. *EuroIntervention* 2015;11 Suppl W:W26-31.
44. Melgaard L, Gorst-Rasmussen A, Lane DA, et al. Assessment of the CHA2DS2-VASc score in predicting ischemic stroke, thromboembolism, and death in patients with heart failure with and without atrial fibrillation. *JAMA* 2015;314:1030-8.
45. Hamid T, Choudhury TR, Anderson SG, et al. Does the CHA2DS2-Vasc score predict procedural and short-term outcomes in patients undergoing transcatheter aortic valve implantation? *Open Heart* 2015;2:e000170.
46. Mitchell LB, Southern DA, Galbraith D, et al. APPROACH investigators. Prediction of stroke or TIA in patients without atrial fibrillation using CHADS2 and CHA2DS2-VASc scores. *Heart* 2014;100:1524-30.
47. Pisters R, Lane DA, Nieuwlaat R, et al. A novel user-friendly score (HAS-BLED) to assess 1-year risk of major bleeding in patients with atrial fibrillation: the Euro Heart Survey. *Chest* 2010;138:1093-100.
48. Fang MC, Go AS, Chang Y, et al. A new risk scheme to predict warfarin-associated hemorrhage: the ATRIA (Anticoagulation and Risk Factors in Atrial Fibrillation) Study. *J Am Coll Cardiol* 2011;58:395-401.
49. Gage BF, Yan Y, Milligan PE, et al. Clinical classification schemes for predicting hemorrhage: results from the National Registry of Atrial Fibrillation (NRAF). *Am Heart J* 2006;151:713-9.
50. Kovacs RJ, Flaker GC, Saxonhouse SJ, et al. Practical management of anticoagulation in patients with atrial fibrillation. *J Am Coll Cardiol* 2015;65:1340-60.
51. Brennan JM, Edwards FH, Zhao Y, et al., DECIDE AVR Research Team. Early anticoagulation of bioprosthetic aortic valves in older patients: results from the Society of Thoracic Surgeons Adult Cardiac Surgery National Database. *J Am Coll Cardiol* 2012;60:971-7.
52. Mérie C, Køber L, Skov Olsen P, et al. Association of warfarin therapy duration after bioprosthetic aortic valve replacement with risk of mortality, thromboembolic complications, and bleeding. *JAMA* 2012;308:2118-25.
53. Cheng D, Pepper J, Martin J, et al. Stentless versus stented bioprosthetic aortic valves: a systematic review and meta-analysis of controlled trials. *Innovations (Phila)* 2009;4:61-73.
54. Eikelboom JW, Connolly SJ, Brueckmann M, et al., RE-ALIGN Investigators. Dabigatran versus warfarin in patients with mechanical heart valves. *N Engl J Med* 2013;369:1206-14.
55. Jaffer IH, Fredenburgh JC, Hirsh J, et al. Medical device-induced thrombosis: what causes it and how can we prevent it? *J Thromb Haemost* 2015;13 Suppl 1:S72-81.
56. Yau JW, Stafford AR, Liao P, et al. Mechanism of catheter thrombosis: comparison of the antithrombotic activities of fondaparinux, enoxaparin, and heparin in vitro and in vivo. *Blood* 2011;118:6667-74.
57. Yau JW, Stafford AR, Liao P, et al. Corn trypsin inhibitor coating attenuates the prothrombotic properties of catheters in vitro and in vivo. *Acta Biomater* 2012;8:4092-100.
58. Yau JW, Liao P, Fredenburgh JC, et al. Selective depletion of factor XI or factor XII with antisense oligonucleotides attenuates catheter thrombosis in rabbits. *Blood* 2014;123:2102-7.
59. Jaffer IH, Stafford AR, Fredenburgh JC, et al. Dabigatran is less effective than warfarin at attenuating mechanical heart valve-induced thrombin generation. *J Am Heart Assoc* 2015;4:e002322.
60. Dewanjee MK, Gross DR, Zhai P, et al. Thrombogenicity of polyethylene oxide-bonded Dacron sewing ring in a mechanical heart valve. *J Heart Valve Dis* 1999;8:324-30.
61. Yau JW, Liao P, Fredenburgh JC, et al. Only high levels of dabigatran attenuate catheter thrombosis in vitro and in rabbits. *Thromb Haemost* 2014;112:79-86.
62. Greiten LE, McKellar SH, Rysavy J, et al. Effectiveness of rivaroxaban for thromboprophylaxis of prosthetic heart valves in a porcine heterotopic valve model. *Eur J Cardiothorac Surg* 2014;45:914-9.
63. Webb J, Rodés-Cabau J, Frenes S, et al. Transcatheter aortic valve implantation: a Canadian Cardiovascular Society position statement. *Can J Cardiol* 2012;28:520-8.
64. Van Mieghem NM, Schipper ME, Ladich E, et al. Histopathology of embolic debris captured during transcatheter aortic valve replacement. *Circulation* 2013;127:2194-201.

- 65.** Hassell ME, Hildick-Smith D, Durand E, et al. Antiplatelet therapy following transcatheter aortic valve implantation. *Heart* 2015;101:1118-25.
- 66.** Deeb GM, Reardon MJ, Chetcuti S, et al., CoreValve US Clinical Investigators. 3-Year outcomes in high-risk patients who underwent surgical or transcatheter aortic valve replacement. *J Am Coll Cardiol* 2016;67:2565-74.
- 67.** Dangas GD, Lefevre T, Kupatt C, et al., BRAVO-3 Investigators. Bivalirudin versus heparin anticoagulation in transcatheter aortic valve replacement: the randomized BRAVO-3 trial. *J Am Coll Cardiol* 2015;66:2860-8.
- 68.** Van Belle E, Hengstenberg C, Lefevre T, et al. Cerebral embolism during transcatheter aortic valve replacement: the BRAVO-3 MRI Study. *J Am Coll Cardiol* 2016;68:589-99.
- 69.** Windecker S, Tijssen J, Giustino G, et al. Trial design: Rivaroxaban for the prevention of major cardiovascular events post transcatheter aortic valve replacement: rationale and design of the GALILEO study. *Am Heart J* 2017;184:81-7.
- 70.** Assistance Publique - Hôpitaux de Paris. Anti-Thrombotic Strategy After Trans-Aortic Valve Implantation for Aortic Stenosis (ATLANTIS). Available at: <https://clinicaltrials.gov/ct2/show/NCT02664649>. Accessed September 30, 2016.
- 71.** Cheung A, Webb J, Verheye S, et al. Short-term results of transapical transcatheter mitral valve implantation for mitral regurgitation. *J Am Coll Cardiol* 2014;64:1814-9.
- 72.** Anyanwu AC, Adams DH. Transcatheter mitral valve replacement: the next revolution? *J Am Coll Cardiol* 2014;64:1820-4.

KEY WORDS antithrombotic therapies, valve replacement, valvular heart disease



Go to <http://www.acc.org/jacc-journals-cme> to take the CME quiz for this article.