

JACC REVIEW TOPIC OF THE WEEK

Atrial Functional Mitral Regurgitation

JACC Review Topic of the Week



Sébastien Deferm, MD,^{a,b} Philippe B. Bertrand, MD, PhD,^{a,b} Frederik H. Verbrugge, MD, PhD,^{a,b}
David Verhaert, MD,^a Filip Rega, MD, PhD,^c James D. Thomas, MD,^d Pieter M. Vandervoort, MD^{a,b}

JACC JOURNAL CME/MOC/ECME

This article has been selected as the month's JACC CME/MOC/ECME activity, available online at <http://www.acc.org/jacc-journals-cme> by selecting the JACC Journals CME/MOC/ECME tab.

Accreditation and Designation Statement

The American College of Cardiology Foundation (ACCF) is accredited by the Accreditation Council for Continuing Medical Education to provide continuing medical education for physicians.

The ACCF designates this Journal-based CME activity for a maximum of 1 AMA PRA Category 1 Credit(s)[™]. Physicians should claim only the credit commensurate with the extent of their participation in the activity.

Successful completion of this CME activity, which includes participation in the evaluation component, enables the participant to earn up to 1 Medical Knowledge MOC point in the American Board of Internal Medicine's (ABIM) Maintenance of Certification (MOC) program. Participants will earn MOC points equivalent to the amount of CME credits claimed for the activity. It is the CME activity provider's responsibility to submit participant completion information to ACCME for the purpose of granting ABIM MOC credit.

Atrial Functional Mitral Regurgitation: JACC Review Topic of the Week will be accredited by the European Board for Accreditation in Cardiology (EBAC) for 1 hour of External CME credits. Each participant should claim only those hours of credit that have actually been spent in the educational activity. The Accreditation Council for Continuing Medical Education (ACCME) and the European Board for Accreditation in Cardiology (EBAC) have recognized each other's accreditation systems as substantially equivalent. Apply for credit through the post-course evaluation. While offering the credits noted above, this program is not intended to provide extensive training or certification in the field.

Method of Participation and Receipt of CME/MOC/ECME Certificate

To obtain credit for JACC CME/MOC/ECME, you must:

1. Be an ACC member or JACC subscriber.

2. Carefully read the CME/MOC/ECME-designated article available online and in this issue of the *Journal*.
3. Answer the post-test questions. A passing score of at least 70% must be achieved to obtain credit.
4. Complete a brief evaluation.
5. Claim your CME/MOC/ECME credit and receive your certificate electronically by following the instructions given at the conclusion of the activity.

CME/MOC/ECME Objectives for This Article: Upon completion of this activity, the learner should be able to: 1) differentiate the pathophysiological background of atrial functional MR from secondary MR in the context of LV disease; 2) identify atrial functional MR based on patient symptoms, clinical presentation, and characteristic imaging findings; and 3) define the optimal medical and therapeutic treatment strategy for atrial functional MR.

CME/MOC/ECME Editor Disclosure: JACC CME/MOC/ECME Editor Ragavendra R. Baliga, MD, FACC, has reported that he has no financial relationships or interests to disclose.

Author Disclosures: Drs. Deferm and Vandervoort are researchers for the Limburg Clinical Research Program (LCRP) UHasselt-ZOL-Jessa, supported by the foundation Limburg Sterk Merk (LSM), Hasselt University, Ziekenhuis Oost-Limburg, and Jessa Hospital. Dr. Rega has been a consultant for Atricura and LivaNova; and has received research funding from Medtronic. Dr. Thomas has been a consultant for and has received honoraria from Edwards, Abbott, GE, and Bay Labs. All other authors have reported that they have no relationships relevant to the contents of this paper to disclose.

Medium of Participation: Print (article only); online (article and quiz).

CME/MOC/ECME Term of Approval

Issue Date: May 21, 2019

Expiration Date: May 20, 2020



Listen to this manuscript's audio summary by Editor-in-Chief Dr. Valentin Fuster on JACC.org.

From the ^aDepartment of Cardiology, Hospital Oost-Limburg, Genk, Belgium; ^bFaculty of Medicine and Life Sciences, Hasselt University, Hasselt, Belgium; ^cDepartment of Cardiac Surgery, Cardiovascular sciences, Leuven University Hospital, Leuven, Belgium; and the ^dDepartment of Cardiology, Northwestern University, Bluhm Cardiovascular Institute, Chicago, Illinois. Drs. Deferm and Vandervoort are researchers for the Limburg Clinical Research Program (LCRP) UHasselt-ZOL-Jessa, supported by the foundation Limburg Sterk Merk (LSM), Hasselt University, Ziekenhuis Oost-Limburg, and Jessa Hospital. Dr. Rega has been a consultant for Atricura and LivaNova; and has received research funding from Medtronic. Dr. Thomas has been a consultant for and has received honoraria from Edwards, Abbott, GE, and Bay Labs. All other authors have reported that they have no relationships relevant to the contents of this paper to disclose.

Manuscript received January 4, 2019; revised manuscript received February 15, 2019, accepted February 18, 2019.

Atrial Functional Mitral Regurgitation

JACC Review Topic of the Week

Sébastien Deferm, MD,^{a,b} Philippe B. Bertrand, MD, PhD,^{a,b} Frederik H. Verbrugge, MD, PhD,^{a,b} David Verhaert, MD,^a Filip Rega, MD, PhD,^c James D. Thomas, MD,^d Pieter M. Vandervoort, MD^{a,b}

ABSTRACT

Unlike secondary mitral regurgitation (MR) in the setting of left ventricular (LV) disease, the occurrence of functional MR in atrial fibrillation (AF) and/or heart failure with preserved ejection fraction (HFpEF) has remained largely unspoken. LV size and systolic function are typically normal, whereas isolated mitral annular dilation and inadequate leaflet adaptation are considered mechanistic culprits. Moreover, the role of left atrial and annular dynamics in provoking MR is often underappreciated. Because of this peculiar pathophysiology, atrial functional MR benefits from a different approach compared with secondary MR. Although both AF and HFpEF—two closely related disease epidemics of the 21st century—are held responsible, current guidelines do not emphasize the need to differentiate atrial functional MR from (ventricular) secondary MR. This review summarizes the prevalence and prognostic importance of atrial functional MR, providing mechanistic insights compared with those of secondary MR and suggesting potential therapeutic targets. (J Am Coll Cardiol 2019;73:2465-76) © 2019 by the American College of Cardiology Foundation.

Mitral regurgitation (MR) is among the most prevalent of valvular heart diseases, striking >2 million U.S. adults in 2000, and is expected to double by 2030 (1,2). Functional or secondary MR in the context of left ventricular (LV) dysfunction occurs in 20% to 25% of patients after myocardial infarction and in up to 50% of heart failure patients (3). The occurrence of functional MR in patients with atrial fibrillation (AF) but normal LV size and function has received less attention, despite its unique pathophysiology. Historically, isolated mitral annular (MA) dilation has been considered the mechanical culprit, but recent evidence has added important nuances (4-8). Specifically, the role of left atrial (LA) and annular dynamics in these subjects may be underappreciated. In addition, atrial functional MR—because of its peculiar pathophysiology—may require a different approach compared with secondary MR caused by increased tethering and/or decreased closing forces. Current guidelines do not acknowledge this distinction (9,10). This review explores the current mechanistic understanding of atrial functional MR and suggests potential therapeutic targets.

FUNCTIONAL MR SPECTRUM: DYNAMIC INTERPLAY BETWEEN CLOSING AND TETHERING FORCES

The mitral valve is an intricate apparatus that allows inflow of blood from the LA to the LV during diastole, while preventing systolic backflow

(Central Illustration). To fulfill this task, a delicate interplay between LV contraction and/or relaxation, papillary muscle contraction, annular motion, and leaflets is mandatory. Any disturbance of this interplay affects systolic leaflet coaptation and may cause MR.

Functional MR is the result of an imbalance between increased tethering forces (due to global and/or focal LV dilation, papillary muscle displacement and/or dysfunction) and decreased closing forces (reduced LV contractility and/or synchronicity) in the presence of a structurally normal valve. Annular dimensions (tethering) and dynamics (closing) contribute to this imbalance in ischemic or dilated cardiomyopathy, although concomitant subvalvular tethering is typically needed to cause more than moderate (ventricular) functional MR (3,11). Conversely, it has become clear that instead of being the end result of longstanding MR, isolated annular dilation can be a distinct etiology of MR (atrial functional MR) at the other end of the functional MR spectrum, typically in the context of AF (4) and/or heart failure with preserved ejection fraction (HFpEF) with severe LA dilation (Central Illustration, Figure 1) (12). In this review, functional MR caused by subvalvular tethering will be referred to as secondary MR.

ATRIAL FUNCTIONAL MR: PREVALENCE AND CLINICAL IMPLICATIONS

Contrary to secondary MR, which has a prevalence of up to 16,250 per million individuals (2), the

HIGHLIGHTS

- Atrial functional MR typically occurs in the context of AF and/or HFpEF.
- Isolated annular dilation, insufficient leaflet growth, and impaired annular dynamics are mechanical culprits.
- Early discrimination between atrial functional MR and secondary MR is pivotal to accommodate for different therapeutic needs.
- Further study is needed to clarify the impact of early rhythm restoration strategies and mitral annular interventions to treat atrial functional MR.

proportion with atrial functional MR is unknown. In the original analysis by Carpentier et al. (13), nearly all cases of type I disease (normal leaflet motion) were organic. In the current era, the opposite seems true, considering that the incidence of AF (14) and HFpEF (15) is growing epidemically.

The number of individuals with AF in 2010 was 33.5 million globally, with annual new cases of approximately 5 million (14). Significant atrial functional MR was present in 7% of patients referred for their first AF ablation (8). Similarly, Kim et al. (16) found a 4.3% prevalence among 1,247 cases of persistent AF.

The proportion of those with HFpEF varied in 3 epidemiological cohort studies according to baseline age (53.3%, 46.5%, and 36.9% of all heart failure events were subclassified as HFpEF in the Cardiovascular Health, the Framingham Heart, and the Prevention of Renal and Vascular End-Stage Disease studies, respectively) (15).

Moreover, one-third and two-thirds of patients with HFpEF experience AF at time of diagnosis or at some point during the disease, respectively (17). In contrast, undiagnosed HFpEF is highly prevalent in AF patients with unexplained exertional dyspnea (in 98% with persistent and/or permanent AF) (18). When HFpEF and AF coexist, greater LA remodeling, natriuretic peptide elevation, exertional intolerance, and worse outcome are observed (19). Whether this reflects a larger prevalence of atrial functional MR is uncertain, but likely.

Early recognition of atrial functional MR seems important because it relates to the success of ablation (20), and considering maintenance of sinus rhythm significantly decreases MR severity (8). The ATTEND (Acute decompensated heart failure syndromes)

registry (21) found 53% and 18% of 1,825 decompensated patients with HFpEF still showed mild or moderate-to-severe functional MR at discharge, respectively, which was linked to worse outcome (Figure 2).

PATHOPHYSIOLOGY OF ATRIAL FUNCTIONAL MR

ISOLATED ANNULAR DILATION. The sequential relationship between AF-induced LA enlargement, MA dilation, and MR remains a matter of debate (Central Illustration) (5,6). Nevertheless, multiple studies have implicated isolated MA dilation as the main culprit for leaflet malcoaptation in AF patients, independent of LV dimensions. Gertz et al. (8)

retrospectively compared 53 patients with moderate to severe type I functional MR and normal LV ejection fraction ($\geq 50\%$) to a matched AF cohort with trivial and/or mild MR during first AF ablation. Patients with MR had significantly larger LA and MA dimensions despite having similar LV size or function. After multivariate regression, persistent AF, age, and isolated MA dilation (odds ratio: 8.39; $p = 0.004$) were linked to significance of MR. After subcategorization of the MR cohort according to rhythm at follow-up, 82% of patients with AF recurrence still showed significant MR compared with 24% of patients who had successful ablation ($p = 0.005$), despite comparable MR severity at baseline ($p = 0.72$) (Figure 3). The latter subgroup experienced significant reductions in LA size (LA volume index $28.2 \text{ cm}^3/\text{m}^2$ vs. $23.9 \text{ cm}^3/\text{m}^2$; $p = 0.02$) and MA dimensions (3.41 cm vs. 3.24 cm ; $p = 0.02$) opposed to the near-significant LA size reductions in the recurrence subgroup ($p = 0.06$). Thus, AF itself may be seen as an instigator for type I functional MR, rather than simply a consequence of MR, mediating its effect through LA and MA dilation.

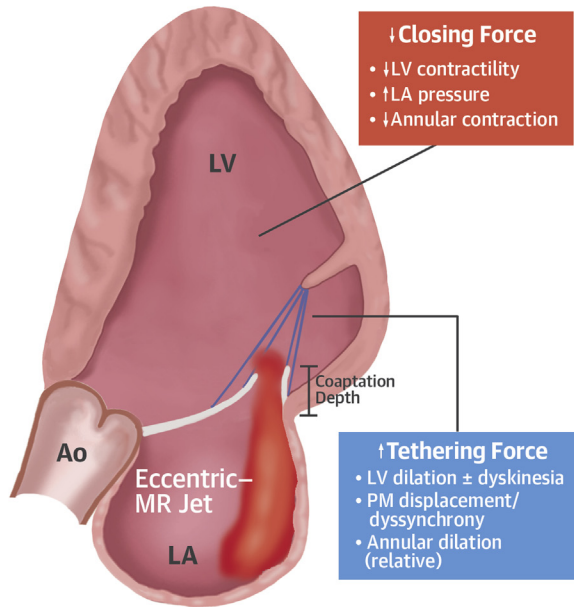
Alternatively, HFpEF might give rise to atrial functional MR through MA dilation, even in the absence of AF. Both AF and HFpEF share pathophysiological grounds (22) (Figure 4). Diastolic dysfunction and increased LA pressures, due to neurohormonal imbalances (depletion of atrial natriuretic peptide and activation of the renin-angiotensin-aldosterone system [RAAS]) (22) account for a major role, resulting in excessive LA stretch and fibrosis. Atrial remodeling facilitates initiation and maintenance of atrial functional MR and AF. In contrast, AF contributes to LV fibrosis, diastolic dysfunction, and therefore, HFpEF (22), and subsequently, atrial functional MR.

ABBREVIATIONS AND ACRONYMS

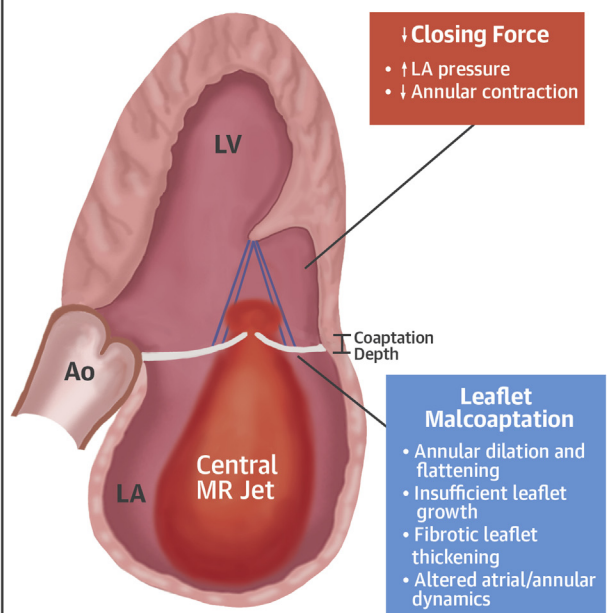
- 3D** = 3-dimensional
- AF** = atrial fibrillation
- CRT** = cardiac resynchronization therapy
- HFpEF** = heart failure with preserved ejection fraction
- HFrEF** = heart failure with reduced ejection fraction
- LA** = left atrial
- LV** = left ventricular
- MA** = mitral annulus
- MR** = mitral regurgitation
- RAAS** = renin-angiotensin-aldosterone system

CENTRAL ILLUSTRATION Secondary Mitral Regurgitation Versus Atrial Functional Mitral Regurgitation

Secondary Mitral Regurgitation



Atrial Functional Mitral Regurgitation



Etiology and Prevalence

- 11%-59% post myocardial infarction
- >50% in dilated cardiomyopathy

Diagnosis

- Systolic LV dysfunction
- Restricted leaflet motion and tethering
- Eccentric jet > central jet
- Relative LA dilation

Management

- Optimal HF therapy
- Cardiac resynchronization therapy
- Revascularization
- MitraClip

- 6%-7% in lone AF
- Up to 53% in HFpEF

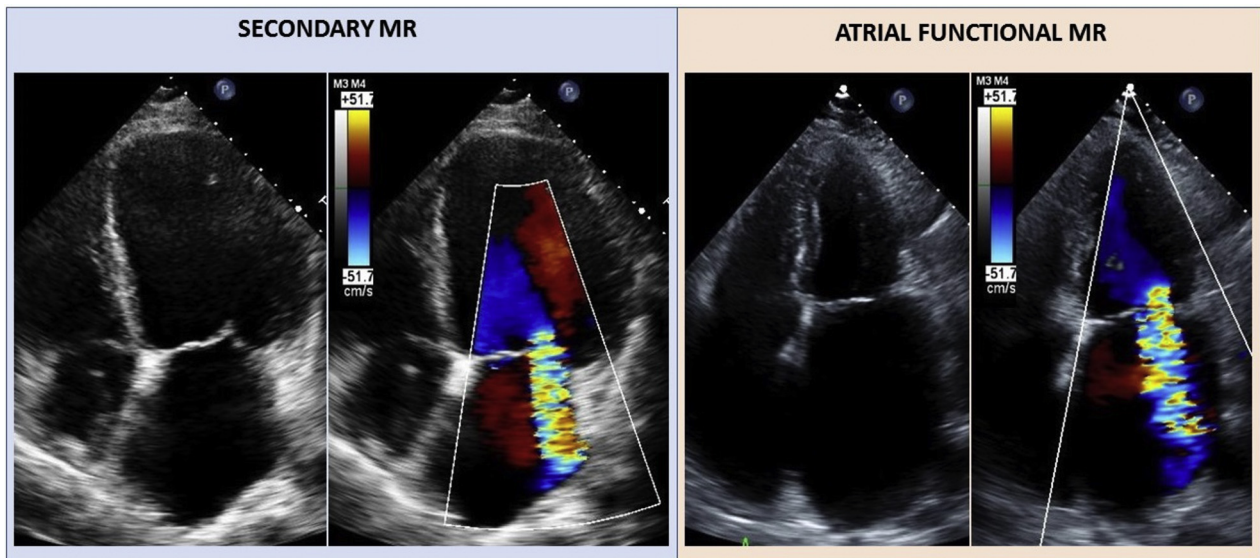
- Normal systolic LV function
- Normal leaflet motion
- Central jet
- Severe LA dilation

- Address AF/HFpEF risk factors and lifestyle
- HF therapy, diuretics as indicated
- Early sinus restoration strategy
- ?Intervention, annuloplasty, MitraClip

Deferm, S. et al. J Am Coll Cardiol. 2019;73(19):2465-76.

AF = atrial fibrillation; Ao = aorta; HF = heart failure; HFpEF = heart failure with preserved ejection fraction; LA = left atrium; LV = left ventricle; MR = mitral regurgitation; PM = papillary muscle.

FIGURE 1 Echocardiographic Comparison of Secondary MR in the Context of LV Disease, Opposed to Atrial Functional MR



Subvalvular leaflet tethering with eccentric mitral regurgitation (MR) jet in secondary MR (left) and excessive left atrial dilation with central MR jet in atrial functional MR (right).

However, annular dilation solves only 1 piece of the puzzle, considering the large disparities in MR burden, despite the similar amounts of MA dilation seen in clinical practice.

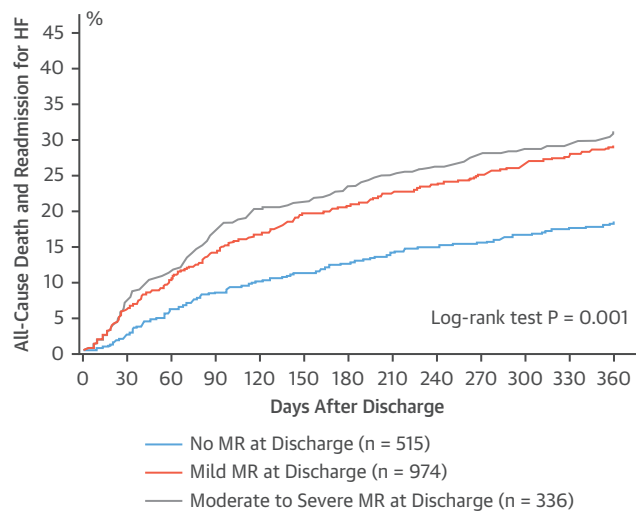
INSUFFICIENT COMPENSATORY LEAFLET GROWTH.

Cardiac valves are no longer seen as static structures. Instead, compensatory leaflet growth secondary to altered cardiac dimensions is increasingly being recognized (23). An increase in leaflet area and thickness was reported in response to subvalvular leaflet tethering in sheep (24). These changes were attributed to endothelial cells co-expressing α -smooth muscle actin more in tethered leaflets ($41 \pm 19\%$ vs. $9 \pm 5\%$; $p = 0.02$), which indicated endothelial-mesenchymal transdifferentiation.

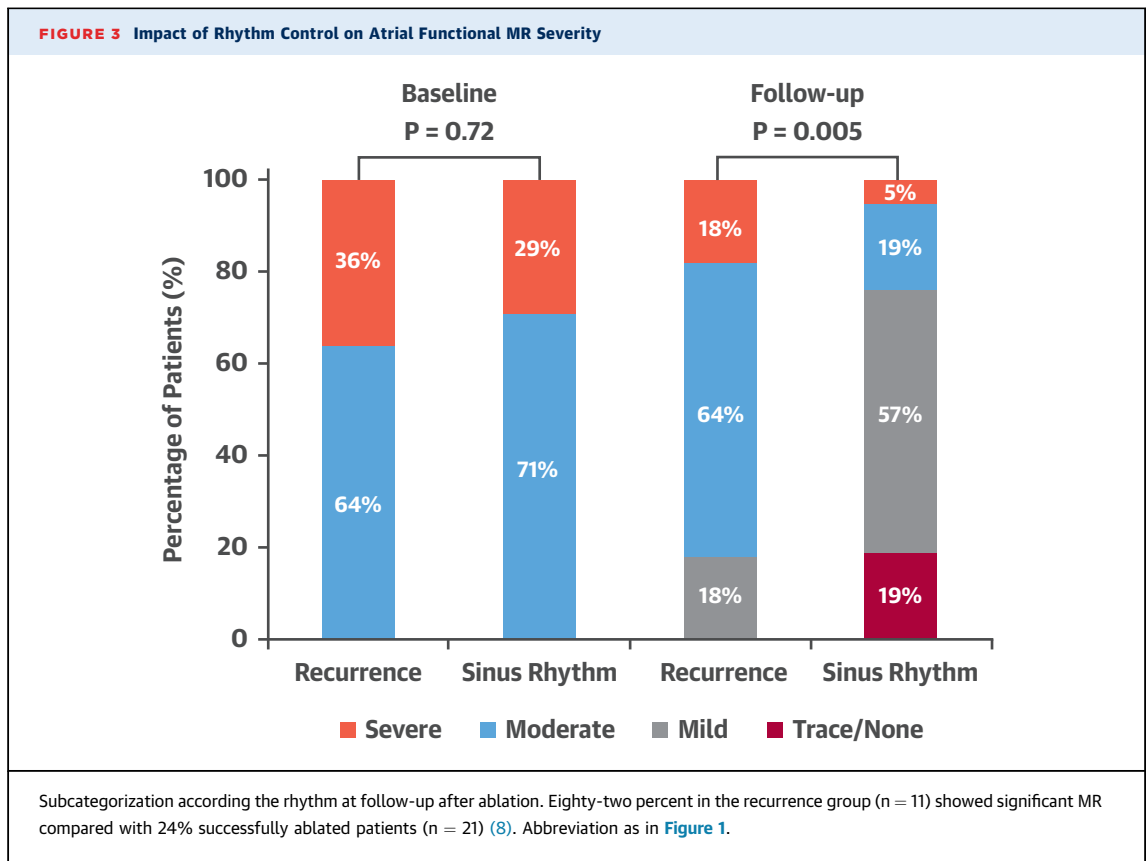
Two studies (16,25) addressed the question of whether leaflet area adaptation occurs when functional MR arises from isolated annular dilation. Kagiya et al. (25) found a significant larger leaflet area exclusively in patients with AF but without MR compared with control subjects. Conversely, Kim et al. (16) found the leaflet area was significantly larger in all AF subjects, paralleling significant increases in MA area. The ratio of total leaflet area to MA area was significantly smaller in the MR group versus the AF group without MR and control subjects (16,25), specifically at lesser degrees of annular

dilation (16). When the MA dilates profoundly, the increase in leaflet area plateaus, indicating that insufficient leaflet adaptation serves as a contributing factor for MR (Figure 5).

FIGURE 2 Kaplan-Meier Estimate of All-Cause Mortality and HF Readmission Stratified by MR Severity at Discharge in HFrEF



MR at discharge was linked to worse outcome in HFrEF (21). HFrEF = heart failure with preserved ejection fraction; other abbreviation as in Figure 1.



ATRIAL AND ANNULAR DYNAMICS. The MA is a fibrofatty ring that sways passively, depending on the aortic root motion besides contraction and/or relaxation of adjacent LA and mostly LV musculature. Early systolic anteroposterior contraction promotes annular size reduction, whereas the inter-commissural diameter behaves relatively fixed (26). Annular narrowing is accompanied by height increases near the midanterior and midposterior point. Consequently, the MA folds along the septolateral-intercommissural axis, which accentuates its saddle-shape and promotes coaptation (26). Simultaneously, a translational motion enforces LA and LV filling and/or emptying during systole and diastole (26) (Figure 6).

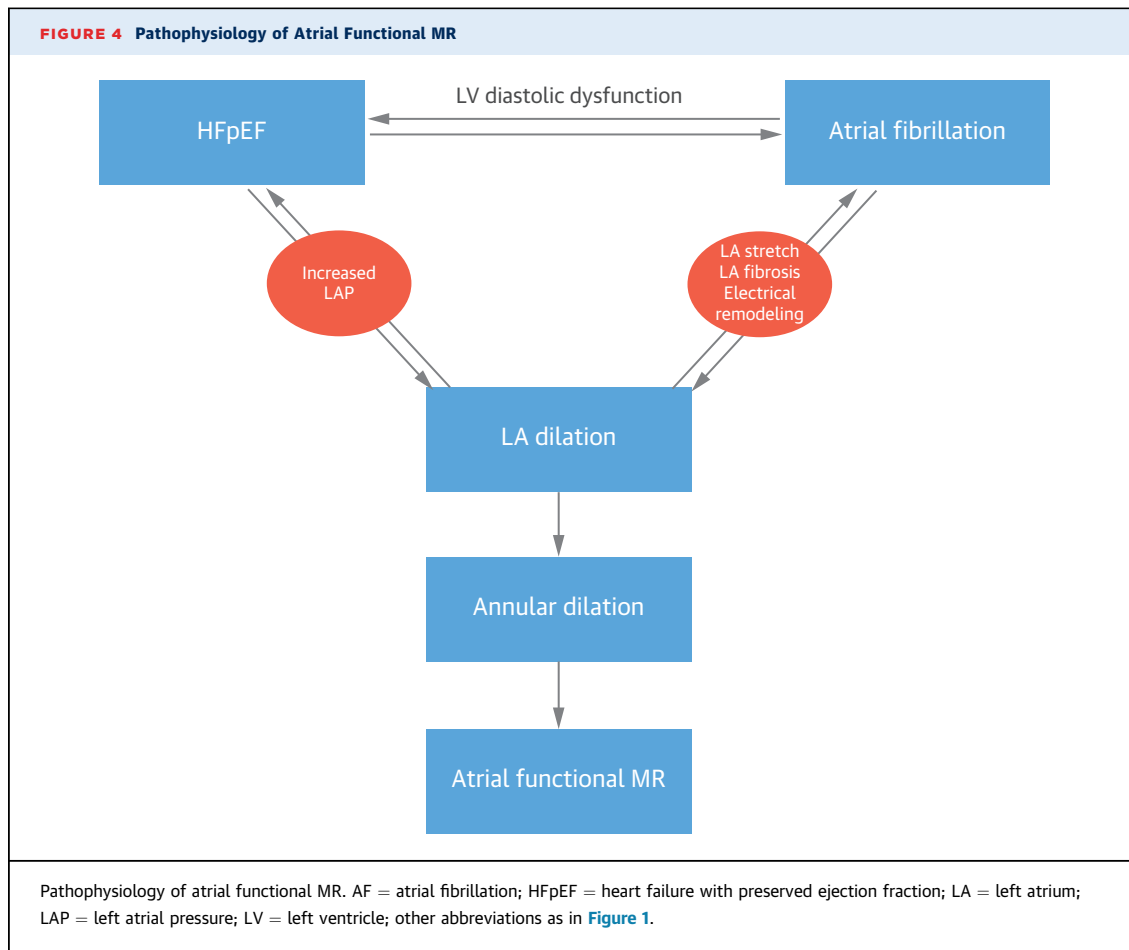
Which part of this 3-fold motion is impaired during AF or LA hypertension, and whether this is important for the mechanics behind atrial functional MR is vague. Fractional annular area change was smaller in AF patients and smallest in those with AF and MR, together with a flattened annulus (16). To what extent impaired LA dynamics affect annular behavior is unclarified. Pre-systolic circumferential narrowing may be harmed, although recent 3-dimensional (3D)

techniques minimized the contribution of LA systole. In addition, LA enlargement and dysfunction lower the threshold toward AF development, instigating a vicious circle of adverse remodeling and perpetuation of MR.

ECHOCARDIOGRAPHIC DIAGNOSIS

Echocardiography is the cornerstone of the evaluation of mitral valve disease (Figure 1). Primary MR etiologies are identified based on leaflet appearance and/or motion. In functional MR, the leaflets are considered normal, although mild fibrotic leaflet thickening or annular calcification can be seen.

In secondary MR, leaflet motion appears restricted and the coaptation point is found at distance from the annular plane due to LV disease. Tethering occurs either symmetrically in global LV dilation or more often asymmetrically posteriorly in ischemic disease. Tenting height (distance from the coaptation point to the annular plane) and tenting area (area between leaflets and annular plane) allow quantification of the tethering degree that is associated with MR severity. Finally, because of longstanding LA volume overload



(and to a lesser extent, LV dilation), annular dilation is noticeable (27).

In atrial functional MR, LV ejection fraction and volumes are invariably normal, although global longitudinal strain may be impaired. The coaptation point is typically found at the annular plane with the MR jet located centrally along the coaptation line. Annular dilation applies when the systolic anteroposterior diameter exceeds 35 mm (parasternal long axis) or when the ratio of the systolic annular diameter/diastolic anterior leaflet length exceeds 1.3 (27).

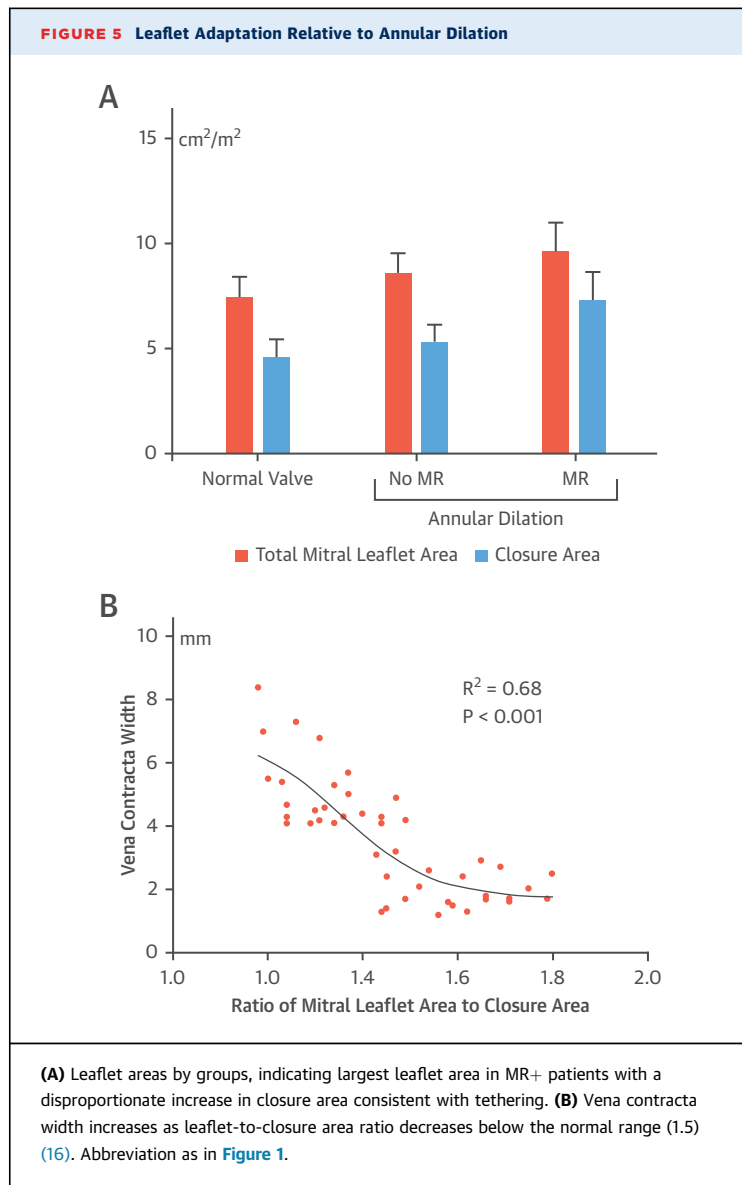
In 211 healthy subjects, mean 3D annular area was $8.4 \pm 1.9 \text{ cm}^2$. Tenting height and area were $6.2 \pm 1.5 \text{ mm}$ and $1.1 \pm 0.5 \text{ cm}^2$, respectively. Tenting height was significantly lower for a similar degree of annular dilation in atrial functional MR, as opposed to secondary MR ($3.5 \pm 1.5 \text{ mm}$ vs. $8.1 \pm 2.4 \text{ mm}$; $p < 0.001$) after quantitative analysis of 3D datasets (28). Nevertheless, even in atrial functional MR, subtle leaflet tethering occurred when there was insufficient leaflet adaptation to match annular remodeling (16). Biatrial dilatation is commonly present in this

population with longstanding AF and/or HFpEF, with concomitant tricuspid regurgitation adding complexity to diagnosis and management. In addition, the prevalence and impact of concomitant aortic stenosis in HFpEF patients with atrial functional MR is yet to be elucidated.

MANAGEMENT OF ATRIAL FUNCTIONAL MR

Current guidelines (9,10) do not discriminate between secondary and atrial functional MR, although MR in these entities is rooted in different pathophysiological backgrounds. Currently, the management of atrial functional MR is incompletely understood, mainly due to lack of data in this distinct patient population.

OPTIMAL HEART FAILURE THERAPY. Guideline-directed medical therapy is the cornerstone of treatment for secondary MR because MR adds volume overload to a decompensated LV (9,10). Beta-blockers (29), angiotensin-converting enzyme inhibitors (30),



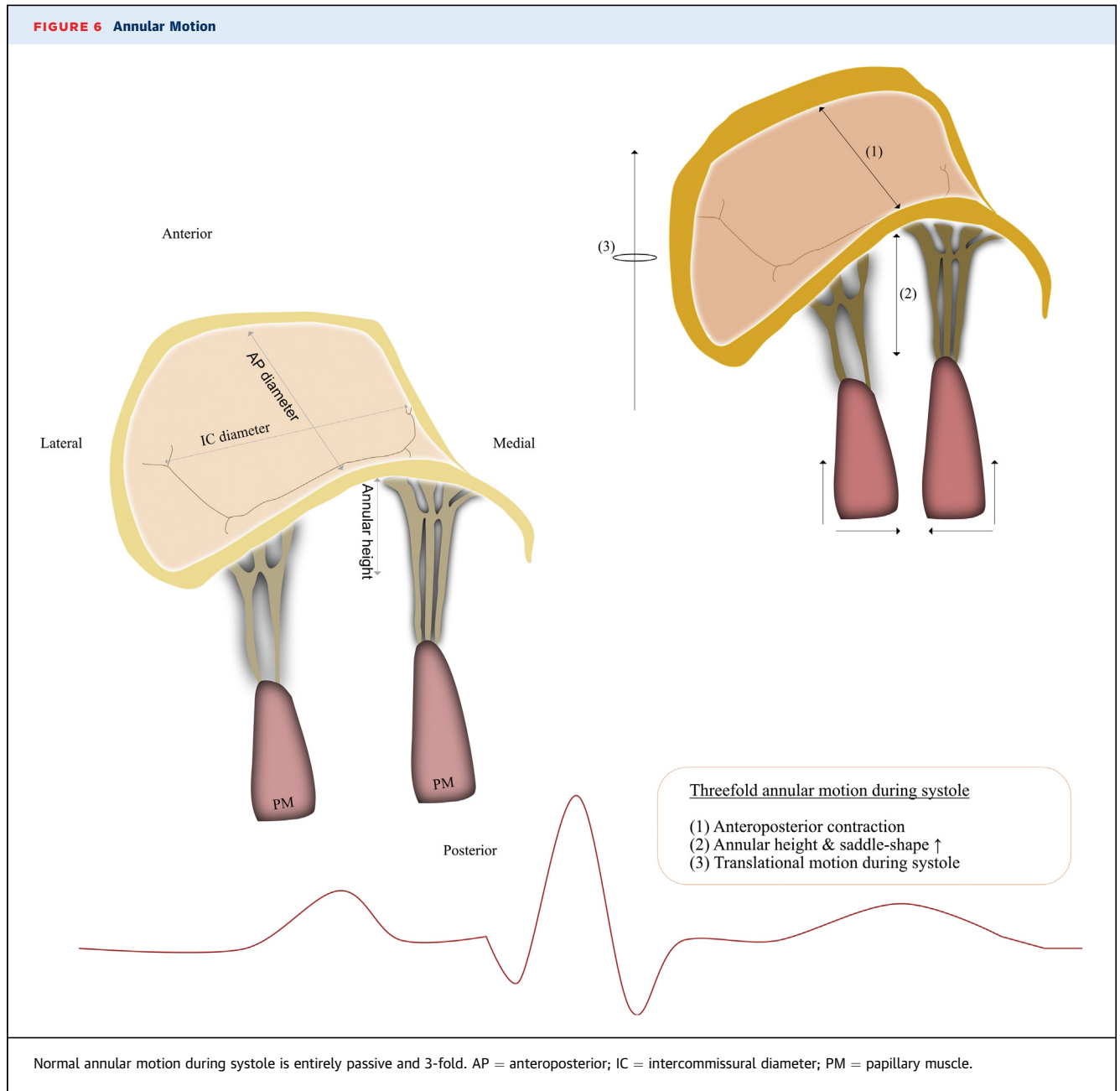
and sacubitril-valsartan (31) reduce secondary MR due to LV reverse remodeling. Secondary analysis of the COAPT (Cardiovascular Outcomes Assessment of the MitraClip Percutaneous Therapy for Heart Failure Patients With Functional Mitral Regurgitation) trial (32) may provide insights into the effects of medical therapy on MR severity because many patients became ineligible after adequate treatment. Additionally, CRT-induced alleviation of secondary MR is attributed acutely to increased closing forces (33) together with papillary muscle resynchronization (34) and chronically to reductions in LV dimensions (35). MR improvement after CRT was less common in patients with AF versus those in sinus rhythm,

despite comparable LV reverse remodeling. Baseline LA volumes and MA diameters were significantly greater in AF and remained unchanged, suggesting an atrial contribution for differences in MR response following CRT (36).

Medical therapy for contemporaneous HFpEF and AF is no different than that in sinus rhythm, although no drug has been proven to reduce morbidity and/or mortality. Therapies that reduce elevated LA pressures and prevent LA remodeling and fibrosis may limit the risk of AF and atrial functional MR. RAAS inhibition might lower the incidence of new-onset AF and recurrence, although this effect was less in patients with HFpEF (37) and absent in those without heart failure (38). Spironolactone was not superior to placebo in HFpEF, although a significant reduction in primary outcome was noted exclusively in the American subgroup (39). The IMPRESS-AF (Spironolactone in Atrial Fibrillation; NCT02673463) trial is investigating whether spironolactone improves exercise capacity and diastolic function in patients with HFpEF with permanent AF. Moreover, sacubitril-valsartan significantly reduced LA volumes, regardless of an unaltered diastolic (dys)function in HFpEF (40). Whether the use of these drugs translates to a lower incidence of atrial functional MR remains to be answered.

RHYTHM CONTROL STRATEGIES. A rhythm control strategy for AF did not show differences in survival and cardiovascular events compared with rate control in the AFFIRM (Atrial Fibrillation Follow-up Investigation of Rhythm Management) trial, nor in a subgroup with HFpEF (41,42). Nevertheless, LA enlargement itself is associated with adverse events in AF (43).

Dell'Era et al. (44) reported improvements in LA volume (from 41.12 ± 12.92 ml/m² to 37.56 ± 12.60 ml/m²) and peak atrial longitudinal strain (from $11.4 \pm 5.2\%$ to $17.2 \pm 7.5\%$; $p < 0.001$), and less MR (MR jet/LA area from 0.11 ± 0.1 to 0.07 ± 0.07 ; $p < 0.001$) 1 month after cardioversion. Significantly lower rates of MR were found in successfully ablated patients compared with the recurrence group (24% vs. 82%; $p = 0.005$), together with greater LA and MA remodeling (8). Thereafter, multiple studies observed congruent findings post-ablation (45,46). Furthermore, Lam et al. (19) highlighted worse hemodynamics, LA dilation, and neurohormonal stress when HFpEF and AF coexist (47). In contrast, improvements in diastolic function were found in patients with HFpEF who maintained sinus rhythm after ablation (48). These studies advocate that



targeting AF might prevent progression of HFpEF, and, potentially, atrial functional MR.

Therefore, atrial functional MR might benefit from sinus rhythm restoration strategies via reverse LA anatomical and mechanical remodeling. Preferably, this strategy should be adapted in early stages of the disease because AF duration is inversely linked to the ability to maintain sinus rhythm (49). Future prospective trials that will examine the effect of early stage ablation on reversal of type I functional

MR are awaited. Ablation proved superior to drug therapy for decreasing the incidence of death or cardiovascular re-hospitalization in AF (50). Currently, the EAST (Early Treatment of Atrial Fibrillation for Stroke Prevention Trial; NCT01288352) study is investigating whether early rhythm control therapy can prevent AF-related complications. Hopefully, these trials will include echocardiographic follow-up to determine the impact on the severity of MR.

MITRAL VALVE INTERVENTION. Surgical restrictive mitral annuloplasty that enhances leaflet coaptation by reducing annular dimensions has long been the gold standard approach for secondary MR based on good mid-term data from observational studies (51). However, recurrence rates up to 32.6% have been reported 12 months after initial successful annuloplasty (52), which reflect ongoing leaflet tethering caused by continued LV remodeling, regardless of annular size reduction (53).

In contrast, when the fundamental mechanism of functional MR is annular dilation, targeting the MA only might prove beneficial. Kihara et al. (54) and Takahashi et al. (55) reported good short-term outcomes after annuloplasty in 12 and 10 cases of atrial functional MR, respectively. In contrast, the need for annuloplasty (on top of sinus rhythm restoration) was questioned by the 1-year follow-up data by Gertz et al. (8). Mitral valve repair might function as a bailout therapy in these patients when early adapted rhythm restoration strategies fail to reduce MR.

The net effect of the MitraClip (Abbott Vascular, Menlo Park, California) on atrial functional MR reduction has not been studied, although it is assumed to be effective considering its effect on the anterior-posterior MA diameter (56). The Carillon System (Cardiac Dimensions Inc., Kirkland, Washington) uses the proximity of the coronary sinus to the posterior annulus for annular remodeling (CARILLON [Assessment of the Carillon Mitral Contour System in Treating Functional Mitral Regurgitation Associated With Heart Failure] trial; NCT03142152). Cardioband (Edwards Lifesciences, Irvine, California) improves coaptation after fixation of an adjustable band posteriorly from commissure-to-commissure (Edwards Cardioband System ACTIVE Pivotal Clinical Trial; NCT03016975). MitraLign (MitrAlign Inc., Highwood Drive, Massachusetts) mimics surgical suture annuloplasty by pulling P1 to P3 pledgets together.

LEAFLET (MAL)ADAPTATION. Even in adult life, the mitral valve remains a dynamic environment capable of reactivating growth processes in response to superimposed stresses (23). However, these compensatory changes act as a double edged-sword. Tethering stimulates leaflet growth (57) but also counterproductive thickening (57) and fibrosis (58), further impairing coaptation. This organic contribution is governed by transforming growth factor- β

overexpression, which results in endothelial-to-mesenchymal transition. By inhibition of transforming growth factor- β , losartan is able prevent pro-fibrotic changes without eliminating compensatory growth (59). Sacubitril-valsartan acts synergistically on this pathway without interfering with growth (60).

To what extent MA dilation triggers compensatory leaflet changes (16,25) and whether identical embryonic pathways are addressed is unclear. A deeper understanding of underlying cellular and molecular mechanisms might trigger new therapeutic opportunities to restore physiological biomechanics.

CONCLUSIONS AND FUTURE PERSPECTIVES

Atrial functional MR is a distinct form of type I functional MR, with a unique pathophysiology. Data on its prevalence is scant due to the fact that this entity is under-recognized and under-reported. HFpEF and/or AF, 2 closely related disease epidemics of the 21st century are held responsible, and occurrence of MR is associated with worse outcome. Various studies have suggested that atrial functional MR finds its roots in AF or HFpEF-induced LA remodeling and subsequent annular dilation. Although annular dilation is a prerequisite for leaflet malcoaptation, insufficient leaflet remodeling is a second major culprit mechanism. In addition, the effects of mitral annular dynamics probably play an important role, although more quantitative echocardiographic studies are needed to provide deeper mechanistical understanding. Furthermore, distinguishing atrial functional from secondary MR caused by LV disease is pivotal, considering their different pathophysiology and therapeutic needs. In contrast to secondary MR, the key to successful treatment of significant atrial functional MR might consist of early adapted strategies to prevent LA dilatation and restore sinus rhythm. Prospective trials comparing rhythm restoration with surgical/endo-vascular strategies are to be awaited to unravel this enigma. Also, surgical and percutaneous approaches targeting the MA might prove beneficial in these subjects.

ADDRESS FOR CORRESPONDENCE: Dr. Pieter M. Vandervoort, Department of Cardiology, Ziekenhuis Oost-Limburg, Schiepse Bos 6, 3600 Genk, Belgium. E-mail: pieter.vandervoort@zol.be. Twitter: [@pietvandervoort](https://twitter.com/pietvandervoort).

REFERENCES

1. Nkomo VT, Gardin JM, Skelton TN, Gottdiener JS, Scott CG, Enriquez-Sarano M. Burden of valvular heart diseases: a population-based study. *Lancet* 2006;368:1005-11.
2. De Marchena E, Badiye A, Robalino G, et al. Respective prevalence of the different Carpentier classes of mitral regurgitation: a stepping stone for future therapeutic research and development. *J Card Surg* 2011;26:385-92.
3. Levine RA, Schwammenthal E. Ischemic mitral regurgitation on the threshold of a solution: from paradoxes to unifying concepts. *Circulation* 2005;112:745-58.
4. Hoit BD. Atrial functional mitral regurgitation: the left atrium gets its due respect. *J Am Coll Cardiol* 2011;58:1482-4.
5. Otsuji Y, Kumanohoso T, Yoshifuku S, et al. Isolated annular dilation does not usually cause important functional mitral regurgitation: comparison between patients with lone atrial fibrillation and those with idiopathic or ischemic cardiomyopathy. *J Am Coll Cardiol* 2002;39:1651-6.
6. Zhou X, Otsuji Y, Yoshifuku S, et al. Impact of atrial fibrillation on tricuspid and mitral annular dilatation and valvular regurgitation. *Circ J* 2002;66:913-6.
7. Tanimoto M, Pai RG. Effect of isolated left atrial enlargement on mitral annular size and valve competence. *Am J Cardiol* 1996;77:769-74.
8. Gertz ZM, Raina A, Saghy L, et al. Evidence of atrial functional mitral regurgitation due to atrial fibrillation: reversal with arrhythmia control. *J Am Coll Cardiol* 2011;58:1474-81.
9. Nishimura RA, Otto CM. 2017 AHA/ACC focused update of the 2014 AHA/ACC guideline for the management of patients with valvular heart disease: a report of the American College of Cardiology/American Heart Association Task Force on Clinical Practice Guidelines. *J Am Coll Cardiol* 2017;70:252-89.
10. Baumgartner H, Falk V, Bax JJ, et al. 2017 ESC/EACTS guidelines for the management of valvular heart disease. *Eur Heart J* 2017;38:2739-86.
11. Bertrand PB, Schwammenthal E, Levine RA, Vandervoort PM. Exercise dynamics in secondary mitral regurgitation: pathophysiology and therapeutic implications. *Circulation* 2017;135:297-314.
12. Ennezat PV, Maréchaux S, Pibarot P, Le Jemtel TH. Secondary mitral regurgitation in heart failure with reduced or preserved left ventricular ejection fraction. *Cardiology* 2013;125:110-7.
13. Carpentier A, Chauvaud S, Fabiani JN, et al. Reconstructive surgery of mitral valve incompetence: ten-year appraisal. *J Thorac Cardiovasc Surg* 1980;79:338-48.
14. Chugh SS, Havmoeller R, Narayanan K, et al. Worldwide epidemiology of atrial fibrillation: a global burden of disease 2010 study. *Circulation* 2014;129:837-47.
15. Dunlay SM, Roger VL, Redfield MM. Epidemiology of heart failure with preserved ejection fraction. *Nat Rev Cardiol* 2017;14:591-602.
16. Kim DH, Heo R, Handschumacher MD, et al. Mitral valve adaptation to isolated annular dilation. Insights into the mechanism of atrial functional mitral regurgitation. *J Am Coll Cardiol* 2017;10:1-13.
17. Zakeri R, Chamberlain AM, Roger VL, Redfield MM. Temporal relationship and prognostic significance of atrial fibrillation in heart failure patients with preserved ejection fraction: a community-based study. *Circulation* 2013;128:1085-93.
18. Reddy YNV, Obokata M, Gersh BJ, Borlaug BA. High prevalence of occult heart failure with preserved ejection fraction among patients with atrial fibrillation and dyspnea. *Circulation* 2018;137:534-5.
19. Lam CSP, Rienstra M, Tay WT, et al. Atrial fibrillation in heart failure with preserved ejection fraction: association with exercise capacity, left ventricular filling pressures, natriuretic peptides, and left atrial volume. *J Am Coll Cardiol* 2017;59:2-8.
20. Gertz ZM, Raina A, Mountantonakis SE, et al. The impact of mitral regurgitation on patients undergoing catheter ablation of atrial fibrillation. *Europace* 2011;13:1127-32.
21. Kajimoto K, Sato N, Takano T. Functional mitral regurgitation at discharge and outcomes in patients hospitalized for acute decompensated heart failure with a preserved or reduced ejection fraction. *Eur J Heart Fail* 2016;18:1051-9.
22. Kotecha D, Lam CSP, Van Veldhuisen DJ, Van Gelder IC, Voors AA, Rienstra M. Heart failure with preserved ejection fraction and atrial fibrillation: vicious twins. *J Am Coll Cardiol* 2016;68:2217-28.
23. Levine RA, Hagège AA, Judge DP, et al. Mitral valve disease-morphology and mechanisms. *Nat Rev Cardiol* 2015;12:689-710.
24. Dal-Bianco JP, Aikawa E, Bischoff J, et al. Active adaptation of the tethered mitral valve: insights into a compensatory mechanism for functional mitral regurgitation. *Circulation* 2009;120:334-42.
25. Kagiya M, Hayashida A, Toki M, et al. Insufficient leaflet remodeling in patients with atrial fibrillation: association with the severity of mitral regurgitation. *Circ Cardiovasc Imaging* 2017;10:e005451.
26. Levack MM, Jassar AS, Shang EK, et al. Three-dimensional echocardiographic analysis of mitral annular dynamics: implication for annuloplasty selection. *Circulation* 2012;126:7-8.
27. Zoghbi WA, Adams D, Bonow RO, et al. Recommendations for noninvasive evaluation of native valvular regurgitation: a report from the American Society of Echocardiography developed in Collaboration with the Society for Cardiovascular Magnetic Resonance. *J Am Soc Echocardiogr* 2017;30:303-71.
28. Ring L, Dutka DP, Wells FC, Fynn SP, Shapiro LM, Rana BS. Mechanisms of atrial mitral regurgitation: insights using 3D transoesophageal echo. *Eur Heart J Cardiovasc Imaging* 2014;15:500-8.
29. Waagstein F, Strömblad O, Andersson B, et al. Increased exercise ejection fraction and reversed remodeling after long-term treatment with metoprolol in congestive heart failure: a randomized, stratified, double-blind, placebo-controlled trial in mild to moderate heart failure due to ischemic or idiopathic dilated cardiomyopathy. *Eur J Heart Fail* 2003;5:679-91.
30. Levine AB, Muller C, Levine TB. Effects of high-dose lisinopril-isosorbide dinitrate on severe mitral regurgitation and heart failure remodeling. *Am J Cardiol* 1998;82:1299-301.
31. Kang RT, Mitral F. Angiotensin receptor neprilysin inhibitor for functional mitral regurgitation: PRIME study. *Circulation* 2018;139:1354-65.
32. Stone GW, Lindenfeld J, Abraham WT, et al. Transcatheter mitral-valve repair in patients with heart failure. *N Engl J Med* 2018;379:2307-18.
33. Breithardt OA, Sinha AM, Schwammenthal E, et al. Acute effects of cardiac resynchronization therapy on functional mitral regurgitation in advanced systolic heart failure. *J Am Coll Cardiol* 2003;41:765-70.
34. Bartko PE, Arfsten H, Heitzinger G, et al. Papillary muscle dyssynchrony-mediated functional mitral regurgitation. *J Am Coll Cardiol* 2018 Aug 15 [E-pub ahead of print].
35. St. John Sutton M, Ghio S, Plappert T, et al. Cardiac resynchronization induces major structural and functional reverse remodeling in patients with New York Heart Association class I/II heart failure. *Circulation* 2009;120:1858-65.
36. van der Bijl P, Vo NM, Leung M, et al. Impact of atrial fibrillation on improvement of functional mitral regurgitation in cardiac resynchronization therapy. *Heart Rhythm* 2018;15:1816-22.
37. Ducharme A, Swedberg K, Pfeffer MA, et al. Prevention of atrial fibrillation in patients with symptomatic chronic heart failure by candesartan in the Candesartan in Heart failure: Assessment of Reduction in Mortality and morbidity (CHARM) program. *Am Heart J* 2006;151:985-91.
38. ACTIVE I Investigators, Yusuf S, Healey JS, et al. Irbesartan in patients with atrial fibrillation. *N Engl J Med* 2011;364:928-38.
39. Pitt B, Pfeffer MA, Assmann SF, et al. Spironolactone for heart failure with preserved ejection fraction. *N Engl J Med* 2014;370:1383-92.
40. Solomon SD, Zile M, Pieske B, et al. The angiotensin receptor neprilysin inhibitor LCZ696 in heart failure with preserved ejection fraction: phase 2 double-blind randomised controlled trial. *Lancet* 2012;380:1387-95.
41. Van Gelder IC, Groenveld HF, Crijns HJGM, et al. Lenient versus strict rate control in patients

- with atrial fibrillation. *N Engl J Med* 2010;362:1363-73.
42. Wyse DG, Waldo AL, DiMarco JP, et al. A comparison of rate control and rhythm control in patients with atrial fibrillation. *N Engl J Med* 2002;347:1825-33.
43. Osranek M, Bursi F, Bailey KR, et al. Left atrial volume predicts cardiovascular event(s) in patients originally diagnosed with lone atrial fibrillation: three-decade follow-up. *Eur Heart J* 2005;26:2556-61.
44. Dell'Era G, Rondano E, Franchi E, Marino PN. Atrial asynchrony and function before and after electrical cardioversion for persistent atrial fibrillation. *Eur J Echocardiogr* 2010;11:577-83.
45. Reddy ST, Belden W, Doyle M, et al. Mitral regurgitation recovery and atrial reverse remodeling following pulmonary vein isolation procedure in patients with atrial fibrillation: a clinical observation proof-of-concept cardiac MRI study. *J Interv Card Electrophysiol* 2013;37:307-15.
46. Zhao L, Jiang W, Zhou L, et al. The role of valvular regurgitation in catheter ablation outcomes of patients with long-standing persistent atrial fibrillation. *Europace* 2014;16:848-54.
47. Piccini JP, Allen LA. Heart failure complicated by atrial fibrillation: don't bury the beta-blockers just yet. *J Am Coll Cardiol HF* 2017;5:107-9.
48. Machino-Ohtsuka T, Seo Y, Ishizu T, et al. Efficacy, safety, and outcomes of catheter ablation of atrial fibrillation in patients with heart failure with preserved ejection fraction. *J Am Coll Cardiol* 2013;62:1857-65.
49. Van Gelder IC, Crijns HJGM, Tieleman RG, et al. Chronic atrial fibrillation: success of serial cardioversion therapy and safety of oral anticoagulation. *Arch Intern Med* 1996;156:2585-92.
50. Packer DL, Mark DB, Robb RA, et al. Catheter Ablation versus Antiarrhythmic Drug Therapy for Atrial Fibrillation (CABANA) trial: study rationale and design. *Am Heart J* 2018;199:192-9.
51. Bax JJ, Braun J, Somer ST, et al. Restrictive annuloplasty and coronary revascularization in ischemic mitral regurgitation results in reverse left ventricular remodeling. *Circulation* 2004;110:103-9.
52. Acker MA, Parides MK, Perrault LP, et al. Mitral-valve repair versus replacement for severe ischemic mitral regurgitation. *N Engl J Med* 2014;370:23-32.
53. Hung J, Papakostas L, Tahta SA, et al. Mechanism of recurrent ischemic mitral regurgitation after annuloplasty: continued LV remodeling as a moving target. *Circulation* 2004;110:85-91.
54. Kihara T, Gillinov AM, Takasaki K, et al. Mitral regurgitation associated with mitral annular dilation in patients with lone atrial fibrillation: an echocardiographic study. *Echocardiography* 2009;26:885-9.
55. Takahashi Y, Abe Y, Sasaki Y, et al. Mitral valve repair for atrial functional mitral regurgitation in patients with chronic atrial fibrillation. *Interact Cardiovasc Thorac Surg* 2015;21:163-8.
56. Schueler R, Momcilovic D, Weber M, et al. Acute changes of mitral valve geometry during interventional edge-to-edge repair with the MitraClip system are associated with midterm outcomes in patients with functional valve disease: preliminary results from a prospective single-center study. *Circ Cardiovasc Interv* 2014;7:390-9.
57. Dal-Bianco JP, Aikawa E, Bischoff J, et al. Myocardial infarction alters adaptation of the tethered mitral valve. *J Am Coll Cardiol* 2016;67:275-87.
58. Grande-Allen KJ, Barber JE, Klatka KM, et al. Mitral valve stiffening in end-stage heart failure: evidence of an organic contribution to functional mitral regurgitation. *J Thorac Cardiovasc Surg* 2005;130:783-90.
59. Bartko PE, Dal-Bianco JP, Guerrero JL, et al. Effect of losartan on mitral valve changes after myocardial infarction. *J Am Coll Cardiol* 2017;70:1232-44.
60. Iborra-Egea O, Gálvez-Montón C, Roura S, et al. Mechanisms of action of sacubitril/valsartan on cardiac remodeling: a systems biology approach. *Syst Biol Appl* 2017;3:1-8.

KEY WORDS atrial fibrillation, functional mitral regurgitation, heart failure with preserved ejection fraction, mitral annular dilatation, mitral annulus, secondary mitral regurgitation

