Does Mitral Valve Calcium in Patients Undergoing Mitral Valve Replacement Portend Worse Survival?

Nishant Saran, MBBS, Kevin L. Greason, MD, Hartzell V. Schaff, MD, Sertac M. Cicek, MD, Richard C. Daly, MD, Simon Maltais, MD, John M. Stulak, MD, Alberto Pochettino, MD, Katherine S. King, MS, Joseph A. Dearani, MD, and Sameh M. Said, MD

Department of Cardiovascular Surgery, and Division of Biomedical Statistics and Informatics, Mayo Clinic, Rochester, Minnesota

Background. Mitral annular calcification (MAC) is associated with worse outcomes after mitral valve replacement (MVR). With limited data available on long-term outcomes, we reviewed our experience of MVR in presence of MAC.

Methods. A retrospective review of 1,710 consecutive patients who underwent MVR between January 2000 and December 2015 was performed. Patients with isolated primary MVR (n = 496) were included, whereas patients with concomitant cardiac surgery (n = 1,068), previous MVR (n = 110), and mitral valve (MV) endocarditis (n = 36) were excluded. MV calcification was classified as MAC present in anterior/posterior annulus and vertically at the level of leaflets/subvalvular apparatus. A conservative approach towards annular debridement was followed.

Results. Our sample's mean age was 64.4 ± 14.1 years, and included 279 (56%) women. MV calcification was observed in 169 (34%) patients with MAC in 115 (23%). Older age, higher ejection fraction, peripheral vascular disease, diabetes, dialysis, and previous aortic valve surgery were associated with increased prevalence of MAC. Patients with MV calcification had higher stroke rate ($p = 0.040$), patients with anterior leaflet and commissural calcification had higher pacemaker implantation ($p = 0.010$, $p = 0.001$, respectively), and patients with circumferential MAC had higher postoperative dialysis ($p = 0.006$). Operative mortality was not significantly different ($p = 0.466$) between MAC (n = 1, 1%) and non-MAC (n = 9, 2%) patients. MAC was associated with late mortality (unadjusted hazard ratio, 1.62; 95% confidence interval, 1.20 to 2.18), though on multivariable analysis age, diabetes, dialysis, hypertension, previous aortic valve surgery, previous coronary artery bypass grafting, and MVR with a bioprosthetic valve were found to be independent risk factors for mortality whereas MAC was not.

Conclusions. A conservative approach to treat MAC achieves satisfactory results. Patients with MAC have significant comorbidities contributing to a worse survival, though MAC in itself is not a risk factor for mortality.

(Ann Thorac Surg 2019;107:444–52)

Calcification of the mitral valve apparatus is often seen during mitral valve (MV) surgery and has been known to increase its complexity [1–3]. This can occur on an annular level (mitral annular calcification [MAC]) and/or vertical (leaflet or subvalvular apparatus) level [4]. MAC is a chronic degenerative process that involves the fibrous skeleton supporting the MV [3–5]. It is associated with advanced age, female sex, and increased risk of cardiovascular disease, morbidity, and mortality [6–9].

Dr Daly discloses a financial relationship with Neochord, Inc.

The Videos can be viewed in the online version of this article [https://doi.org/10.1016/j.athoracsur.2018.07.098] on http://www.annalsthoracicsurgery.org.

Accepted for publication July 24, 2018.

Presented at the Sixty-fourth Annual Meeting of the Southern Thoracic Surgical Association, San Antonio, TX, Nov 8–11, 2017.

Address correspondence to Dr Saran, Department of Cardiovascular Surgery, Mayo Clinic, 200 First St SW, Rochester, MN 55905; email: saran.nishant@mayo.edu.

Published by Elsevier Inc.

0003-4975/$36.00
https://doi.org/10.1016/j.athoracsur.2018.07.098

These patients present with increased MV dysfunction, arrhythmias, and increased systemic atherosclerosis [1, 2, 5, 10]. MV surgery in the presence of MAC is associated with worse prognosis [1, 4, 11]. There are limited data on long-term outcomes of patients with MAC who receive mitral valve replacement (MVR). Our objectives in this study were to describe the prevalence and perioperative characteristics of MAC in patients operated upon for isolated primary MVR and to evaluate the perioperative and long-term outcomes in these patients.

Patients and Methods

We retrospectively analyzed the charts of 1,710 consecutive patients who underwent MVR between January 2000 and December 2015. The study was approved by the institutional review board at Mayo Clinic (Rochester, MN). Patients with isolated primary MVR (n = 496) were included, whereas patients with concomitant cardiac surgery (n = 1,068), previous MVR (n = 110), and active MV endocarditis (n = 36) were excluded. Baseline patient characteristics were obtained from review of electronic medical record and were reported based on definitions set forth by The Society of Thoracic Surgeons Adult Cardiac Database [12].

Operative notes were reviewed to ascertain the degree of calcification of the MV, and the following classification was used. At the horizontal (annular) level, calcium was present either at the anterior annulus, posterior annulus, commissures, and/or circumferentially. At the vertical level (leaflet and subvalvular apparatus) calcium was present at the anterior leaflet, posterior leaflet, subvalvular apparatus, and/or left ventricle myocardium. In order to address the subjective nature of operative reports, coronary angiograms were also reviewed, if available (n = 480) (Videos 1 and 2), to grade MV calcification. The operative report and coronary angiogram findings matched in 96% of the patients with a Cohen's kappa coefficient of 0.937 and, in the remaining 4%, the calcification was usually found to be more extensive in the coronary angiograms. The coronary angiograms were limited by the evaluation of calcification only at a horizontal level as vertical extent was difficult to gauge. Because of a near complete overlap of findings and a limitation of coronary angiograms with regard to vertical extent of calcification, operative reports were used to define calcification in this study.

Operative Approach

Patients either received a mechanical (n = 268, 54.0%) or a tissue (n = 228, 46.0%) prosthetic valve. MVR was performed using interrupted braided pledgeted sutures placed through the mitral valve annulus. In most MVRs, a conservative operative approach was followed. The annulus was debrided and decalcified to the safe extent possible to allow an adequately sized prosthesis to fit, without compromising the integrity of the atrioventricular groove or increasing the risk of injury to the circumflex coronary artery or conduction tissues in/near the areas of the fibrous trigones. Annulopapillary

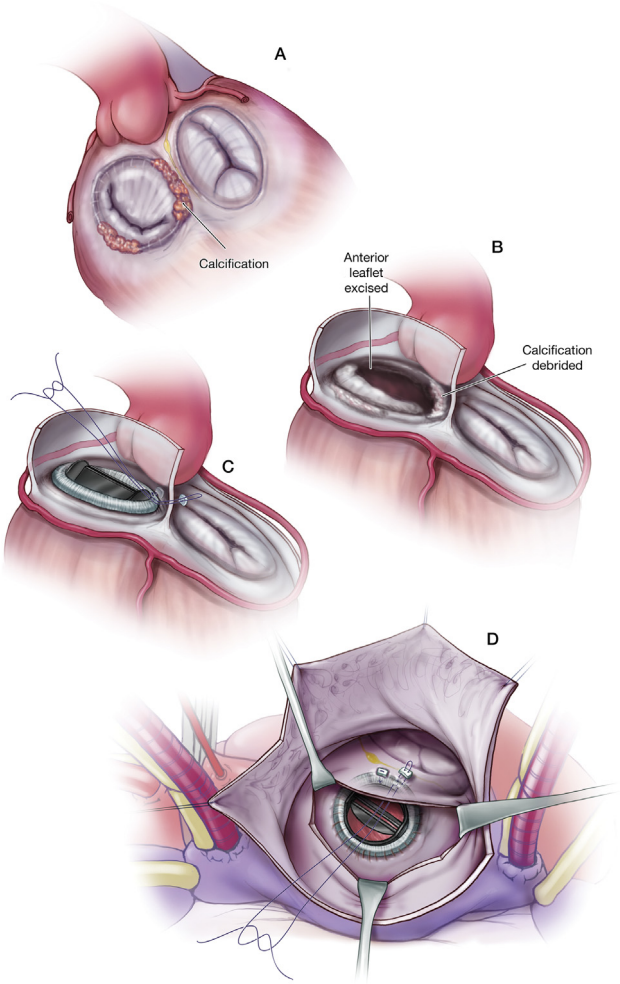

Fig 1. (A) If mitral annular calcification is present towards the interatrial septum, (B) post annular debridement, (C) it can be approached from the right atrial side of the interatrial septum, (D) being aware of the conduction bundle and atrioventricular node (yellow color in the illustration).

continuity was maintained by saving as much subvalvular apparatus as possible to decrease the risk of atrioventricular groove disruption. Calcified and thickened leaflet areas were excised. Pliable posterior leaflet was incorporated into the pledgeted sutures and anterior leaflet was excised in most cases, though in some cases they were imbricated within the sutures. In a few patients, where extensive debridement was performed, the annulus was reconstructed using a bovine pericardial patch (n = 2) and/or suture reconstruction of annulus with interrupted pledgeted mattress sutures approximating the left atrial wall to annulus (n = 1). In the 2 patients with patch reconstruction, artificial chords were placed connecting the neoannulus to papillary muscles. In some patients with a more extensive degree of calcifications, valvular sutures were placed from the right atrial side of the interatrial septum avoiding the conduction tissue (n = 3) (Fig 1) and/or from the aortic side (n = 2) (Fig 2) to minimize the risk of periprosthetic leak. When calcium

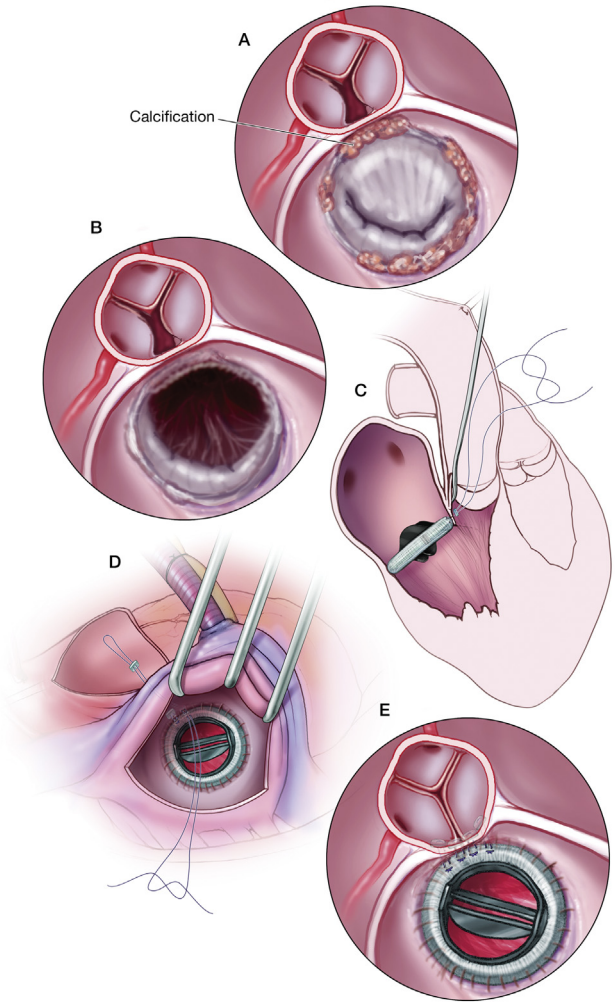

Fig 2. (A) If mitral annular calcification is located in the anterior annulus at the aortomitral curtain, (B) post annular debridement, (C) sutures can be placed through an aortotomy, (D, E) with pledgeted sutures passing below the aortic annulus into the mitral prosthesis sewing ring.

was deemed too extensive to place any sutures, patients underwent direct transatrial MVR using a modified balloon-expandable Edwards-Sapien valve (n = 3, direct transatrial access, Fig 3) [13].

Statistical Analysis

Clinical features were described with mean (standard deviation) or median (interquartile range) as appropriate for continuous variables and number (percentage) for categorical variables. Associations of baseline characteristics and MAC were assessed with logistic regression. Cox models were used to determine independent baseline and calcification factors associated with mortality. Multivariable models were developed using purposeful selection with the additional inclusion of etiological variables, testing all pairwise interactions, and assessing linearity using splines. The proportional hazard assumption was checked for each variable in the multivariable Cox model using the score test and visually with the Schoenfeld residuals. Rates of long-term mortality and reoperation were estimated with Kaplan-Meier methods and mortality follow up was estimated with the reverse Kaplan-Meier estimate. An alpha level of 0.05 was used to determine statistical significance and all analyses were carried out in SAS version 9.4 (SAS Institute Inc, Cary, NC).

Results

Mean age of the study group was 64.4 ± 14.1 years and 279 (56%) were women. Calcification of MV was seen in 169 (34%) patients. MAC was present in 115 (23%) patients. In patients with MAC, posterior annular calcification (n = 91, 80%) was most common, followed by commissural (n = 62, 54%), anterior annular (n = 36, 31%), and circumferential calcification (n = 26, 23%). Vertically, 120 (24%) patients had leaflet/subvalvular calcification. Posterior leaflet calcification (n = 102, 85%) was the most common, followed by anterior leaflet calcification (n = 82, 68%), calcification of adjacent left ventricle myocardium (n = 9, 8%) and calcification of the subvalvular apparatus (n = 6, 5%) (Fig 4).

Baseline associations with MAC are shown in Table 1 (Univariate logistic regression). There were significantly more patients with stenosis in the MAC group. A multivariable analysis (Table 2) found that older age, higher ejection fraction, peripheral vascular disease, diabetes, dialysis, and previous aortic valve surgery were independently associated with higher odds of MAC, and previous MV repair and presence of significant mitral regurgitation were less likely in patients with MAC.

Operative and Early Outcomes

Operative and early outcomes of patients with and without MAC are shown in Table 3. Patients with MAC had a higher incidence of postoperative periprosthetic leak ($p = 0.001$), though only 4 patients (4%) had significant periprosthetic leak at discharge. Patients with MV calcification had a higher stroke rate (n = 4, 2%, $p = 0.048$) post-surgery. When looking at patients with horizontal level calcification, those with circumferential MAC required more postoperative dialysis (n = 3, 12%, $p = 0.006$) and those with commissural calcification had higher rates of permanent-pacemaker/automated implantable cardioverter-defibrillator (AICD) implantation (n = 8, 13%, $p < 0.001$).

In patients with vertical calcification, those with anterior leaflet calcification had higher pacemaker/AICD implantation (n = 8, 10%, $p = 0.016$). We did not find any significant difference in early mortality, renal failure/dialysis, or stroke rate between patients with and without vertical calcification.

Follow-Up and Long-Term Outcome

The median follow-up time was 7.75 (interquartile range, 1.21 to 13.46) years with maximum follow-up of 17.55 years. There were a total of 15 MV reoperations, with

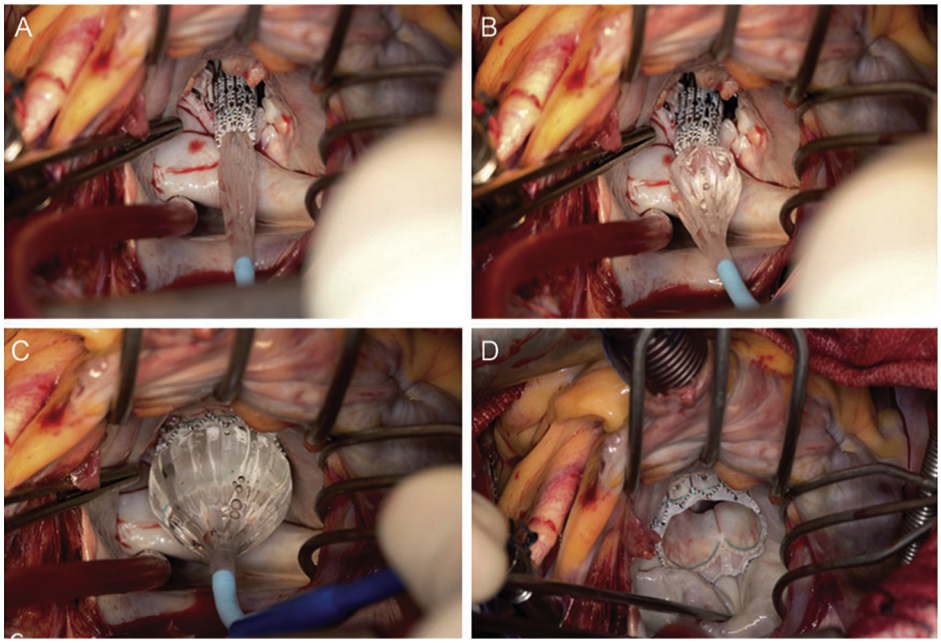

Fig 3. Direct transatrial balloon-expandable SAPIEN valve implantation in a patient with severe mitral annular calcification. (A) Mitral valve is visualized and balloon expandable valve is delivered and positioned across the valve. (B, C) Valve is deployed. (D) Final result directly visualized. (Reprinted from El Sabbagh and colleagues [13] with permission from The European Association for Cardio-Thoracic Surgery.)

incidence of reoperation at 1 and 10 years being 0.5% and 5.7%, respectively. Reoperation rates for patients with MAC were 0.0% and 4.4% at 1 and 10 years, respectively (Fig 5). Reoperation due to peri-prosthetic leak took place in 2 patients (1 each in MAC and non-MAC patients). There were 4 patients who needed a subsequent transcatheter closure of periprosthetic leak (3 in MAC and 1 in non-MAC patients).

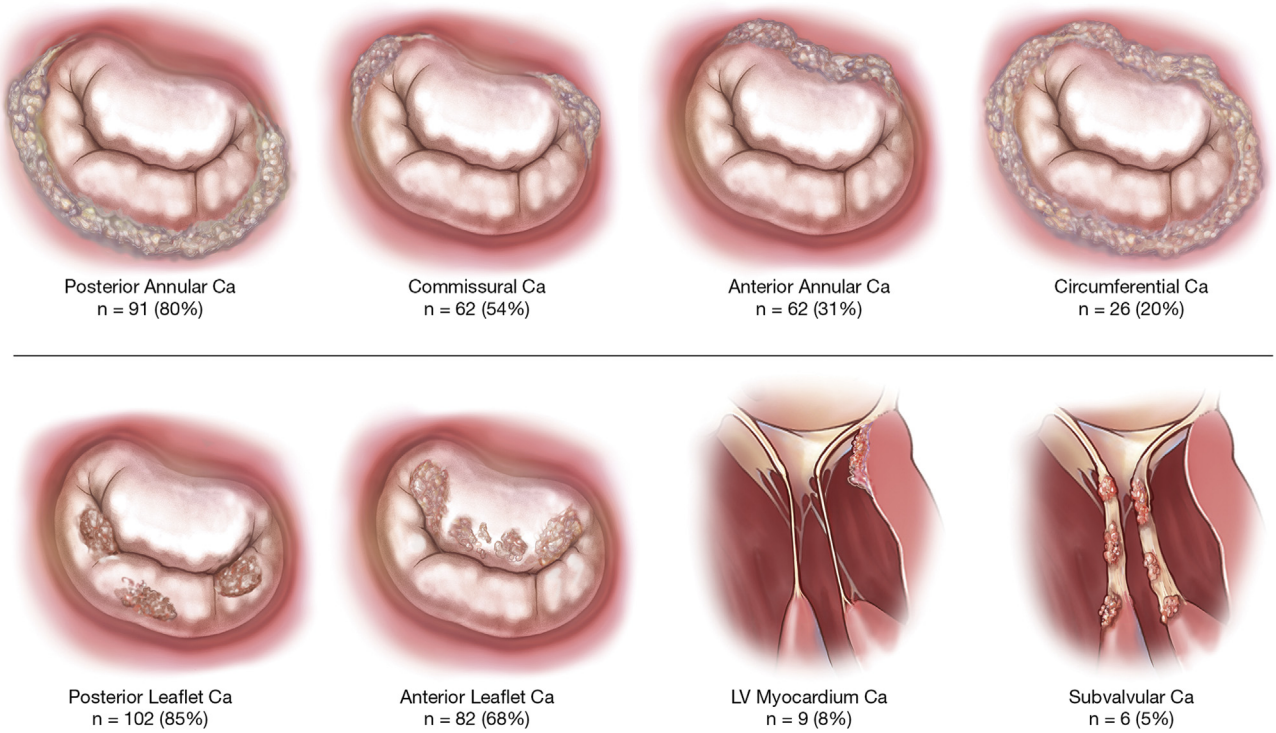

Fig 4. Mitral valve calcification. (Top row) Horizontal level calcification (mitral annular calcification). (Bottom row) Vertical level calcification. (Ca = calcification; LV = left ventricle.)

Table 1. Baseline Characteristics (MAC Versus Rest)

Preoperative Characteristics	MVR Without MAC (n = 381)	MVR With MAC (n = 115)	*p* Value
Age at surgery, years, mean (SD)	62.8 (14.3)	69.9 (11.8)	<0.001
Ejection fraction, %, mean (SD)	57.3 (11.8)	61.2 (9.1)	0.002
Body mass index, kg/m^2, mean (SD)	28.1 (6.0)	29.1 (7.4)	0.173
Female sex, n (%)	201 (52.8)	78 (67.8)	0.005
Smoking status, n (%)			0.102
Never	145 (38.1)	46 (40.0)	
Former	137 (36.0)	40 (34.8)	
Current	43 (11.3)	5 (4.3)	
Unknown	56 (14.7)	24 (20.9)	
Diabetes, n (%)	58 (15.2)	31 (27.0)	0.005
Dyslipidemia, n (%)	260 (68.2)	84 (73.0)	0.328
Renal failure, n (%)	10 (2.6)	12 (10.4)	<0.001
Dialysis, n (%)	2 (0.5)	5 (4.3)	0.011
Chronic lung disease, n (%)	61 (16.0)	29 (25.2)	0.026
Peripheral vascular disease, n (%)	19 (5.0)	14 (12.2)	0.009
Cerebrovascular accident, n (%)	32 (8.4)	12 (10.4)	0.502
Previous myocardial infarction, n (%)	45 (11.8)	14 (12.2)	0.916
Hypertension, n (%)	224 (58.8)	75 (65.2)	0.218
Coronary artery disease, n (%)	122 (32.1)	46 (40)	0.118
Ejection fraction < 40%, n (%)	36 (9.7)	3 (2.7)	0.026
Non-elective surgery, n (%)	43 (11.3)	10 (8.7)	0.432
Previous cardiac surgery, n (%)	187 (49.1)	36 (31.3)	<0.001
Previous aortic valve surgery, n (%)	35 (9.2)	23 (20)	0.002
Previous mitral valve repair, n (%)	133 (34.9)	14 (12.2)	<0.001
Previous tricuspid valve surgery, n (%)	8 (2.1)	3 (2.6)	0.746
Previous coronary artery bypass grafting, n (%)	82 (21.5)	17 (14.8)	0.115
Degenerative etiology, n (%)	86 (23)	34 (30)	0.125
Rheumatic etiology, n (%)	136 (36)	42 (37)	0.871
Ischemic etiology, n (%)	33 (9)	3 (3)	0.028
Myxomatous etiology, n (%)	148 (39)	42 (37)	0.653
Other etiology, n (%)	226 (59)	41 (36)	<0.001
Mitral stenosis, n (%)	158 (41.5)	65 (56.5)	0.005
Mitral regurgitation, n (%)			<0.001
None	2 (0.5%)	5 (4.3%)	
Trivial/trace	10 (2.6)	9 (7.8)	
Mild	37 (9.7)	20 (17.4)	
Moderate	58 (15.2)	17 (14.8)	
Severe	274 (71.9)	64 (55.7)	

p values are from univariate logistic regression predicting mitral annular calcification (MAC).

MVR = mitral valve replacement.

Patients with MAC had significantly worse survival (unadjusted hazard ratio [HR], 1.62; 95% confidence interval, 1.20 to 2.18; $p = 0.002$) with 1-, 5-, and 10-year survival as 87.8%, 61.2%, and 35.2%, respectively (Fig 6). In multivariable analysis, independent risk factors of mortality for the whole study group were older age, diabetes, dialysis, hypertension, previous aortic valve surgery, previous coronary artery bypass grafting, and MVR with a bioprosthetic valve. MAC was not found to be an independent risk factor for mortality, with a HR of 1.3 ($p = 0.10$) (Fig 7).

Comment

This study, involving a cohort of isolated primary MVR, found the prevalence of MAC at 23%. Older age, higher ejection fraction, peripheral vascular disease, diabetes, dialysis, and previous aortic valve surgery were associated with increased prevalence of MAC. Patients with MAC had worse survival, though MAC itself was not found to be an independent predictor of late mortality.

The reported prevalence of MAC in the general population is between 8% and 15% [6, 14–16]. MAC was

Table 2. Multivariable Analysis: Baseline Characteristics Predicting MAC

Effect	Reference	Odds Ratio	Wald 95% Confidence Limits		*p* Value
Age	1 year	1.051	1.029	1.073	<0.001
Ejection fraction	1%	1.035	1.008	1.062	0.010
Sex	Male vs female	0.702	0.405	1.217	0.208
Diabetes	Yes vs no	2.043	1.138	3.665	0.017
Dialysis	Yes vs no	16.727	2.699	103.657	0.003
Peripheral vascular disease	Yes vs no	2.995	1.270	7.064	0.012
Previous aortic valve surgery	Yes vs no	3.375	1.611	7.068	0.001
Previous mitral valve repair	Yes vs no	0.252	0.124	0.514	<0.001
Mitral regurgitation					0.005
Trivial/trace vs none	0.228	0.027	1.904	0.172	
Mild vs none	0.088	0.013	0.596	0.013	
Moderate vs none	0.074	0.011	0.497	0.007	
Severe vs none	0.056	0.009	0.353	0.002	

MAC = mitral annular calcification.

present in 23% of our patients. This is higher than the Japanese series [17] in which only 7.2% of the MVRs had evidence of MAC. This may be reflective of ethnic differences in the prevalence of MAC, as brought out by the Multi-Ethnic Study of Atherosclerosis [6, 9] with a much higher prevalence of MAC reported in white patients.

The Multi-Ethnic Study of Atherosclerosis found the baseline preoperative characteristics of age, female sex, diabetes, and body mass index to be significantly associated with MAC [6].

The present study also found age and diabetes to be associated with MAC. Female sex, though associated univariately, was not associated with MAC on multivariable analysis.

This study did not find any association between coronary artery disease, previous myocardial infarction,

Table 3. Operative and Early Outcomes (MAC Versus Rest)

Operative and Postoperative Outcomes	MVR Without MAC (n = 381)	MVR With MAC (n = 115)	*p* Value
Cross-clamp time, minutes, median (IQR)	48 (37–64)	54 (40–78)	0.004[a]
Bypass Times, minutes, median (IQR)	69 (53–95)	82 (54–108)	0.040[a]
Intraoperative, TEE, periprosthetic leak, n (%)			<0.001[b]
Missing	5	4	
Mild	18 (5)	18 (16)	
Moderate	0 (0)	3 (3)	
None	358 (95)	90 (81)	
At discharge, TTE, periprosthetic leak, n (%)			0.001[b]
Missing	27	11	
Indeterminate	1 (0)	2 (2)	
Mild	10 (3)	7 (7)	
Moderate	1 (0)	4 (4)	
None	342 (97)	91 (88)	
Hospital stay, days, median (IQR)	7 (5–8)	7 (6–9)	0.019[a]
New dialysis required, n (%)	8 (2)	6 (5)	0.077[c]
Permanent pacemaker/automated implantable cardioverter-defibrillator, n (%)	15 (4)	8 (7)	0.177[c]
Stroke - permanent, n (%)	4 (1)	1 (1)	1.000[b]
Stroke - transient ischemic attack, n (%)	2 (1)	0 (0)	1.000[b]
Reoperation for bleeding, n (%)	9 (2)	5 (4)	0.331[b]
Atrioventricular groove disruption, n (%)	3 (1)	0 (0)	1.000[b]
Operative mortality, n (%)	9 (2)	1 (1)	0.466[b]

[a] Wilcoxon test. [b] Fisher exact test. [c] Chi-square test.

IQR = interquartile range; MAC = mitral annular calcification; MVR = mitral valve replacement; TEE = transesophageal echocardiogram; TTE = transthoracic echocardiogram.

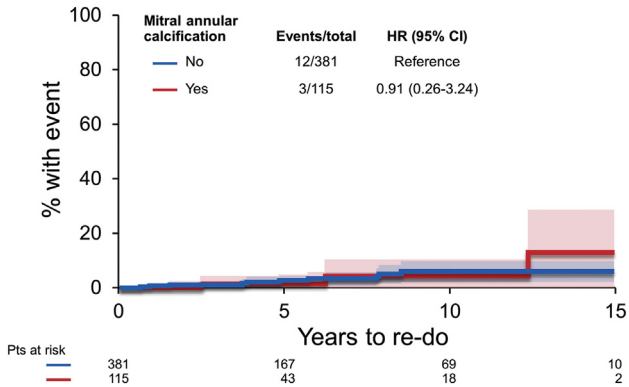

Fig 5. Mitral valve reoperation. (CI = confidence interval; HR = hazard ratio; Pts = patients.)

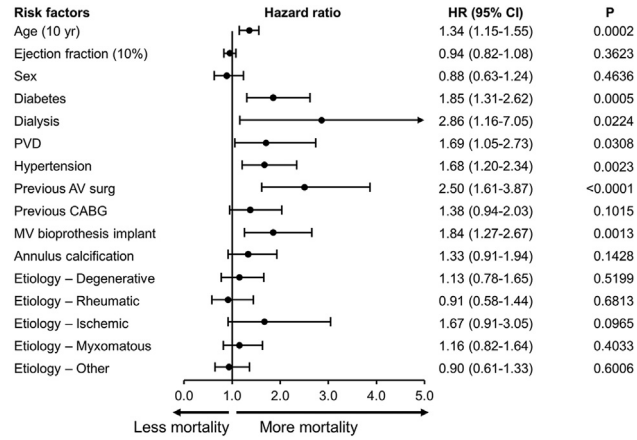

Fig 7. Forest plot, independent risk factors for mortality in entire study cohort (multivariable analysis). (AV = aortic valve surgery; CABG = coronary artery bypass grafting; CI = confidence interval; HR = hazard ratio; PVD = peripheral vascular disease.)

or dyslipidemia and MAC, though we did find peripheral vascular disease as an independent predictor for MAC.

Chronic renal failure has been associated with MAC [16, 18]. There is some evidence that altered calcium–phosphorous metabolism due to chronic kidney disease predisposes to MAC [16, 19]. This is consistent with our findings as preoperative renal failure and dialysis were found to be associated with MAC.

Abudiab and colleagues found patients with more severe MAC to have higher ejection fraction [20]. This correlates with our finding of higher left ventricular ejection fraction in MAC patients. This likely indicates the association of MAC with diastolic dysfunction with preserved left ventricle function, as compared with non-MAC patients, who were associated with more significant mitral regurgitation and left-sided systolic heart failure. Some studies have found aortic stenosis, hypertrophic cardiomyopathy, and hypertension to be associated with MAC [3–5]. Altered left-ventricle systolic pressure in such patients increases MV stress, which contributes to annular tension and degeneration [3]. In this study, previous aortic valve surgery was significantly associated with MAC possibly because of this altered MV stress.

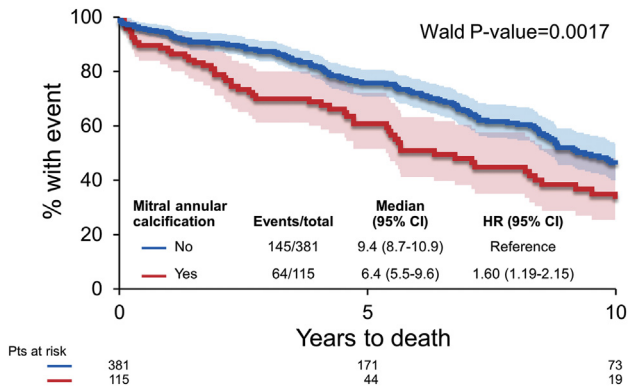

Fig 6. Kaplan-Meier survival curves: MAC versus non-MAC. (CI = confidence interval; HR = hazard ratio; MAC = mitral annular calcification; Pts = patients.)

In operative outcome, postoperative heart block and need for permanent pacemaker has been found in 8% to 25% of patients with MAC [11, 17]. In this study, patients with anterior leaflet and commissural calcification had increased pacemaker/AICD implantation, though patients with MAC as a whole did not. This could be explained by increased chances of encroaching upon the conduction area in such patients either during debridement of annulus or placement of stitches. Postoperative renal failure has been reported in 2% to 5% of patients with MAC [11, 17]. In this study, no significant increase in postoperative dialysis was seen in MAC patients, though patients with circumferential MAC had an increased incidence ($p = 0.006$) of postoperative new dialysis. This could be reflective of the more severe nature of disease in this specific subset of patients.

Studies including those involving extensive annular reconstruction have found postoperative stroke rates ranging from 3.5% to 5.5% [11, 17]. In the present study, stroke rate in MAC patients was 1%, which was not significantly different from non-MAC patients. Nevertheless, we did find significantly higher postoperative stroke in the larger subset of patients with any MV calcification (2%, $p = 0.048$). This could be due to embolization of calcium debris post-debridement of the annulus/valvular apparatus. It is therefore imperative to irrigate the field extensively with saline to ensure that no loose calcium debris is left behind.

In the current era, operative mortality for isolated MVR is between 1% and 6% [21, 22]. MAC has been associated with increased perioperative morbidity and mortality, with early mortality ranging from 9% to 28% [11, 23, 24]. Most of these studies either involved extensive patch reconstruction of the annulus [11, 23] or no debridement of the annulus with sutures placed around the calcified annulus [24]. With the increased mortality

and the complexity of such surgery, surgeons have also developed alternate solutions to treat such patients. Use of ultrasonic debridement of MV calcification [25], intraatrial placement of MV prosthesis [26], and patch-glue annular reconstruction [27] have been described. There are limited data, however, about a more conservative approach involving debridement of annulus as needed to place a sufficiently-sized prosthesis without compromising atrioventricular groove integrity, injuring the coronary artery, or encroaching upon the conduction area [28]. Nezic and associates [29] have described a technique of MVR with posterior transposition of anterior leaflet to help cover and buttress the partially decalcified posterior annulus. Coselli and Crawford [30] suggested the securing of the MV prosthesis to leaflet tissue without sacrificing the subvalvular apparatus, although this came with the evident drawback of MVR with a smaller prosthesis. This study with a conservative operative approach found no difference in operative mortality between patients with and without MAC. The increased cross-clamp and bypass times seen in patients with MAC in this study is reflective of the time needed to debride/decalcify the annulus and the increased complexity of surgery in such patients.

In patients with MAC, there is a concern about periprosthetic leak and the subsequent risk of reoperations [1]. Fiendel and colleagues [11] saw only 4 reoperations in their study with extensive annular reconstruction, and none because of periprosthetic leak. In the present study, although there was an increased incidence of significant periprosthetic leak at discharge in MAC patients compared with non-MAC patients (4%, $p = 0.001$), only 3 reoperations took place in MAC patients (which included 1 due to periprosthetic leak). Transcatheter closure of periprosthetic leak was successfully performed in 3 other patients in the MAC group, suggesting that transcatheter options remain a viable tool to manage residual periprosthetic leak in these otherwise difficult-to-treat patients. This also emphasizes that patients who have residual periprosthetic leak need to have an informed follow-up. In patients with more extensive calcification, we have also developed alternate strategies of valvular suture placement, such as from the right atrial and/or the aortic side (as described in Figs 1 and 2), in particular to counter the risk of periprosthetic leak.

In situations when calcification is too extensive to adopt a conservative approach, alternative solutions like transcatheter MVR [13, 31] or bypass of a stenosed and heavily calcified MV with a left atrial to left ventricular valved conduit [32] have been sought. Our experience with transcatheter MVR has shown that it is a viable solution for these otherwise difficult-to-treat patients, with gratifying early results [13, 31]. An evolving transcatheter technology should make this approach even more attractive in the near future [31, 33].

Data on long term survival of patients with MAC post MVR are limited. In this study, the 1-, 5-, and 10-year survival of MAC patients post MVR was 87.8%, 61.2%, and 35.2%, respectively. Fiendel and colleagues reported similar survival (65% ± 8% at 8 years), though a large number of the patients (n = 12 of 54) received MV repair [11]. Uchimuro and associates [17] reported a survival of 75.6% ± 6% at 5 years (57 replacements, 4 repairs); however, the patient population differed significantly from our study. Only 3.6% of the MVRs in the Uchimuro and colleagues study had a previous aortic valve surgery, whereas 20% of MAC patients in this study had a previous aortic valve surgery. This assumes greater importance, as previous aortic valve surgery besides age, diabetes, dialysis, hypertension, previous coronary artery bypass grafting, and MVR with a bioprosthetic valve were identified as independent risk factors for mortality in our study. The worse survival (unadjusted HR, 1.6) seen in MAC patients in the present study appears to be due to increased comorbidities (older age, diabetes, dialysis, peripheral vascular disease, and previous aortic valve surgery) present in MAC patients. MAC in itself was not found to be an independent risk factor for mortality.

Limitations

This study is a retrospective analysis in a highly selected group of patients in a single institution. The analysis involving incidence and associations for MAC may therefore be subject to selection bias. This was a compromise to achieve the more precise objective of evaluating MAC in patients requiring MVR. We also acknowledge our inability to accurately distinguish rheumatic from degenerative MV disease in this study. The assessment of MV calcification is based on the surgeon's operative note and is therefore subjective in nature. We also acknowledge that there would be patients who might have developed periprosthetic leak, and not required a reoperation, which we have not been able to account for. Last but not least, this study includes MVR done by more than 1 surgeon and hence the approach to annular debridement and preservation of leaflet/subvalvular apparatus might have been variable, though the principles followed were the same as outlined earlier.

Conclusion

Presence of MV calcification in patients receiving MV replacement is associated with increased perioperative morbidity. A conservative operative approach to treat MAC achieves satisfactory results. Presence of significant comorbidities in patients with MAC contributes to a worse survival, though MAC in itself is not a risk factor for mortality.

References

1. Okada Y. Surgical management of mitral annular calcification. Gen Thorac Cardiovasc Surg 2013;61:619–25.
2. O'Neal WT, Efird JT, Nazarian S, et al. Mitral annular calcification and incident atrial fibrillation in the Multi-Ethnic Study of Atherosclerosis. Europace 2015;17:358–63.
3. Abramowitz Y, Jilaihawi H, Chakravarty T, Mack MJ, Makkar RR. Mitral annulus calcification. J Am Coll Cardiol 2015;66:1934–41.
4. Carpentier AF, Pellerin M, Fuzellier JF, et al. Extensive calcification of the mitral valve anulus: pathology and surgical management. J Thorac Cardiovasc Surg 1996;111:718–29; discussion 729–30.

5. Nestico PF, Depace NL, Morganroth J, et al. Mitral annular calcification: clinical, pathophysiology, and echocardiographic review. Am Heart J 1984;107:989–96.
6. Kanjanauthai S, Nasir K, Katz R, et al. Relationships of mitral annular calcification to cardiovascular risk factors: the Multi-Ethnic Study of Atherosclerosis (MESA). Atherosclerosis 2010;213:558–62.
7. Fox CS, Vasan RS, Parise H, et al. Mitral annular calcification predicts cardiovascular morbidity and mortality: the Framingham Heart Study. Circulation 2003;107:1492–6.
8. Boon A, Lodder J, Cheriex E, et al. Mitral annulus calcification is not an independent risk factor for stroke: a cohort study of 657 patients. J Neurol 1997;244:535–41.
9. Elmariah S, Budoff MJ, Delaney JAC, et al. Risk factors associated with the incidence and progression of mitral annulus calcification: the Multi-Ethnic Study of Atherosclerosis. Am Heart J 2013;166:904–12.
10. Johnson RC, Leopold JA, Loscalzo J. Vascular calcification: pathobiological mechanisms and clinical implications. Circ Res 2006;99:1044–59.
11. Feindel CM, Tufail Z, David TE, Ivanov J, Armstrong S. Mitral valve surgery in patients with extensive calcification of the mitral annulus. J Thorac Cardiovasc Surg 2003;126:777–82.
12. The Society of Thoracic Surgeons. STS Adult Cardiac Surgery Database Data Specifications, Version 2.81, March 28, 2014. Available at https://www.sts.org/sites/default/files/documents/ACSD_DataSpecificationsV2_81.pdf. Accessed March 9, 2018.
13. El Sabbagh A, Eleid MF, Foley TA, et al. Direct transatrial implantation of balloon-expandable valve for mitral stenosis with severe annular calcifications: early experience and lessons learned. Eur J Cardiothorac Surg 2018;53:162–9.
14. Allison MA, Cheung P, Criqui MH, et al. Mitral and aortic annular calcification are highly associated with systemic calcified atherosclerosis. Circulation 2006;113:861–6.
15. Foley PW, Hamaad A, El-Gendi H, et al. Incidental cardiac findings on computed tomography imaging of the thorax. BMC Res Notes 2010;3:326.
16. Asselbergs FW, Mozaffarian D, Katz R, et al. Association of renal function with cardiac calcifications in older adults: the cardiovascular health study. Nephrol Dial Transplant 2009;24:834–40.
17. Uchimuro T, Fukui T, Shimizu A. Mitral valve surgery in patients with severe mitral annular calcification. Ann Thorac Surg 2016;101:889–95.
18. Fox CS, Larson MG, Vasan RS, et al. Crosssectional association of kidney function with valvular and annular calcification: the Framingham heart study. J Am Soc Nephrol 2006;17:521–7.
19. Umana E, Ahmed W, Alpert MA. Valvular and perivalvular abnormalities in end-stage renal disease. Am J Med Sci 2003;325:237–42.
20. Abudiab MM, Chebrolu LH, Schutt RC, Nagueh SF, Zoghbi WA. Doppler echocardiography for the estimation of left ventricular filling pressure in patients with mitral annular calcification. JACC Cardiovasc Imaging 2017;10:1411–20.
21. Gillinov AM, Cosgrove DM. Minimally invasive mitral valve surgery: mini-sternotomy with extended transseptal approach. Semin Thorac Cardiovasc Surg 1999;11:206–11.
22. O'Brien SM, Shahian DM, Filardo G, et al. Society of Thoracic Surgeons Quality Measurement Task Force. The Society of Thoracic Surgeons 2008 cardiac surgery risk models: part 2—isolated valve surgery. Ann Thorac Surg 2009;88:S23–42.
23. Cammack PL, Edie RN, Edmunds LH. Bar calcification of the mitral annulus. A risk factor in mitral valve operations. J Thorac Cardiovasc Surg 1987;94:399–404.
24. d'Alessandro C, Vistarini N, Aubert S, Acar C, Pavie A, Gandjbakhch I. Mitral annulus calcification: determinants of repair feasibility, early and late surgical outcome. Eur J Cardiothorac Surg 2007;32:596–603.
25. Baumgartner FJ, Pandya A, Omari BO, et al. Ultrasonic debridement of mitral calcification. J Card Surg 1997;12:240–2.
26. Gandjbakhch I, Lascar M, Pavie A, Cabrol C. Intra-atrial insertion of a prosthetic mitral valve. J Cardiovasc Surg (Torino) 1988;29:113–4.
27. Ruvolo G, Speziale G, Voci P, Marino B. "Patch-glue" annular reconstruction for mitral valve replacement in severely calcified mitral annulus. Ann Thorac Surg 1997;63:570–1.
28. Smedira NG. Mitral valve replacement with a calcified annulus. Oper Tech Thorac Cardiovasc Surg 2003;8:2–13.
29. Nezic D, Knezevic A, Borovic S, Jovic M. Mitral valve replacement with posterior transposition of the anterior mitral leaflet which covers and buttresses partially decalcified posterior mitral annular bed. Eur J Cardiothorac Surg 2012;41:1129–31.
30. Coselli JS, Crawford ES. Calcified mitral valve annulus: prosthesis insertion. Ann Thorac Surg 1988;46:584–6.
31. Eleid MF, Whisenant BK, Cabalka AK, et al. Early outcomes of percutaneous transvenous transseptal transcatheter valve implantation in failed bioprosthetic mitral valves, ring annuloplasty, and severe mitral annular calcification. JACC Cardiovasc Interv 2017;10:1932–42.
32. Said SM, Schaff HV. An alternate approach to valve replacement in patients with mitral stenosis and severely calcified annulus. J Thorac Cardiovasc Surg 2014;147:e76–8.
33. De Backer O, Piazza N, Banai S, et al. Percutaneous transcatheter mitral valve replacement: an overview of devices in preclinical and early clinical evaluation. Circ Cardiovasc Interv 2014;7:400–9.