

# Modern management of systolic anterior motion of the mitral valve

Michael Ibrahim, Christopher Rao, Hutan Ashrafian, Umar Chaudhry, Ara Darzi and Thanos Athanasiou\*

Department of Surgery and Cancer, Imperial College London, London, UK

\* Corresponding author. Department of Surgery and Cancer 10th Floor, Queen Elizabeth the Queen Mother (QEQM) Building St Mary's Hospital, London W2 1NY, UK. Tel: +44-20-33127651; e-mail: t.athanasiou@imperial.ac.uk (T Athanasiou).

Received 26 July 2011; received in revised form 25 October 2011; accepted 2 November 2011

## Summary

Systolic anterior motion (SAM) of the mitral valve (MV) can be a life-threatening condition. The SAM can result in severe left ventricular outflow tract obstruction and/or mitral regurgitation and is associated with an up to 20% risk of sudden death (which is substantially lower in hypertrophic cardiomyopathy (HCM)). The mechanisms of SAM are complex and depend on the functional status of the ventricle. The SAM can occur in the normal population, but is typically observed in patients with HCM or following MV repair. Echocardiography (2D, 3D and stress) has a central diagnostic role as the application of echocardiographic SAM predictors allows the incorporation of prevention techniques during surgery and post-operative SAM assessment. Cardiac magnetic resonance imaging has a special role in understanding the dynamic nature of SAM, especially in anatomically atypical hearts (including HCM). This article describes what the clinician needs to know about SAM ranging from pathophysiological mechanisms and imaging modalities to conservative (medical) and surgical approaches and their respective outcomes. A stepwise approach is advocated consisting of medical therapy, followed by aggressive volume loading and beta-adrenoceptor blockade. Surgery is the final option. The correct choice of surgical technique requires an understanding of the anatomical substrate of SAM.

**Keywords:** Mitral valve • Systolic anterior motion

## INTRODUCTION

Systolic anterior motion (SAM) describes the dynamic movement of the mitral valve (MV) during systole anteriorly towards the left ventricular outflow tract (LVOT). SAM was first documented by Termini *et al.* three-decades ago [1] and was initially considered to be specific to hypertrophic cardiomyopathy (HCM), but is now recognized to arise in any setting that alters the complex dynamic anatomy of the left ventricle. Although early reports identified LVOT obstruction (LVOTO) to occur in all cases of SAM, it is now understood that its presentation can vary from clinically silent disease to severe LVOTO with associated haemodynamic compromise.

In order to accurately address SAM, it is necessary to characterize its severity and understand its anatomical basis. A stepwise management protocol can then be initiated ranging from a conservative approach of ventricular loading, vasoconstriction and beta-adrenoceptor blockade to definitive surgical correction. The surgical management of SAM may consist of a single procedure or can be part of a wider intervention of ventricular remodelling that may include the removal of a subaortic membrane in subaortic stenosis or septal myectomy for HCM. SAM can also be minimized by prophylactic measures during MV repair surgery by the identification of high-risk patients based on echocardiographic factors.

Here, we review SAM in different clinical contexts and discuss its aetiology and pathophysiology. We describe its risk assessment and echocardiographic characterization. We discuss its management with respect to each cause: HCM, post-surgical SAM and medical causes of SAM. We divide our discussion into two broad areas: SAM secondary to HCM and other causes.

## SYSTOLIC ANTERIOR MOTION NOT DUE TO HYPERTROPHIC CARDIOMYOPATHY

### The incidence of systolic anterior motion

Data from the Framingham Study demonstrate that SAM is rarely seen in unoperated myxomatous MV disease regardless of the leaflet size. Consequently, the appearance of SAM after MV repair has been considered to be an iatrogenic effect [2]. After the initial description of SAM as a complication of MV repair by Termini *et al.* [1], many investigators reported its post-operative incidence to range between 1 and 16% [3–6] of mitral surgery patients. Large reports of mid- to long-term follow-up indicate that SAM is a relatively uncommon cause of late failure, occurring between 2 and 7% of patients [7, 8].

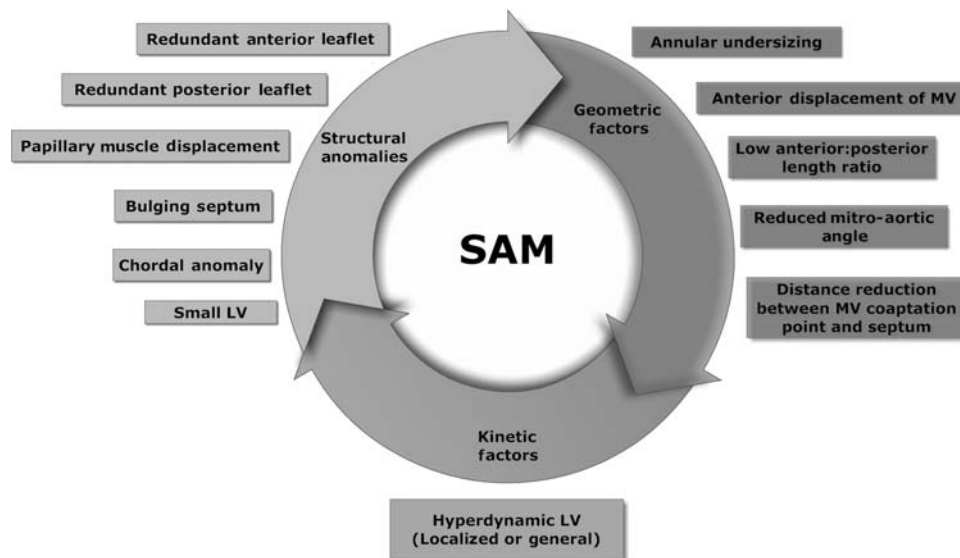


Figure 1: Factors predisposing to SAM. LV: left ventricle; MV: mitral valve.

## Patho-anatomical mechanisms of systolic anterior motion

The MV consists of the anterior and posterior leaflets, the annulus and the subvalvular apparatus of the papillary muscles and chordae tendinae. The function of MV depends on these structures, but also the global left ventricular (LV) structure and contractility. Changes in any element of this functional unit can predispose to or precipitate SAM. These are discussed in detail below and are summarized in Fig. 1.

**The role of the mitral leaflets.** A disruption of the dynamic unit of the mitral annulus and the MV leaflets can predispose to SAM. Excessive anterior or posterior leaflet tissue can predispose to SAM because they provide a large surface area on which drag forces act (resulting from the high flow of blood through the LVOT), drawing the MV anteriorly and towards the LV. They may also cause the MV coaptation point to move anteriorly towards the LVOT. Any anatomical or surgical translocation of the MV anteriorly will increase the forces acting to draw the MV anteriorly that may precipitate SAM. How such features actually result in SAM is not fully understood. It was thought that Venturi effect (which is the fluid pressure reduction at areas of stenosis, necessarily resulting from the need to increase the flow velocity) alone could account for SAM by means of a mitral-aortic angle of  $<15^\circ$ . However, anatomical studies have demonstrated a mitral-aortic angle closer to  $21^\circ$  in some cases of SAM, suggesting that the role of other factors involved in its pathogenesis. Drag forces are also thought to play a role. Charls [9] proposed that the Venturi effect may elevate the MV and that drag forces may move it anteriorly resulting in a synergistic mechanism to result in SAM. Experimental studies are required to assess this hypothesis.

He *et al.* [10] proposed that elongation of the anterior leaflet could be a mechanism for SAM and this is supported by echocardiographic evidence, showing that the anterior mitral leaflet (AML) height is an important predictor of SAM [11]. Elongation of the MV leaflets can be pathological or may result from surgical correction. This evidence provides the rationale for the

anterior valvuloplasty as a surgical technique to address SAM [12]. Changes to posterior leaflet height have also been proposed to be important as it results in anterior shifting of the coaptation point closer to the base of the anterior leaflet, predisposing to SAM [13]. This supports the role of the sliding posterior leaflet plasty technique to move the coaptation point posteriorly [4] as a treatment for SAM. The relationship between the anterior and posterior leaflets is also important as an anterior:posterior leaflet length ratio  $<1.3$  is a risk factor for SAM. Carpentier and coworkers [7] asserted that the essential cause of SAM is excess tissue with respect to the annulus. To prevent this during MV repair, he has proposed a number of principles. These are outlined in a later section on prevention of SAM during MV repair.

**The role of the mitral annulus.** Recent animal [14, 15] and clinical studies [16] associate the insertion of rigid/semirigid mitral rings with the disruption of anterior mitral annulus dynamics. Patients with mitral rings can demonstrate gross-disruption of LVOT function on cardiac magnetic resonance imaging (MRI) [16], and there is increasing evidence that identifies the disruption of mitral annular and aortic root dynamics as the primary cause of SAM after MV repair using leaflet resection and rigid rings (independent to leaflet size). This is supported by evidence from a large series of patients [17] who underwent MV annuloplasty with major efforts to preserve normal annular dynamics. Subjects did not receive leaflet resection and were not given oversized rings, and as a result demonstrated successful post-operative mitral dynamics. SAM is normally prevented by the early systolic expansion of the aortic root and the flattening of the aorto-mitral angle that displaces the anterior mitral annulus upwards and backwards into the left atrium. In addition, the 'steepening of the saddle' shape of the annulus also moves the middle of the anterior leaflet up and out of the LVOT [18].

Annular undersizing is also a risk factor for SAM as it promotes bulging of the leaflet tissues. This may occur when an excessively small annuloplasty ring is inserted, or if a misjudged posterior quadrangular resection makes too much of the annular circumference redundant [4, 19]. Annuloplasty ring sizes should

be selected according to the risk of SAM, with large rings used in patients at high risk of SAM. The use of small rings is associated with post-operative SAM, and their removal can resolve SAM [20]. Any reduction in annular circumference reduces the mitral-aortic angle, which increases the risk of SAM [21].

**The role of the subvalvular apparatus.** The subvalvular apparatus can alter the position of the coaptation zone with respect to the septum, and this can result in SAM. There is growing evidence that SAM is associated with chordal anomalies such as elongation and buckling. Surgical interventions on the chordal including transection, translocation and reimplantation may result in SAM. SAM of the chordae themselves can also occur, in patients presenting for echocardiography for cardiac disease or in the absence of any known cardiac abnormality [22]. It is not known what drives this 'isolated chordal SAM', as patient characteristics do not differ between those presenting for echocardiography with known cardiac anomalies.

The papillary muscles are of special importance in asymmetric ventricular hypertrophy, where anterior and medial displacement of the papillary muscles significantly influences SAM. Papillary muscle function also influences SAM as pacing of the papillary muscles (through placement in the lateral wall of the LV) has been shown to abolish SAM [23]. Despite the importance of structural changes to the ventricle, MV and subvalvular apparatus in HCM, the capacity of SAM always exists in the normal ventricle, as demonstrated by *in vitro* flow dynamics studies. This is due to flow velocities which drag the MV towards the LV, although they may be insufficient alone to induce SAM [24].

**The role of ventricular morphological changes.** Both acquired hypertrophy and HCM can result in SAM. Approximately 1% of cases of SAM may also arise in the context of a hypertrophied ventricle due to the factors identified in Fig. 1 [22]. These include elongated chordae and a small, hyper-dynamic LV cavity. These mechanisms appear to differ to those observed in HCM, where a prominent septum and abnormal MV anatomy play a significant role. The presence of a 'bulging' subaortic septum is also an important risk factor for SAM after MV repair [25]. SAM peaks at the end of systole in non-HCM hypertrophied ventricles but peaks at approximately two-thirds the way through systole in HCM [26]. The presence of SAM in hypertension may alter management, as vasodilators could worsen SAM and LVOT.

The function of the LV must be considered when assessing SAM because this is a result of complex geometric interaction between valve components requiring significant Venturi and drag forces. This implies that SAM may not be apparent if the LV is contracting poorly. Occasionally, SAM may develop late after surgery when LV function recovers sufficiently to induce SAM [27].

### Rare causes of systolic anterior motion

SAM has been documented as a part of complex congenital anomalies involving subaortic stenosis [28], a cleft AML and an accessory papillary muscle that was successfully managed by surgery. Other rare congenital causes of SAM include transposition of the great arteries, where myocardial dysfunction may make surgical correction impossible requiring careful medical management [29].

Post-AVR SAM should be considered in the context of pre-existing aortic stenosis where increased blood velocity in the

LVOT causes drag on the AML to result in SAM [30]. This is compounded by the hypertrophic, smaller LV cavity often found in such patients. After surgery, reductions in afterload may cause the MV to move closer to the LVOT. Post-AVR SAM in the context of aortic insufficiency is uncommon as the LV is commonly dilated, minimizing the risk of SAM, as this extends the distance between the LVOT and MV and there is often a compensatory hypervolaemia in these patients [31].

In ~2% of Takotsubo cardiomyopathy patients, SAM and LVOTOs can be the presenting features [32]. The mechanisms mediating this are not defined, but involve a reduction in the LV volume and the effect of mid- and distal LV dyskinesia, and compensatory basal hyperkinesia [32].

SAM has also been noted as a manifestation of cardiac allograft rejection [33] which resolves after rejection is treated. SAM may also occur due to the presence of pericardial stay sutures used in minimally invasive surgery [34].

### Medical causes of systolic anterior motion

There are a number of medical causes of SAM including diabetes mellitus, myocardial infarction (MI), hypertension (discussed above), during dobutamine stress echocardiography (DSE) and general anaesthesia.

**Diabetes mellitus.** The mechanism of SAM in diabetics is complex, as there are often multiple other concurrent cardiac pathologies resulting in myocardial ischaemia and hypertrophy. Nevertheless, there may be a specific mechanism as suggested by studies of beta-adrenoceptor stimulation in diabetic and control subjects. Upon beta-adrenoceptor stimulation by intravenous infusion of isoproterenol, echocardiography revealed SAM in 65% of diabetic subjects compared with 9% of controls [35]. There may be an increased beta-adrenoceptor sensitivity, which mediates a hyperdynamic state. In the context of LV hypertrophy, this results in SAM.

**Dobutamine stress echocardiography.** SAM may emerge during dobutamine stress testing [36]. This is predicted by the concept of MV reserve, which states that SAM occurs when the physiological state of the circulation promotes or allows patho-anatomical features of the MV to result in SAM. The physiological state results in an 'unmasking' of anatomical features that provoke SAM via the MV and its apparatus.

**Post-myocardial infarction.** SAM is sometimes observed following MI. This is thought to be due to alterations in LV geometry triggered by the opposition of hypokinetic and hyperkinetic regions after acute MI. This reduces the size of the LVOT and promotes SAM [37]. Therapy with inotropes and vasodilators classically used in cardiogenic shock may worsen SAM and cause further LVOTO. These patients require careful management with beta-adrenoceptor blockade.

**Systolic anterior motion during general anaesthesia.** SAM can rarely occur in patients without cardiac pathology undergoing general anaesthesia [38]. Absolute hypovolaemia or the vasodilator effect of anaesthetic agents can result in LV under-filling which reduces the LVOT size to result in a hyperdynamic LV. Under-filling of the LV also changes the geometry of the ventricle to move the papillary muscles relatively anterior and inwards. The hyperdynamic state raises outflow tract velocity, increasing drag forces on the MV and

resulting in LVOTO. This should be managed by volume loading, peripheral vasoconstriction and beta-adrenoceptor blockade.

## Imaging modalities and risk assessment of systolic anterior motion

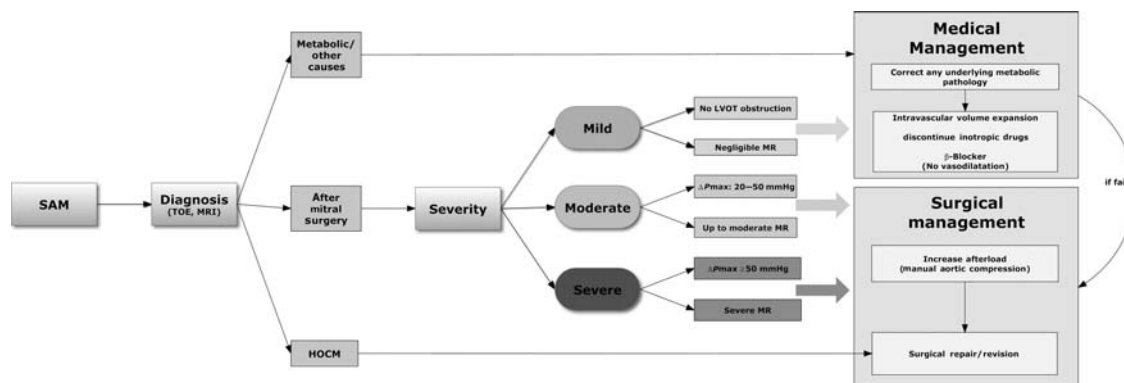
The risk assessment of SAM using imaging modalities continues to evolve, but depends on careful echocardiography, which should always be performed on a full, closed ventricle (that is, off cardiopulmonary bypass support). Traditional two-dimensional echocardiography is useful in confirming the presence of SAM and assessing the LVOT gradient. It may point to a clear, gross-anatomical cause. Trans-oesophageal echocardiography (TOE) provides clearer images which allow for further investigation of the anatomical substrate. For most patients, TOE will provide a sufficient detail to decide on the relative importance of SAM in any LVOTO or mitral regurgitation (MR). This is the first step in formulating a management plan. For those with complex anatomy, MRI provides the best imaging modality to decide on the relative contribution of any one of a number of possible anatomical causes of SAM including anomalies of the leaflet, chordae and septum. Three-dimensional echocardiography also allows a detailed assessment of the anatomy of SAM. It also has the benefit assessing the dynamic contribution of these components at different phases of the cardiac cycle.

Guarise *et al.* [39] compared the ability of echocardiography and cardiac MRI in assessing SAM in consecutive patients diagnosed with SAM. They found that MRI was more sensitive than echocardiography in identifying the presence of SAM, but that both modalities were equally able to identify the site of the disease. The authors conclude that MRI is superior in its objectivity, assessing the functional implications of SAM and assessing early, subtle consequences of SAM such as secondary mitral regurgitation visible by a left atrial jet.

There are a number of structural and geometric factors for SAM which should be assessed (Fig. 1). The most important are the ratio of anterior:posterior leaflet height, the annular circumference and the distance between the coaptation point and the septum. Any SAM at rest should be characterized and documented, including the LVOT gradient. General assessment of the ventricle should be made including wall thicknesses, septal features, LVOT size and any hypokinetic regions.

As described before, the phenomenon of SAM occurs when a permissive physiological state arises in an anatomically susceptible heart. This implies that the MV has an adaptive reserve which prevents SAM in the face of altered physiological conditions; SAM therefore is most likely to occur when an anatomically susceptible ventricle undergoes physiological changes which promote SAM—the mitral reserve principle [40]. Therefore, one way to test the severity of SAM is to perform ‘provocation’ tests by altering the physiological state. The most common setting for this approach is perioperative TOE during MV repair. SAM may be present in a patient after MV repair, but the functional consequences may not be clear. Is the SAM likely to result in clinically significant LVOTO and/or mitral regurgitation? There are two approaches to testing SAM in this way: first, conservative approaches can be used to try to ameliorate or eradicate SAM. This involves volume loading, discontinuation of inotropes and beta-adrenoreceptor blockade [40] (Fig. 2). If SAM is abolished, it is likely to be clinically silent or responsive to medical therapy. The second approach is to try to create a permissive physiological state, and characterize the most severe degree of SAM which is likely to develop under the ‘worst’ physiological conditions. This involves delivery of nitroglycerin and rapid ventricular pacing for ~15 min. The LVOT gradient is then assessed, and if a significant gradient arises, a surgical correction is warranted. If not, it can be safely assumed that the patient is unlikely to develop serious LVOT and SAM under even the most challenging physiological conditions. SAM may precipitate during stress echocardiography. Stressful stimuli include short bursts of exercise and using DSE. In a study of 100 consecutive patients undergoing DSE, Meimoun *et al.* found that 23% of patients presenting for DSE during assessment of myocardial ischaemia had SAM when stressed. These patients exhibited specific anatomical features including reduced mitral–aortic angle, reduced septum–aortic angle, higher posterior mitral leaflet (PML) length and a smaller LV. The presence of SAM was not correlated with the finding of myocardial ischaemia or hypotensive response, and the authors conclude that the presence of SAM is not indicative of increased clinical severity.

An important role for imaging is to assess the outcomes of MV repair. SAM may arise in a surgically repaired valve, even if it did not pre-exist. Freeman *et al.* [41] assessed the ability of echocardiography to identify and characterize SAM in a population of patients undergoing MV repair. They report an incidence up to 9% of SAM in patients undergoing TOE post-MV repair.



**Figure 2:** The management of SAM. TOE: transoesophageal echocardiography; MRI: magnetic resonance imaging;  $\Delta P_{\max}$ : left ventricular outflow tract (LVOT) maximum pressure gradient; mmHg: millimetres of mercury.

Clearly, this will vary with the patient cohort, surgical approach and surgical experience. This report also indicates that the immediate post-surgical trans-oesophageal and pre-discharge transthoracic echocardiograms may differ significantly.

Echocardiography is also a powerful tool to characterize SAM patterns. However, when multiple components interact to produce SAM, three-dimensional echocardiography has demonstrated an emerging role in allowing the visualization and investigation of SAM of complex aetiology [42], although this technology is not widely available at present. Preliminary studies also indicate that the use of tissue Doppler may accurately identify SAM, and reduce the need for further studies [43].

In summary, echocardiography has a central role in detecting SAM and in characterizing the anatomical features of the MV. If there are many risk factors (Fig. 1), then a preventative repair should be performed. If SAM develops after the repair, alteration in the physiological state will guide surgical decision-making.

## The management of systolic anterior motion

The correct management of SAM depends on two factors: the anatomical lesion responsible and the degree of severity, which is also related to the response of conservative therapy. Here, we discuss the management according to each lesion, and then discuss preventative strategies for those undergoing MV repair. Finally, we describe an overall strategy and the anatomical principles of the main techniques used to prevent or repair SAM surgically. These techniques have been described in detail in Table 1 and in Fig. 3.

**What is the role of medical therapy?** Brown *et al.* [20] assessed the effectiveness of medical therapy in all 174 cases of SAM arising in a cohort of 2076 patients (8.4%). They report that treatment with beta-adrenoceptor blockade, volume loading and phenylephrine was sufficient to correct SAM in the vast majority of patients and only four patients required reoperation for SAM, and at late follow-up SAM persisted in only 17 patients. These results suggest that medical therapy alone may be sufficient for mild SAM, but surgical therapy remains the definitive therapy for serious SAM.

A systematic approach for the management of intraoperative post-MV repair SAM has been proposed by Crescenzi *et al.* [44]. They propose a logical stepwise approach consisting of conservative management first. This starts with cessation of inotropes and intravascular volume expansion (Step 1). If this fails, then beta-adrenoceptor blockade is initiated and the aorta is compressed manually for 30 s (Step 2) (Fig. 2). If SAM persists, a surgical repair is attempted. A total of 9.8% of patients in their series of 608 patients had SAM, and <1% of patients had persistent SAM requiring reoperation.

However, whether the outcomes of patients with moderate SAM who are treated medically are as good as those who did not require medical management for SAM is not clear. Sorrell *et al.* [45] have described the mid- to long-term outcomes of patients with transient MR- and SAM-treated medically. They showed that although it may be possible to abolish even moderate or severe MR and SAM, it is the degree of transient MR which stratifies patients. Those with moderate or severe SAM are more likely to later require reoperation or develop other complications. Therefore, medical therapy alone may be insufficient,

despite adequately removing the MR and SAM, as these may indicate an underlying pathology.

## Preventing systolic anterior motion using techniques

**focussing on the leaflet.** Shah *et al.* [11] used TOE to identify a high AML and a small annulus to be characteristic of patients with SAM. Furthermore, the AML and annular dimensions appeared to have a marked mismatch in patients with SAM. They therefore proposed that the choice of annular ring size should take into account the AML height and that the AML height was the most important determinant of SAM. This work supports the use of anterior valvuloplasty, an elliptical excision of the AML, to prevent SAM. If anterior valvuloplasty is to be effective, it is important that the AML dimensions are properly assessed. Preoperative assessment of the AML height (the distance from the anterior annulus to the rough zone) is made using TOE and then the AML area is measured after exposure of the MV intra-operatively. The maximum size of the elliptical excision can then be calculated to adequately reduce the AML height and area. This excision site is then closed with double-layer prolene stitches, and then the MV repair continues as normal. The annuloplasty ring size should be selected on the basis of the reduced AML area. Quigley *et al.* [46, 47] reported the outcomes of this technique in 47 patients, and showed that there was no postoperative SAM. Quigley *et al.* also showed a significant reduction in the anterior:PML ratio and the distance between the coaptation point and the annulus. Grossi *et al.* [3] showed that adopting anterior annuloplasty in patients at high risk of SAM reduced its occurrence from 9.1 to 3.4%. The reduction in the AML height by ellipsoid excision, with repositioning of major basal chords, has been described by Raney *et al.* [48] as the Pomeroy procedure.

Lee *et al.* [13] used TOE in 14 patients pre- and post-SAM corrections who developed SAM post-MV repair. They showed that during SAM, a large PML could result in a relatively more anterior coaptation line and used this to suggest that the posterior leaflet sliding plasty could eliminate SAM. This technique was developed in 1988 by Carpentier and reduces the height of the posterior leaflet [49]. The middle posterior segment is most commonly implicated and if confirmed by intraoperative inspection and TOE, then sliding plasty is performed. The excessive leaflet is resected from the PML by triangular resection and the remnants of the posterior leaflet are detached from the annulus.

The annuloplasty ring is then placed and the posterior leaflet can be reconstructed using continuous sutures. In a modified technique, the triangular resection is not performed saving time [50]. The excess tissue at the base of the PML is taken in to buttress the annuloplasty ring.

Reports of the outcomes of sliding leaflet technique show the rates of SAM of between 0 and 2% [4, 51]. When the sliding leaflet technique is insufficient to abolish SAM, George and Gillinov [52] have described a technique to deal with any remaining excess tissue by a pledgetted tethering of mitral excess tissue. They used this technique in four patients where the sliding plasty was not sufficient to abolish SAM. Gillinov and Cosgrove [50] presented a modified sliding plasty which eliminates the triangular resection. Instead, the excess PML tissue is taken into the annulus with deep bites which reduce the height of the leaflet and support the annulus.

An alternative method of preventing SAM involving the leaflets is the edge-to-edge, or Alfieri stitch technique [53].

**Table 1:** Surgical techniques in the management of SAM

Technique	Use	Target	Repair	Comments	Outcomes	References
<b>Techniques targeting coaptation point</b>						
Assymmetric Alfieri stitch	At MV repair, post MV repair	AML, PML	Move coaptation point	A1-P1 stitch instead of midline	Case report	[55]
Edge to edge repair	At MV repair, post MV repair	AML, PML	Move coaptation point		Successful in 4 patients with post MV repair SAM [54] No SAM in series of 72 patients [73]	[53]
<b>Techniques targeting posterior leaflet</b>						
Posterior leaflet ventricularization	At MV repair	PML	Resect PML, height adjustment of the MLs	Triangular resection of posterior leaflet and ventricularization	-	[56]
Sliding leaflet plasty	At MV repair	AML, Annulus	Height adjustment of the MLs			[19]
Modified sliding leaflet technique	At MV repair	PML	Resect PML	Middle scallop of PML is resected, differs from Carpentier in eliminating triangular resection.	No SAM in series of 227 patients with no SAM	[50]
Posterior leaflet folding plasty	At MV repair	PML	Resect PML, reduce area of MLs	Reduces excess tissue of PML	When used as MV repair technique, 4% of 45 patients	[12]
Loop technique	At MV repair	PML, chordae	Height adjustment of the MLs	Artificial chordae used		[57]
Chordal translocation	At MV repair	PML, chordae	Move coaptation point	PML secondary chordae are transected and moved to the AML		[58]
Posterior leaflet shortening	Post MV repair	PML	Reduce area of MLs	Gathers in excess PML tissue	Successful in report of series of 4 patients	[52]
<b>Techniques targeting anterior leaflet</b>						
Pomeroy procedure	Post MV repair	AML	Resect AML, height adjustment of the MLs	Removal of excess AML tissue		[48]
Elliptical AML resection	At MV Repair	AML	Resect AML		No SAM in a cohort of 47 patients	[46]
AML retention plasty	HCM	AML	Move coaptation point, height adjustment of the MLs	AML nearest the trigones are freed and sutured to the annulus.	No SAM in a series of 12 children	[74]
Transaortic correction of SAM	At MV repair	AML, PML	Resect AML, resect PML	In presence of aortotomy, excess mitral tissue after MV replacement may induce SAM. Resection possible through aortotomy		[61, 75]
<b>Techniques targeting the annulus</b>						
Annular enlargement	Post MV repair, Barlow disease	Annulus	Reduce area of MLs, annulus	36-40 mm annular rings are used in presence of excessive mitral tissue.	Used in 67 patients with Barlow's disease with no SAM	[76]
Annular plication	At MV repair, post MV repair	PML, annulus	Move coaptation point, reduce area of MLs, Annulus	Plication sutures are used to tie down the PML to the annulus	No SAM in series of 69 patients	[77]
<b>Techniques for HCM</b>						
Resection-plication-release	HCM	AML, chordae, LVOT	Move coaptation point, height adjustment of the MLs, reduce area of MLs	Myectomy, plication of the AML, release of the papillary muscles remodels the LV to reduce SAM	No SAM in 50 patients, at 2.5 years	[78]
Myectomy-loop technique	HCM	AML, chordae, LVOT	Move coaptation point, height adjustment of the MLs	AML chordae are transected and artificial chordae used to move the CP	Successful in series of 4 patients with HCM and SAM	[79]

Mascagni *et al.* [54] used the Alfieri stitch technique in four patients with SAM resistant to medical therapy. This uses a continuous suture with large bites between the anterior and posterior leaflets in the mid-region. The suture measures 5 mm and ensures a large area of coaptation, reducing the anterior motion of the AML, the redundant tissue area as well as AML height. All patients showed the absence of SAM at a mean follow-up of 14 months. This technique significantly alters the MV anatomy and disturbs the flow patterns across the valve, which has attracted some criticism. MV repair using edge-to-edge repair has also been reported to occasionally cause SAM [20]. Pereda *et al.* [55] have described a modified Alfieri leaflet stitch with draws the AML towards the posterior leaflet, avoiding the LVOT.

A rapid procedure with many of the benefits of posterior sliding plasty is the posterior leaflet shortening [52]. Four

pledgetted interrupted horizontal mattress sutures are placed in the posterior leaflet to shorten it. The height reduction at each suture should be the same so as not to distort the shape of the PML. This technique was successful in four patients, who had maintained freedom from SAM at discharge.

Posterior leaflet ventricularization attempts to correct the excessive posterior leaflet tissue by plication into the ventricle after triangular resection [56].

**Preventing systolic anterior motion using techniques focussing on the chordae.** The loop technique is a well-established method for using artificial chordae to repair the MV. After artificial chordae and annuloplasty ring placement in the normal way, a polyester reduction suture with a spaghetti loop supporting it is placed on the posterior leaflet surface, and

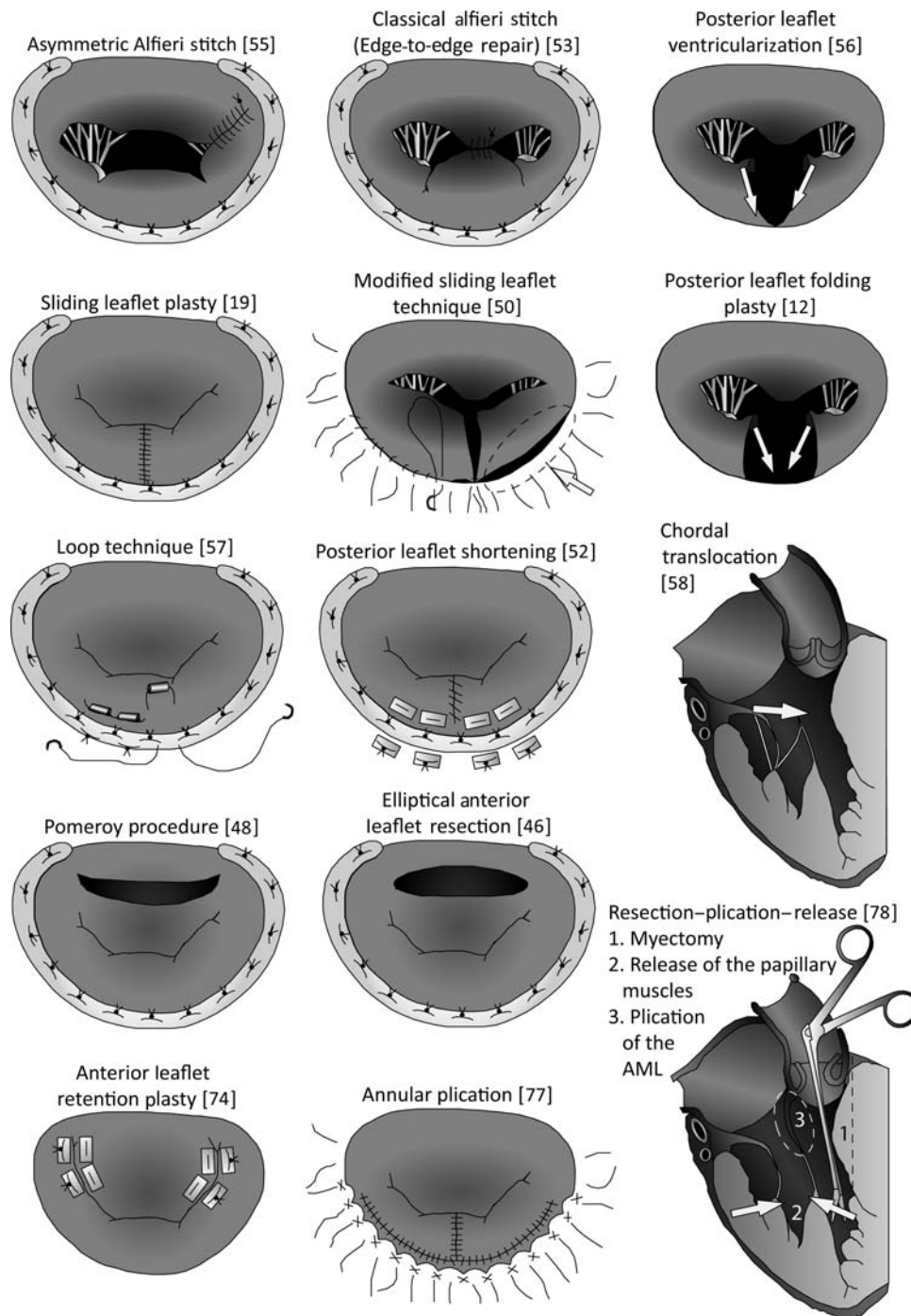


Figure 3: Surgical techniques for the repair of SAM. Numbers refer to references in the text.

tied down until its height is <math><1.5\text{ cm}</math>. This technique typically requires the placement of two or three sutures in the posterior leaflet (see Fig. 3, 'Modified loop technique' as described by Kudo).

These artificial chordae allow preservation of the anatomy of the MV while preventing the extent of the motion of the PML [57].

Extra native secondary chordae on the mid-portion of the posterior leaflet can be utilized to prevent SAM if they are present. In patients at risk of developing SAM, these chordae can be transferred to the underside of the mid-portion of the

anterior leaflet [58]. Chordae are removed from the resected portion of the posterior leaflet and placed between the anterior leaflet's primary and secondary chordae. The 4-0 prolene sutures are passed through the atrial side of the AML, and tied over a small Teflon pledget. Only normal chordae are used. This technique translocates the most posterior chordae to the anterior leaflet, thus limiting the anterior motion of the AML.

Occasionally, accessory chordae can tether the AML to the septum, resulting in SAM [59]. The removal of these accessory chordae successfully eliminates SAM in such cases.

**Prevention of systolic anterior motion during mitral valve repair.** The large body of work describing echocardiographic risk factors predictive of SAM allows the surgeon to assess the likelihood of post-operative SAM prior to operation. This information can be used to incorporate techniques to reduce the risk of SAM. These techniques are identified in Table 1 ('At MV Repair'). The selection of which technique to use depends on the pathology. For instance, if the valve is floppy, as in Barlow's disease, then a large annuloplasty ring can be inserted. If the main pathology is chordal, then a loop technique can be incorporated. Therefore, a clear understanding of each SAM technique and its anatomical appropriateness allows one to prevent SAM in the post-operative setting.

**When mitral valve replacement can be used for treatment of systolic anterior motion.** MV repair is superior to replacement [60], especially for younger and female patients. This is also in keeping with the shift towards respect for the tissues, rather than resection. However, SAM is not a benign condition and LVOTO can have fatal consequences. If SAM is severe and persistent despite exhaustive medical and surgical attempts at eliminating SAM, MV replacement can be the only option. In this setting, care must be taken to properly resect any remaining mitral tissue, to prevent SAM recurring [61]. The decision to opt for replacement depends on the chances of successfully eliminating SAM by repairing, or re-repairing the MV. Re-repair can be successful [62], and is more likely to succeed if attempted close to the time of the initial repair. MV replacement has a very small role in the modern management of SAM.

### The current state of systolic anterior motion therapy

We have described a number of approaches to tackling SAM, from conservative medical approaches to multiple techniques designed to re-repair the MV and eliminate SAM. In this section, we address how these techniques compare to one another and describe a literature-based approach.

First, we emphasize the important role of imaging and risk assessment in preventing SAM after MV repair. Where SAM has occurred, or was not preventable, medical therapy has a proven role. We propose that medical therapy should be used to stabilize the patient and to adequately assess the degree of SAM and MR. If there is only mild SAM and MR, then medical therapy should be used. However, in moderate or worse SAM and MR, we propose that even if medical therapy is able to abolish SAM, a surgical solution should be sought. This is because there is likely to be an underlying pathology which is causing SAM, and this may have detrimental long-term outcomes.

We propose that it is inappropriate to rate one surgical procedure as superior to another. This is because each technique has evolved to meet a specific anatomical problem. We suggest that each technique has its own utility and by understanding the anatomical context of each. However, we suggest a number of principles to guide the selection of a particular technique.

First, the surgeon must understand the anatomical cause of SAM, and this may provide a narrower list of techniques described for that cause. In addition, the ease of the repair should be considered, as this will have beneficial consequences for the total time taken to complete the operation, and the total

time under cardiopulmonary bypass. On the other hand, the durability of the repair should also be considered. These features cannot be assessed *a priori*, and mid- and long-term studies of each are required. Further, these parameters are dependent also on the individual surgeon, as a particular technique may be more effective in the hands of one surgeon, whilst another surgeon may be faster and more effective using another technique. When all conditions are the same, we propose the application of a technique that optimizes cardiac physiological function. This is a repair which resects as little tissue as possible and that does not distort the anatomy significantly. These principles would support the use of the placement of large annuloplasty rings and artificial chordae, while the Alfieri stitch distorts the anatomy of the normal valve by creating a double-lumen orifice which unless essential for the treatment of SAM should be avoided. Another alternative that should be mentioned is a surgical correction of SAM through less-invasive techniques, for example Nakamura *et al.*'s [61] resection of excessive mitral tissue during an aortic valve replacement.

## SYSTOLIC ANTERIOR MOTION DUE TO HYPERTROPHIC CARDIOMYOPATHY

### The incidence of systolic anterior motion in hypertrophic cardiomyopathy

SAM is predominantly observed in patients with HCM (where it was originally considered to be pathognomonic for this disease) or after cardiac surgery, typically as a complication of MV repair. It occurs in 31–61% of HCM patients, where it is associated with resting LVOTO in 25–50% of cases (based on several small series) [22, 26, 63].

### The mechanisms of systolic anterior motion in hypertrophic cardiomyopathy

Congenital papillary anomalies associated with HCM can contribute to SAM, although papillary muscle displacement and associated leaflet elongation can also cause SAM in the absence of ventricular hypertrophy or HCM [64]. In HCM, the anterior displacement of papillary muscles is thought to create diastolic downwards vortex forces which pull the MV into the LVOT [65].

The characteristic septal hypertrophy observed in HCM creates large drag forces and promotes the Venturi effect which can move the MV anteriorly, resulting in SAM. The diminished LVOT also lowers the threshold for SAM. The MV anatomy is disrupted adopting an abnormal D-shape, with a large amount of anterior leaflet tissue entering the LVOT. In HCM, SAM begins before the initiation of ventricular ejection [66], perhaps reducing the importance of Venturi effect. The papillary muscles are displaced anteriorly and inward and the leaflets are also enlarged, promoting SAM. The mechanisms of SAM in HCM have been recently studied in the beating *in vivo* heart by three-dimensional echocardiography studies [67]. The factors found to influence SAM represent a geometrical rearrangement of the subvalvular apparatus, in a small LV. Hwang *et al.* [68] have recently documented a dynamic geometric rearrangement of the morphology of the mitral subvalvular apparatus, mitral tenting and the



mitral coaptation point to be implicated in the pathogenesis of SAM in HCM. Lin *et al.* [69] have investigated the temporal development of forces acting on the MV. The LVOTO seen in HCM leads to Bernoulli pressure drop in early systole which moves the MV anteriorly, initiating SAM. During systole, continuous blood flow promotes the suction effect on the MV, sustaining SAM. As blood flow falls during late-systole, SAM regresses.

### Echocardiographic assessment of hypertrophic cardiomyopathy-induced systolic anterior motion

In HCM, SAM may arise due to a number of causes and combinations of these causes including leaflet pathology (involving specific aspects of the leaflet), chordae anomalies and the septum. Spirito *et al.* [70] assessed SAM aetiology in 62 patients with HCM. They showed that in 58% of patients both leaflets play a role in the SAM, in 31% the posterior leaflet alone was responsible, and in 10% only the AML was responsible for SAM. In 1% of patients, SAM is attributable to anomalies of the chordae tendinae. In general, 82% of patients only the tip of the mitral leaflet and chordae were involved rather than the proximal elements. It is important to note that this study shows that echocardiography is often sufficient to characterize the origin of SAM to a high degree.

**Surgical approaches to SAM in HCM.** SAM arises in HCM due to the complex ventricular phenotype of septal hypertrophy which increases the drag forces acting on the MV, and also due to primary MV anomalies. In addition, the LVOTO results in generalized hypertrophy which contributes to the diminution of the ventricular cavity and also promotes SAM. Therefore, a multifaceted approach to repair and abolition of SAM is required. Septal myectomy is fundamental to any of these. Septal myectomy increases the distance between the AML and the septum, and also reduces the LVOTO. The latter results in reversal of ventricular hypertrophy which further reduces the risk of SAM. In addition, specific techniques for SAM in the context of HCM have been described (Fig. 3). In general, these either focus on altering the physiology of the LV through ventricular remodelling, making SAM less likely, or they address the anatomy of the mitral annulus and displaced papillary muscles. Seeburger *et al.*'s myectomy-loop which uses chordal replacement and Delmo-Walter *et al.*'s retention-plasty of the AML are anatomical repairs which are preferable to drastic ventricular remodelling. Alcohol septal ablation for HCM has been developed as a less-invasive alternative to surgical myectomy, although its role in the management of HCM associated with SAM requires further and the current evidence supports the use of septal myectomy [71].

### CONCLUSIONS

SAM is a complex disorder that shifts the MV anteriorly during systole to impair cardiac performance. Its mechanisms are not fully understood, but include patho-anatomical dysfunction relating to the MV and its apparatus. It is classically observed in HCM patients or after MV surgery, although it can also be observed in a wide spectrum of underlying diseases. The current diagnosis of SAM is based on detailed echocardiography or MRI and its subsequent management requires a stepwise approach

that ranges from initial medical management to eventual surgery as a last option. Treatment decisions should be based on disease severity and multi-disciplinary cardiac expertise in the context of specialist centres. Further research is necessary to clarify the optimum diagnostic and treatment strategies for SAM through the application of long-term longitudinal studies. Understanding the mechanisms of this multi-faceted disorder may provide future therapeutic options. Progress in the molecular biology of HCM may enable the correction of the molecular defect, therefore preventing the progression to SAM. More generally, technological advances may facilitate repair of SAM through robotic, minimally invasive (for example, through the ventricular apex [72]) techniques under the guidance of improved imaging modalities.

**Conflict of interest:** none declared.

### REFERENCES

- Termini BA, Jackson PA, Williams CD. Systolic anterior motion of the mitral valve following annuloplasty. *Vasc Surg* 1977;11:55-60.
- Singh JP, Evans JC, Levy D, Larson MG, Freed LA, Fuller DL *et al.* Prevalence and clinical determinants of mitral, tricuspid, and aortic regurgitation (the Framingham Heart Study). *Am J Cardiol* 1999;83:897-902.
- Grossi EA, Steinberg BM, LeBoutillier M III, Ribacove G, Spencer FC, Galloway AC *et al.* Decreasing incidence of systolic anterior motion after mitral valve reconstruction. *Circulation* 1994;90:1195-7.
- Jebara VA, Mihaileanu S, Acar C, Brizard C, Grare P, Latremouille C *et al.* Left ventricular outflow tract obstruction after mitral valve repair. Results of the sliding leaflet technique. *Circulation* 1993;88:1130-4.
- Maslow AD, Regan MM, Haering JM, Johnson RG, Levine RA. Echocardiographic predictors of left ventricular outflow tract obstruction and systolic anterior motion of the mitral valve after mitral valve reconstruction for myxomatous valve disease. *J Am Coll Cardiol* 1999;34:2096-104.
- Rey MJ, Mercier LA, Castonguay Y. Echocardiographic diagnosis of left ventricular outflow tract obstruction after mitral valvuloplasty with a flexible Duran ring. *J Am Soc Echocardiogr* 1992;5:89-92.
- Zegdi R, Carpentier A, Doguet F, Berrebi A, Khabbaz Z, Chauvaud S *et al.* Systolic anterior motion after mitral valve repair: an exceptional cause of late failure. *J Thorac Cardiovasc Surg* 2005;130:1453-4.
- Suri RM, Schaff HV, Dearani JA, Sundt TM III, Daly RC, Mullany CJ *et al.* Recurrent mitral regurgitation after repair: should the mitral valve be re-repaired? *J Thorac Cardiovasc Surg* 2006;132:1390-7.
- Charls LM. SAM-systolic anterior motion of the anterior mitral valve leaflet post-surgical mitral valve repair. *Heart Lung* 2003;32:402-6.
- He S, Hopmeyer J, Lefebvre XP, Schwammenthal E, Yoganathan AP, Levine RA. Importance of leaflet elongation in causing systolic anterior motion of the mitral valve. *J Heart Valve Dis* 1997;6:149-59.
- Shah PM, Raney AA. Echocardiographic correlates of left ventricular outflow obstruction and systolic anterior motion following mitral valve repair. *J Heart Valve Dis* 2001;10:302-6.
- Grossi EA, Galloway AC, Kallenbach K, Miller JS, Esposito R, Schwartz DS *et al.* Early results of posterior leaflet folding plasty for mitral valve reconstruction. *Ann Thorac Surg* 1998;65:1057-9.
- Lee KS, Stewart WJ, Savage RM, Loop FD, Cosgrove DM III. Systolic anterior motion of mitral valve after the posterior leaflet sliding advancement procedure. *Ann Thorac Surg* 1994;57:1338-40.
- Bothe W, Kvitting JP, Swanson JC, Goktepe S, Vo KN, Ingels NB *et al.* How do annuloplasty rings affect mitral leaflet dynamic motion? *Eur J Cardiothorac Surg* 2010;38:340-9.
- Bothe W, Kvitting JP, Stephens EH, Swanson JC, Liang DH, Ingels NB Jr *et al.* Effects of different annuloplasty ring types on mitral leaflet tenting area during acute myocardial ischemia. *J Thorac Cardiovasc Surg* 2011;141:345-53.
- Caimmi PP, Diterlizzi M, Grossini E, Kapetanakis EI, Gavinelli M, Carriero A *et al.* Impact of prosthetic mitral rings on aortomitral apparatus function: a cardiac magnetic resonance imaging study. *Ann Thorac Surg* 2009;88:740-4.

- [17] Braun J, Ciarka A, Versteegh MI, Delgado V, Boersma E, Verwey HF *et al.* Cardiac support device, restrictive mitral valve annuloplasty, and optimized medical treatment: a multimodality approach to nonischemic cardiomyopathy. *J Thorac Cardiovasc Surg* 2011;142:e93-100.
- [18] Jensen MO, Jensen H, Levine RA, Yoganathan AP, Andersen NT, Nygaard H *et al.* Saddle-shaped mitral valve annuloplasty rings improve leaflet coaptation geometry. *J Thorac Cardiovasc Surg* 2011;142:697-703.
- [19] Mihaileanu S, Marino JP, Chauvaud S, Perier P, Forman J, Vissoat J *et al.* Left ventricular outflow obstruction after mitral valve repair (Carpentier's technique). Proposed mechanisms of disease. *Circulation* 1988;78:178-84.
- [20] Brown ML, Abel MD, Click RL, Morford RG, Dearani JA, Sundt TM *et al.* Systolic anterior motion after mitral valve repair: is surgical intervention necessary? *J Thorac Cardiovasc Surg* 2007;133:136-43.
- [21] Muresian H. Prevention of systolic anterior motion after mitral valve repair. *Tex Heart Inst J* 2005;32:453-4.
- [22] Pearson AC, Pasierski TJ, Orsinelli DA, Gray P, Huschart K. Systolic anterior motion of the mitral chordae tendineae: prevalence and clinical and Doppler-echocardiographic features. *Am Heart J* 1996;131:748-53.
- [23] Truin G, Backx A, van Wetten H, Neeleman C. Cardiac resynchronization therapy for mitral systolic anterior motion in a child. *Ann Thorac Surg* 2007;83:1873-4.
- [24] Yoganathan AP, Lemmon JD Jr, Kim YH, Levine RA, Vesier CC. A three-dimensional computational investigation of intraventricular fluid dynamics: examination into the initiation of systolic anterior motion of the mitral valve leaflets. *J Biomech Eng* 1995;117:94-102.
- [25] Said SM, Schaff HV, Suri RM, Greason KL, Dearani JA, Nishimura RA. Bulging subaortic septum: an important risk factor for systolic anterior motion after mitral valve repair. *Ann Thorac Surg* 2011;91:1427-32.
- [26] Doi YL, McKenna WJ, Oakley CM, Goodwin JF. 'Pseudo' systolic anterior motion in patients with hypertensive heart disease. *Eur Heart J* 1983;4:838-45.
- [27] Rescigno G, Cecconi M, Matteucci ML, Domenella P, Munch C, Iacobone G. Delayed systolic anterior motion after mitral valve repair. *J Heart Valve Dis* 2006;15:512-4.
- [28] Iwata Y, Imai Y, Shin'oka T, Kurosawa H. Subaortic stenosis associated with systolic anterior motion. *Heart Vessels* 2008;23:436-9.
- [29] Zurick AO III, Menon V. Dynamic outflow tract obstruction in congenitally corrected transposition of the great arteries. *Int J Cardiovasc Imaging* 2010;26:617-9.
- [30] Xu J, Wen J, Shu L, Liu C, Zhang J, Zhao W. Mechanism and correlated factors of SAM phenomenon after aortic valve replacement. *J Huazhong Univ Sci Technolog Med Sci* 2007;27:72-4.
- [31] Routledge T, Nashef SA. Severe mitral systolic anterior motion complicating aortic valve replacement. *Interact Cardiovasc Thorac Surg* 2005;4:486-7.
- [32] Dorfman TA, Iskandrian AE, Aqel R. An unusual manifestation of Takotsubo cardiomyopathy. *Clin Cardiol* 2008;31:194-200.
- [33] Johnson DE, Gollub SB, Wilson DB, Vacek JL, Dunn M. Systolic anterior motion of the mitral valve as a manifestation of heart transplant rejection. *J Heart Transplant* 1988;7:289-91.
- [34] Jensen MB, Hansen PB, Moller JE, Lund JT. Another pitfall in minimally invasive mitral valve repair. *Ann Thorac Surg* 2007;84:2101-3.
- [35] Maraud L, Gin H, Roudaut R, Aubertin J, Bricaud H. Echocardiographic study of left ventricular function in type 1 diabetes mellitus: hypersensitivity of beta-adrenergic stimulation. *Diabetes Res Clin Pract* 1991;11:161-8.
- [36] Heinein MY, O'Sullivan C, Sutton GC, Gibson DG, Coats AJ. Stress-induced left ventricular outflow tract obstruction: a potential cause of dyspnea in the elderly. *J Am Coll Cardiol* 1997;30:1301-7.
- [37] Haley JH, Sinak LJ, Tajik AJ, Ommen SR, Oh JK. Dynamic left ventricular outflow tract obstruction in acute coronary syndromes: an important cause of new systolic murmur and cardiogenic shock. *Mayo Clin Proc* 1999;74:901-6.
- [38] Luckner G, Margreiter J, Jochberger S, Mayr V, Luger T, Voelckel W *et al.* Systolic anterior motion of the mitral valve with left ventricular outflow tract obstruction: three cases of acute perioperative hypotension in non-cardiac surgery. *Anesth Analg* 2005;100:1594-8.
- [39] Guarise A, Faccioli N, Foti G, Da PS, Meneghetti P, Morana G. Role of echocardiography and cardiac MRI in depicting morphological and functional imaging findings useful for diagnosing hypertrophic cardiomyopathy. *Radiol Med* 2011;116:197-210.
- [40] Mahmood F, Swaminathan M. Systolic anterior motion and mitral valve reserve function: which one should we care about? *J Cardiothorac Vasc Anesth* 2010;24:885-6.
- [41] Freeman WK, Schaff HV, Khandheria BK, Oh JK, Orszulak TA, Abel MD *et al.* Intraoperative evaluation of mitral valve regurgitation and repair by transesophageal echocardiography: incidence and significance of systolic anterior motion. *J Am Coll Cardiol* 1992;20:599-609.
- [42] Jungwirth B, Adams DB, Mathew JP, Swaminathan M, Glower DD, Mackensen GB. Mitral valve prolapse and systolic anterior motion illustrated by real time three-dimensional transesophageal echocardiography. *Anesth Analg* 2008;107:1822-4.
- [43] Kerut EK. Novel application of tissue Doppler imaging: a preliminary observational study. *Echocardiography* 1998;15:553-62.
- [44] Crescenzi G, Landoni G, Zangrillo A, Guarracino F, Rosica C, La CG *et al.* Management and decision-making strategy for systolic anterior motion after mitral valve repair. *J Thorac Cardiovasc Surg* 2009;137:320-5.
- [45] Sorrell VL, Habibzadeh MR, Kalra N, Chitwood WR. Transient severe mitral regurgitation after mitral valve repair is associated with a poor clinical outcome: a small case series. *Echocardiography* 2008;25:835-9.
- [46] Quigley RL. Prevention of systolic anterior motion after repair of the severely myxomatous mitral valve with an anterior leaflet valvuloplasty. *Ann Thorac Surg* 2005;80:179-82.
- [47] Quigley RL, Garcia FC, Badawi RA. Prevention of systolic anterior motion after mitral valve repair with an anterior leaflet valvuloplasty. *J Heart Valve Dis* 2004;13:927-30.
- [48] Raney AA, Shah PM, Joyo CI. The 'Pomeroy procedure': a new method to correct post-mitral valve repair systolic anterior motion. *J Heart Valve Dis* 2001;10:307-11.
- [49] Carpentier A. The sliding leaflet technique. *Le Club Mitral Newsletter* 1998.
- [50] Gillinov AM, Cosgrove DM III. Modified sliding leaflet technique for repair of the mitral valve. *Ann Thorac Surg* 1999;68:2356-7.
- [51] Perier P, Clausnizer B, Mistarz K. Carpentier 'sliding leaflet' technique for repair of the mitral valve: early results. *Ann Thorac Surg* 1994;57:383-6.
- [52] George KM, Gillinov AM. Posterior leaflet shortening to correct systolic anterior motion after mitral valve repair. *Ann Thorac Surg* 2008;86:1699-700.
- [53] Gillinov AM, Smedira NG, Shiota T. Use of the Alfieri edge-to-edge technique to eliminate left ventricular outflow tract obstruction caused by mitral systolic anterior motion. *Ann Thorac Surg* 2004;78:e92-3.
- [54] Mascagni R, Al AN, Lamarra M, Calvi S, Tripodi A, Mebazaa A *et al.* Edge-to-edge technique to treat post-mitral valve repair systolic anterior motion and left ventricular outflow tract obstruction. *Ann Thorac Surg* 2005;79:471-3.
- [55] Pereda D, Topilsky Y, Nishimura RA, Park SJ. Asymmetric Alfieri's stitch to correct systolic anterior motion after mitral valve repair. *Eur J Cardiothorac Surg* 2011;39:779-81.
- [56] Suri RM, Burkhardt HM, Schaff HV. A novel method of leaflet reconstruction after triangular resection for posterior mitral valve prolapse. *Ann Thorac Surg* 2010;89:e53-6.
- [57] Kudo M, Yozu R, Kokaji K, Kimura N. A simple method of prevention for systolic anterior motion in mitral valve repair by loop technique method. *Ann Thorac Surg* 2009;87:324-5.
- [58] Sternik L, Zehr KJ. Systolic anterior motion of the mitral valve after mitral valve repair: a method of prevention. *Tex Heart Inst J* 2005;32:47-9.
- [59] Massaccesi S, Mancinelli G, Munch C, Catania S, Iacobone G, Piccoli GP. Functional systolic anterior motion of the mitral valve due to accessory chordae. *J Cardiovasc Med (Hagerstown)* 2008;9:105-8.
- [60] Athanasiou T, Chow A, Rao C, Aziz O, Siannis F, Ali A *et al.* Preservation of the mitral valve apparatus: evidence synthesis and critical reappraisal of surgical techniques. *Eur J Cardiothorac Surg* 2008;33:391-401.
- [61] Nakamura T, Shibukawa T, Kawamoto J, Mochiduki S. Transaortic correction of systolic anterior motion of the mitral leaflet after aortic and mitral valve replacement. *Ann Thorac Surg* 2010;89:1287-8.
- [62] Zegdi R, Sleilaty G, Latremouille C, Berrebi A, Carpentier A, Deloche A *et al.* Reoperation for failure of mitral valve repair in degenerative disease: a single-center experience. *Ann Thorac Surg* 2008;86:1480-4.
- [63] Maron BJ, Peterson EE, Maron MS, Peterson JE. Prevalence of hypertrophic cardiomyopathy in an outpatient population referred for echocardiographic study. *Am J Cardiol* 1994;73:577-80.
- [64] Izgi C, Akgun T, Men EE, Feray H. Systolic anterior motion of the mitral valve in the absence left ventricular hypertrophy: role of mitral leaflet elongation and papillary muscle displacement. *Echocardiography* 2010;27:E36-8.
- [65] Lefebvre XP, He S, Levine RA, Yoganathan AP. Systolic anterior motion of the mitral valve in hypertrophic cardiomyopathy: an in vitro pulsatile flow study. *J Heart Valve Dis* 1995;4:422-38.

- [66] Jiang L, Levine RA, King ME, Weyman AE. An integrated mechanism for systolic anterior motion of the mitral valve in hypertrophic cardiomyopathy based on echocardiographic observations. *Am Heart J* 1987;113:633-44.
- [67] Kim DH, Handschumacher MD, Levine RA, Choi YS, Kim YJ, Yun SC *et al.* In vivo measurement of mitral leaflet surface area and subvalvular geometry in patients with asymmetrical septal hypertrophy: insights into the mechanism of outflow tract obstruction. *Circulation* 2010;122:1298-307.
- [68] Hwang HJ, Choi EY, Kwan J, Kim SA, Shim CY, Ha JW *et al.* Dynamic change of mitral apparatus as potential cause of left ventricular outflow tract obstruction in hypertrophic cardiomyopathy. *Eur J Echocardiogr* 2011;12:19-25.
- [69] Lin CS, Chen KS, Lin MC, Fu MC, Tang SM. The relationship between systolic anterior motion of the mitral valve and the left ventricular outflow tract Doppler in hypertrophic cardiomyopathy. *Am Heart J* 1991;122:1671-82.
- [70] Spirito P, Maron BJ. Patterns of systolic anterior motion of the mitral valve in hypertrophic cardiomyopathy: assessment by two-dimensional echocardiography. *Am J Cardiol* 1984;54:1039-46.
- [71] Alam M, Dokainish H, Lakkis N. Alcohol septal ablation for hypertrophic obstructive cardiomyopathy: a systematic review of published studies. *J Interv Cardiol* 2006;19:319-27.
- [72] Shaff HV, Brown ML, Dearani JA, Abel MD, Ommen SR, Sorajja P *et al.* Apical myectomy: a new surgical technique for management of severely symptomatic patients with apical hypertrophic cardiomyopathy. *J Thorac Cardiovasc Surg* 2010;140:634-40.
- [73] Brinster DR, Unic D, D'Ambra MN, Nathan N, Cohn LH. Midterm results of the edge-to-edge technique for complex mitral valve repair. *Ann Thorac Surg* 2006;81:1612-7.
- [74] Delmo Walter EM, Siniawski H, Hetzer R. Sustained improvement after combined anterior mitral valve leaflet retention plasty and septal myectomy in preventing systolic anterior motion in hypertrophic obstructive cardiomyopathy in children. *Eur J Cardiothorac Surg* 2009;36:546-52.
- [75] McIntosh CL, Maron BJ, Cannon RO III, Klues HG. Initial results of combined anterior mitral leaflet plication and ventricular septal myotomy-myectomy for relief of left ventricular outflow tract obstruction in patients with hypertrophic cardiomyopathy. *Circulation* 1992;86:1160-7.
- [76] Adams DH, Anyanwu AC, Rahmanian PB, Abascal V, Salzberg SP, Filsoufi F. Large annuloplasty rings facilitate mitral valve repair in Barlow's disease. *Ann Thorac Surg* 2006;82:2096-100.
- [77] Mesana T, Ibrahim M, Hynes M. A technique for annular plication to facilitate sliding plasty after extensive mitral valve posterior leaflet resection. *Ann Thorac Surg* 2005;79:720-2.
- [78] Balam SK, Tyrie L, Sherrid MV, Afthinos J, Hillel Z, Winson G *et al.* Resection-plication-release for hypertrophic cardiomyopathy: clinical and echocardiographic follow-up. *Ann Thorac Surg* 2008;86:1539-44.
- [79] Seeburger J, Passage J, Borger MA, Mohr FW. A new concept for correction of systolic anterior motion and mitral valve regurgitation in patients with hypertrophic obstructive cardiomyopathy. *J Thorac Cardiovasc Surg* 2010;140:481-3.