JACC: CARDIOVASCULAR INTERVENTIONS
VOL. 11, NO. 6, 2018

PUBLISHED BY ELSEVIER

STATE-OF-THE-ART REVIEW

Cerebral Embolic Risk During Transcatheter Mitral Valve Interventions

An Unaddressed and Unmet Clinical Need?

Matteo Pagnesi, MD,[a] Damiano Regazzoli, MD,[a] Marco B. Ancona, MD,[a] Antonio Mangieri, MD,[a] Giuseppe Lanzillo, MD,[a] Francesco Giannini, MD,[a,b] Nicola Buzzatti, MD,[c] Bernard D. Prendergast, MD,[d] Susheel Kodali, MD,[e] Alexandra J. Lansky, MD,[f,g] Antonio Colombo, MD,[a,b,h] Azeem Latib, MD[a,b]

ABSTRACT

As new transcatheter mitral valve (MV) interventions continuously evolve, potential procedure-related adverse events demand careful investigation. The risk of cerebral embolic damage is ubiquitous in any left-sided structural heart intervention (and potentially linked to long-term neurocognitive sequelae); therefore, efforts to evaluate these aspects in the field of catheter-based MV procedures are justified. Given the peculiarities of MV anatomy, MV disease, and MV procedures, the lessons learned from other transcatheter heart interventions (i.e., transcatheter aortic valve replacement) cannot be directly translated to MV applications. Through a systematic assessment of available evidence, the authors present and discuss procedure- and patient-related factors potentially associated with cerebral embolic risk during catheter-based MV interventions. Given the paucity of available data in this field, future large, dedicated studies are needed to understand whether cerebral embolic injury represents a real clinical issue during MV procedures. (J Am Coll Cardiol Intv 2018;11:517–28) © 2018 by the American College of Cardiology Foundation.

Mitral valve (MV) disease is the most common heart valve disorder, and its most frequent manifestation, mitral regurgitation (MR), affects more than 10% of subjects above the age of 75 years (1). Although open-heart surgery represents the gold standard for the treatment of severe MR, transcatheter MV interventions are emerging as less-invasive options for patients who are inoperable or at high surgical risk (2). These new percutaneous techniques allow both repair/replacement of the native diseased MV and replacement of a degenerating surgical bioprosthesis or failed annuloplasty.

Over the past 10 years, transcatheter aortic valve replacement (TAVR) has become established as a valuable catheter-based option for patients with

From the [a]Interventional Cardiology Unit, San Raffaele Scientific Institute, Milan, Italy; [b]Interventional Cardiology Unit, EMO-GVM Centro Cuore Columbus, Milan, Italy; [c]Department of Cardiovascular and Thoracic Surgery, San Raffaele Scientific Institute, Milan, Italy; [d]Department of Cardiology, St Thomas' Hospital, London, United Kingdom; [e]Division of Cardiology, Columbia University Medical Center, New York, New York; [f]Division of Cardiovascular Medicine and Yale Cardiovascular Research Group, Yale University School of Medicine, New Haven, Connecticut; [g]Department of Cardiology, St Bartholomew's Hospital and William Harvey Research Institute and Queen Mary University of London, London, United Kingdom; and the [h]Vita-Salute San Raffaele University, Milan, Italy. Dr. Prendergast has received research funding from Edwards Lifesciences; and speaker fees from Edwards Lifesciences, Boston Scientific, MVRx, and Symetis. Dr. Kodali has served as a consultant for Medtronic, Claret Medical, and Edwards Lifesciences; is the principal investigator of the SENTINEL trial, sponsored by Claret Medical; has served on the advisory boards of Thubrikar Aortic Valve and Dura Biotech; has received research support and travel reimbursement from Edwards Lifesciences, Claret Medical, and Medtronic; and holds equity in Thubrikar Aortic Valve (minimal) and Dura Biotech. Prof. Lansky has received research support from Keystone Heart, NeuroSave Inc., and Boston Scientific; and has received speaker/consultant fees from Keystone Heart. Dr. Latib has served on the advisory boards of Medtronic and Millipede; has received honoraria from Abbott Vascular; and has served as a consultant for Medtronic, Millipede, Valtech Cardio, MitralTech, Innovative Cardiovascular Solutions, Keystone Medical, and Mitralign. All other authors have reported that they have no relationships relevant to the contents of this paper to disclose.

Manuscript received August 30, 2017; revised manuscript received November 4, 2017, accepted December 12, 2017.

ISSN 1936-8798/$36.00
https://doi.org/10.1016/j.jcin.2017.12.018

JACC: CARDIOVASCULAR INTERVENTIONS VOL. 11, NO. 6, 2018
MARCH 26, 2018:517–28

ABBREVIATIONS AND ACRONYMS

AF = atrial fibrillation

CEP = cerebral embolic protection

DW-MRI = diffusion-weighted magnetic resonance imaging

MAC = mitral annular calcification

MoCA = Montreal Cognitive Assessment

MR = mitral regurgitation

MV = mitral valve

TAVR = transcatheter aortic valve replacement

THV = transcatheter heart valve

TMVI = transcatheter mitral valve implantation

TMVR = transcatheter mitral valve repair

VIR = valve-in-ring

VIV = valve-in-valve

severe aortic stenosis. Rationally, lessons learned during this "TAVR revolution" should be strongly considered when approaching MV treatment and should guide future evaluation of percutaneous MV therapies. As with any other cardiac endovascular procedure, catheter-based MV interventions may be associated with overt or covert cerebral injury, the latter being more frequent and likely linked with long-term neurocognitive disturbances (3,4). Besides the risk of clinically apparent neurological events (5), silent cerebral infarcts are present in the majority of patients (75% to 80%) undergoing TAVR (6); furthermore, when performing TAVR with filter-based cerebral embolic protection (CEP) devices, embolic debris is captured in most (90% to 95%) patients (7,8). These observations should not be overlooked when moving to transcatheter MV procedures, as similar risks are likely associated with any left-sided structural heart intervention.

The aim of this review is intended to analyze and discuss the available evidence concerning cerebral embolic injury during transcatheter MV interventions (repair, replacement, valve-in-valve [VIV], and valve-in-ring [VIR]) in an effort to better understand this potential future clinical need.

TRANSCATHETER MITRAL VALVE REPAIR

Edge-to-edge transcatheter mitral valve repair (TMVR) with the MitraClip device (Abbott Vascular, Menlo Park, California) is the most widely adopted catheter-based strategy to treat MR, with more than 40,000 patients treated worldwide. **Figure 1** shows the rate of clinically overt stroke at short-term (in-hospital or 30-day) follow-up reported in major MitraClip studies (9–17). Details of these studies are reported in **Table 1**. Reported clinically apparent stroke occurs in a very small percentage of patients after MitraClip implantation, with rates ranging from 0.2% to 1.2% and 0.7% to 2.6% for in-hospital and 30-day stroke, respectively.

COVERT CENTRAL NERVOUS SYSTEM INJURY DETECTED BY NEUROIMAGING. Despite the low rate of clinically overt stroke after MitraClip implantation, the risk of covert central nervous system injury detected by neuroimaging (according to the recent definition of the Neurologic Academic Research Consortium [18]) is not negligible. Indeed, a recent study by Blazek et al. (19) evaluated the incidence and features of new cerebral embolic lesions detected by brain diffusion-weighted magnetic resonance imaging (DW-MRI) after MitraClip implantation. This prospective, single-center study included 27 patients with severe, symptomatic MR (functional MR in 67%) undergoing TMVR with the MitraClip device and DW-MRI within 2 days before and 2 to 6 days after the procedure. The study population represented a high-risk cohort with multiple comorbidities (most notably atrial fibrillation [AF] in 67%). Interestingly, new DW-MRI lesions were observed in 23 patients (86%), with 19 (70%) showing multiple lesions in different neurovascular territories of both cerebral hemispheres, strongly suggesting an embolic mechanism. Device time (a marker of procedural complexity) independently predicted a higher number of new lesions in multivariate analysis. No patients showed a significant decline in post-procedural neurocognitive function (as assessed by the Montreal Cognitive Assessment [MoCA] score) compared with baseline; furthermore, although MV calcification on echocardiography and the presence of >3 new DW-MRI lesions were univariate predictors of lower post-procedural MoCA score, pre-procedural MoCA score was the only independent predictor after multivariate analysis. The lack of statistical significance may be related to the small number of patients; nevertheless, this study did not identify a clear relationship between new brain DW-MRI lesions after MitraClip and early neurocognitive impairment.

The study by Blazek et al. (19) allows us to perform a comparison between cerebral DW-MRI lesions detected after MitraClip and those (more extensively studied) after TAVR (6). As shown in **Table 2**, new cerebral lesions are very common after both procedures (MitraClip 86%, TAVR 77.5%) with similar numbers of new lesions per patient. Although such lesions seem to affect both cerebral hemispheres more frequently after MitraClip, total lesion volume is higher after TAVR.

HISTOPATHOLOGIC ANALYSIS OF DEBRIS CAPTURED BY CEP SYSTEMS. An elegant means of investigating neurological risk during transcatheter heart interventions is provided by histopathologic analysis of debris captured by CEP filters used during the procedure. Detailed analysis of debris traveling to the brain allows a logical understanding of the pathophysiology of procedure-related cerebral embolic phenomena. In this context, the recent pioneering study by Frerker et al. (20) reports the first experience of CEP during MitraClip implantation and provides histopathologic analysis of embolic debris potentially responsible for cerebrovascular damage. This

FIGURE 1 In-Hospital and 30-Day Overt Stroke Rates Reported in Major MitraClip Studies

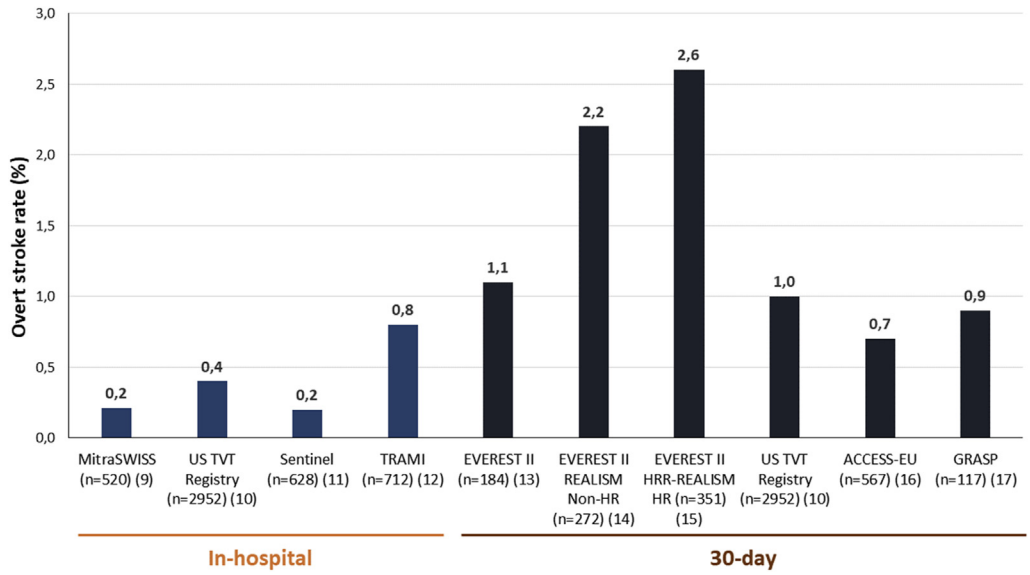

Overt stroke rates were derived from one randomized controlled trial (EVEREST II) and 8 landmark registries. Both published data and data presented at relevant scientific meetings are reported. ACCESS-EU = ACCESS-Europe A Two-Phase Observational Study of the MitraClip System in Europe; EVEREST = Endovascular Valve Edge-to-Edge Repair Study; GRASP = Getting Reduction of Mitral Insufficiency by Percutaneous Clip Implantation; HR = High Risk; HRR = High Risk Registry; REALISM = Real World Expanded Multicenter Study of the MitraClip System; TRAMI = Transcatheter Mitral Valve Interventions; TVT = Transcatheter Valve Therapy.

TABLE 1 Major Studies Evaluating TMVR With the MitraClip Device

					MV Pathology						
Study (Ref.#)	Study Design	N	Age (yrs)	STS Score (%)	DMR (%)	FMR (%)	Mixed (%)	Other/ Indeterminate (%)	LVEF (%)	Mortality (In-Hospital/ 30-Day) (%)	Stroke (In-Hospital/ 30-Day) (%)
MitraSwiss (9)	Retrospective Multicenter	520	79 (71–84)	5.4 (3.0–11.5)	40	52.6	7.4	–	48 (32–60)	0.4 3.2	0.21 –
US TVT registry (10)	Prospective Multicenter	2,952	82 [74–86]	6.1 [3.7–9.9]	85.9	8.6	8.9	2.8	55 [40–60]	2.7 5.2	0.4 1.0
TCVT Sentinel Pilot registry (11)	Prospective Multicenter	628	74 ± 10	–	22.8	72.0	2.7	2.5	43 ± 16	2.9 –	0.2 –
German TRAMI registry (12)	Prospective Multicenter	749	76 [71–81]	6.0 (4.0–11.0)	27.8	71.3	–	0.9	–	2.4 4.5	0.8 –
EVEREST II trial (13)	RCT Multicenter	184	67 ± 13	–	73.4	26.6	–	–	60 ± 10	– 1.1	– 1.1
EVEREST II REALISM Non-HR arm (14)	Prospective Multicenter	272	74 ± 11	–	69	31	–	–	56 ± 11	– 1.5	– 2.2
EVEREST II HRR + REALISM HR arm (15)	Prospective Multicenter	351	76 ± 11	11.3 ± 7.7	29.9	70.1	–	–	48 ± 14	– 4.8	– 2.6
ACCESS-EU registry (16)	Prospective Multicenter	567	74 ± 10	–	20.6	69.3	–	10.1	–	– 3.4	– 0.7
GRASP registry (17)	Prospective Single-center	117	72 ± 10	–	24	76	–	–	38 ± 13	– 0.9	– 0.9

Values are mean ± SD, median (range), or median [interquartile range].

ACCESS-EU = ACCESS-Europe A Two-Phase Observational Study of the MitraClip System in Europe; DMR = degenerative mitral regurgitation; EVEREST = Endovascular Valve Edge-to-Edge Repair Study; FMR = functional mitral regurgitation; GRASP = Getting Reduction of Mitral Insufficiency by Percutaneous Clip Implantation; HR = High Risk; HRR = High Risk Registry; LVEF = left ventricular ejection fraction; MV = mitral valve; REALISM = Real World Expanded Multicenter Study of the MitraClip System; RCT = randomized controlled trial; STS = Society of Thoracic Surgeons; TCVT = Transcatheter Valve Treatment Sentinel Pilot Registry; TMVR = transcatheter mitral valve repair; TRAMI = Transcatheter Mitral Valve Interventions; TVT = Transcatheter Valve Therapy.

JACC: CARDIOVASCULAR INTERVENTIONS VOL. 11, NO. 6, 2018
MARCH 26, 2018:517–28

TABLE 2 Comparison of Overt/Covert Cerebral Injury and Debris Captured by Cerebral Embolic Protection Filters in Patients Undergoing TMVR (MitraClip) vs. TAVR

	MitraClip	TAVR
Overt CNS injury		
30-day stroke rate	0.5%–2.5%	3%–6%
MRI-detected CNS injury (6,19)		
Total lesion volume, mm^3	107.7 [30.7–303.0]	437.5 (286.7–588.3)*
New lesions per patient, n	3.0 [1.0–9.0]	4.2 (3.4–5.0)*
Patients with new lesions	23/27 (85.7)	785/1043 (77.5)*
Patients with lesions in both cerebral hemispheres	19/27 (70.4)	78/207 (37.8)*
Debris captured by CEP filters (7,8,20)		
Presence of debris	14/14 (100)	70/81 (86) 156/161 (97)
Size of debris	295 μm [104–509]	1 mm [0.6–1.5] –
Thrombotic material/procedural ACT	12/14 (86)/289 ± 48 s	60/81 (74)/230 ± 68 s 147/161 (91)/315 ± 54 s
Any tissue	11/14 (79)	51/81 (63) –
MV/atrial wall tissue vs. AV tissue	9/14 (64)	27/81 (33) 85/161 (53)
Arterial wall	0/14 (0)	– 109/161 (68)
Myocardium	2/14 (14)	13/81 (16) –
Calcification	0/14 (0)	20/81 (25) 74/161 (46)
Foreign material	12/14 (86)	8/81 (10) 49/161 (30)

Values are range, median [interquartile range], n/N (%), mean ± SD, or mean (95% confidence interval), except as noted. *Pooled estimate rates obtained from a weighted meta-analysis of published studies.

ACT = activated clotting time; AV = atrial valve; CEP = cerebral embolic protection; CNS = cerebral nervous system; MRI = magnetic resonance imaging; TAVR = transcatheter aortic valve implantation; other abbreviations as in Table 1.

2-center safety and feasibility study included 14 patients undergoing the MitraClip procedure with the dual-filter Sentinel CEP system (Claret Medical, Santa Rosa, California) in situ. All patients had severe MR (functional MR in 79%) and a high-risk profile (AF in 57%). All procedures were successfully completed, demonstrating that CEP during MitraClip implantation is feasible and safe. Interestingly, debris was identified in all 14 patients and all 28 filters (14 proximal and 14 distal), with larger debris in patients treated with 2 clips versus 1 clip (maximum particle diameter 402 μm [interquartile range: 275 to 589 μm] vs. 134 μm [interquartile range: 56 to 336 μm]; $p < 0.0001$). The most commonly identified material was acute thrombus and nonpolarizable basophilic foreign body (hydrogel)—each found in 86% of patients. The formation of acute thrombus may be associated with several steps/materials used during the procedure (transseptal sheath, MitraClip guide catheter or delivery systems, but also insertion, placement, or removal of CEP filters) and promoted by longer procedural/device time (leading to transient phases of suboptimal anticoagulation). The foreign material probably derives from the transseptal sheath (21) or MitraClip delivery system, and not from CEP filters (the authors stated that they manually scraped the surface of filters, not observing such material at microscopy). Other identified debris was as follows: valve/atrial tissue (64%); chronic organizing thrombus (29%), probably ascribable to the high prevalence of AF; and myocardium (14%). Notably, no calcific debris was identified, a finding that may be explained by the inclusion of patients mainly affected by functional MR.

Comparison between the study of Frerker et al. (20) and 2 TAVR studies (7,8) demonstrates that debris is captured by filters in the vast majority of patients undergoing both MitraClip and TAVR procedures (Table 2). Debris captured during MitraClip implantation seem to be smaller and more frequently composed of foreign material, whereas thrombotic material and debris derived from the valve or surrounding tissue seem to be captured with equal frequency during both procedures. Given the degenerative nature of aortic stenosis, calcium particles were frequently detected in TAVR studies, whereas Frerker et al. (20) did not identify such particles in any patient (probably reflecting the predominance of patients with functional rather than degenerative MR).

TMVR INTERVENTIONS OTHER THAN MITRACLIP. Table 3 summarizes all studies evaluating TMVR systems other than MitraClip and demonstrates that reported rates of clinically overt stroke are very low (22–32). These TMVR devices are illustrated in Figure 2. Although coronary sinus annuloplasty approaches (Carillon and cerclage) could carry a lower risk of device-related cerebral embolism (because there is no direct access to left-sided heart structures), any TMVR procedure may theoretically be associated with periprocedural cerebrovascular injury. However, given the low number of treated patients and the paucity of data regarding neurological events, no definitive conclusion can be derived yet for these new TMVR procedures.

TRANSCATHETER MITRAL VALVE IMPLANTATION

The success of TAVR during the last decade and the ensuing hope of finding an effective catheter-based solution for MR have generated considerable interest in new transcatheter heart valves (THVs) specifically designed for replacement of the native MV. Several dedicated transcatheter MV implantation

TABLE 3 Studies Evaluating TMVR Systems Other Than MitraClip

Study (Ref. #)	Device	Study Design	N	Approach	Age (yrs)	STS Score (%)	MV Pathology			LVEF (%)	Mortality (In-Hospital/ 30-Day) (%)	Stroke (In-Hospital/ 30-Day) (%)
							DMR (%)	FMR (%)	Mixed (%)			
Cardioband Mitral CE Mark trial (22)	Cardioband	Prospective Multicenter	61	TV-TS	72 ± 7	–	–	100	–	33 ± 11	– 3.3	– 1.6
Mitralign FIM study (23)	Mitralign	Prospective Multicenter	45	TF	68 ± 13	5.7 ± 5.2	–	100	–	35 ± 8	– 4.4	– 4.4
MAVERIC study (24)	ARTO	Prospective Multicenter	45	TV-TS	70 ± 12	3.8 ± 3.4	–	100	–	40 ± 9	0 0	0 0
NeoChord International Registry (25)	NeoChord	Retrospective Multicenter	192	TA	66 [55-76]	0.8 [0.3-1.6]	100	–	–	60 [55-66]	1.6 –	0 –
TACT registry (26)	NeoChord	Prospective Multicenter	68	TA	66 ± 13	1.6	100	–	–	61 ± 7	– 2.9	– 1.5
TACT trial (27)	NeoChord	Prospective Multicenter	30	TA	63.5 ± 11.9	–	100	–	–	59 ± 5	– 3.3	– 3.3
Colli et al. 2016 (28)	NeoChord	Prospective Single-center	49	TA	72 [58-78]	1.4 [0.5-2.5]	100	–	–	65 [58-68]	2.0 2.0	0 0
Park et al. 2017 (29)	Cerclage	Prospective Single-center	5	TSub/TF	70 ± 5	6.0 ± 2.6	–	100	–	51 ± 14	0 0	0 0
AMADEUS trial (30)	Carillon	Prospective Multicenter	48	TJ	64 (25-81)	–	–	100	–	29 (10–39)	– 2.2	NA
TITAN trial (31)	Carillon	Prospective Multicenter	53	TJ	62 ± 13	–	–	100	–	28 ± 8	– 1.9	NA
TITAN II trial (32)	Carillon	Prospective Multicenter	36	TJ	71 ± 9	–	–	100	–	34 ± 10	– 2.8	NA

Values are mean ± SD, median [interquartile range], or median (range).

AMADEUS = CARILLON Mitral Annuloplasty Device European Union Study; CE = Conformité Européenne; FIM = first-in-man; MAVERIC = Mitral Valve Repair Clinical Trial; NA = not available; TA = transapical; TACT = Transapical Artificial Chordae Tendinae; TF = transfemoral; TITAN = Transcatheter Implantation of Carillon Mitral Annuloplasty Device; TJ = transjugular; TSub = transsubclavian; TV-TS = transvenous-transseptal; other abbreviations as in Table 1.

(TMVI) devices for both degenerative and functional MR are in development or undergoing evaluation in early feasibility studies (Figure 2). Intuitively, MV replacement seems likely to be more traumatic to the valve apparatus than MV repair, and it could therefore be expected that TMVI would be associated with a higher risk of embolizing debris to the brain. As shown in Table 4, current experience with specific TMVI devices remains at a very early stage, hence the numbers of treated patients and clinically overt strokes are too low to draw valid conclusions (33-39).

Notwithstanding these considerations, insights can be gained from the study of Guerrero et al. (40). This multicenter registry evaluated the performance of THVs designed for TAVR in the treatment of severe native MV disease (mainly mitral stenosis) and concomitant severe mitral annular calcification (MAC). Considering the complexity of the procedure and extremely high-risk profile of the study population, which included 64 inoperable patients, the relatively high rates of procedural complications (20%) and 30-day mortality (30%) were not unexpected. Although the in-hospital stroke rate was relatively high (6.9%), the low number of events (4 strokes in 58 patients) prevent us from drawing robust conclusions on cerebral injury in this population. The placement and implantation of a THV in a heavily calcified MV apparatus could theoretically enhance the cerebral embolic risk during the procedure; interestingly, left-sided cardiac annular and valve calcification has been associated with covert brain infarcts (41), and MAC has been specifically reported to be a strong risk factor for incident stroke (42,43). However, only future studies specifically focusing on neurological endpoints will help us understanding whether MV calcification or other factors increase the risk of cerebral embolism during TMVI procedures.

TRANSCATHETER MITRAL VIV OR VIR IMPLANTATION

Although open-heart surgical reintervention represents the standard of care in patients with degenerating mitral bioprosthetic valves or annuloplasty rings, redo surgery is associated with significant risk of mortality and morbidity. Transcatheter mitral VIV and VIR procedures are therefore developing as valuable options for patients who are elderly or at high or unacceptable surgical risk. Studies evaluating mitral VIV and VIR are summarized in Table 5 (44-59).

FIGURE 2 Overview of Devices Specifically Designed for TMVR and TMVI

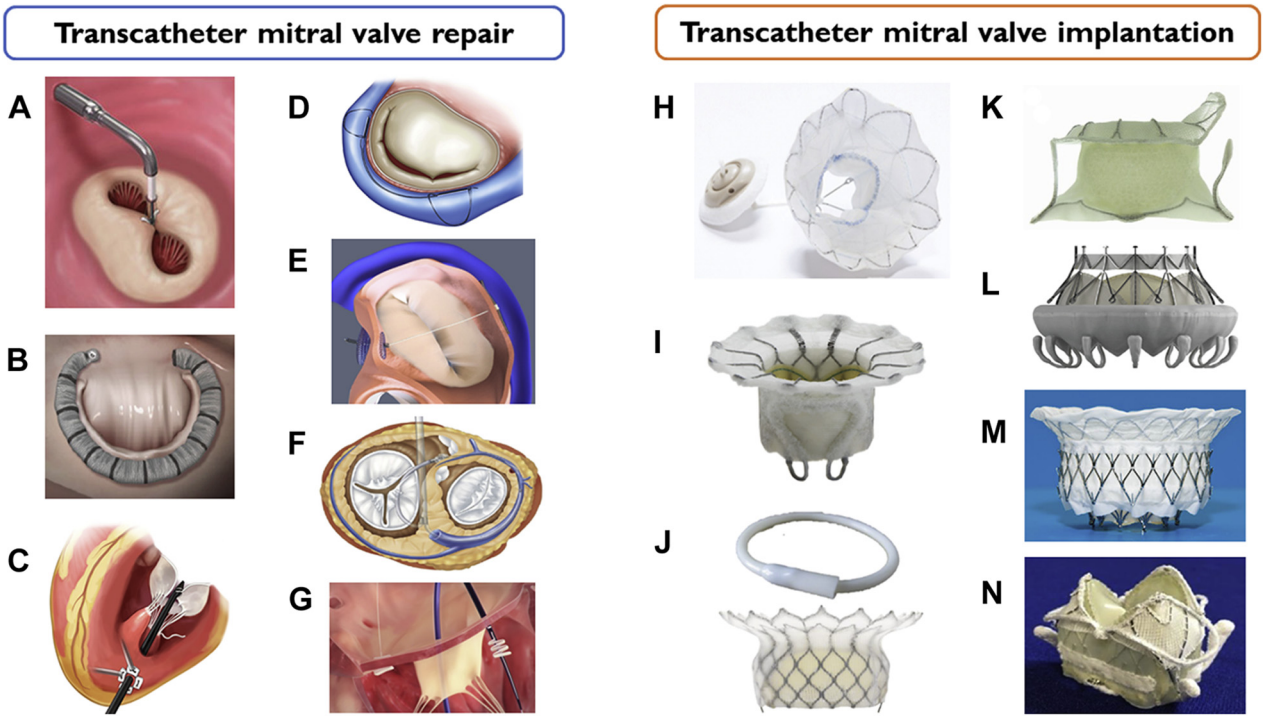

New percutaneous technologies for MV repair **(A-G)** and MV replacement **(H-N)** are under clinical evaluation: (A) MitraClip (Abbott Vascular); **(B)** Cardioband (Edwards Lifesciences, Irvine, California); **(C)** NeoChord DS1000 (NeoChord, Minneapolis, Minnesota); **(D)** Carillon (Cardiac Dimensions, Kirkland, Washington); **(E)** ARTO (MVRx, Belmont, California); **(F)** Mitral Loop Cerclage (Tau-PNU Medical Company, Pusan, Korea); **(G)** Mitralign (Mitralign, Tewksbury, Massachusetts); **(H)** Tendyne (Tendyne Holdings, a subsidiary of Abbott Vascular, Roseville, Minnesota); **(I)** Fortis (Edwards Lifesciences); **(J)** HighLife (HighLife Medical, Irvine, California); **(K)** Tiara (Neovasc, Richmond, British Columbia, Canada); **(L)** CardiAQ (Edwards Lifesciences); **(M)** Intrepid (Medtronic, Minneapolis, Minnesota); **(N)** Caisson (Caisson Interventional, Maple Grove, Minnesota). MV = mitral valve; TMVI = transcatheter mitral valve implantation; TMVR = transcatheter mitral valve repair.

The largest experience is represented by the multicenter VIVID (Valve-in-Valve International Data) registry, which includes 437 high-risk patients who underwent transcatheter mitral VIV (n = 349) or VIR (n = 88) (44). VIR was associated with worse procedural and clinical outcomes than VIV (more left ventricular outflow tract obstruction, post-procedural MR, acute kidney injury, and numerically higher overall and cardiovascular 30-day mortality), and the composite endpoint of 30-day survival free from significant MR or clinically evident left ventricular outflow tract obstruction occurred more frequently in patients undergoing VIV (88.8% VIV vs. 71.6% VIR). By contrast, the rate of major procedural stroke was numerically higher during VIV procedures (2.9% VIV vs. 1.1% VIR). Similar findings were observed also in the recent study of Yoon et al. (45), confirming the association between VIR and worse clinical/procedural outcomes, and reporting a numerically higher rate of 30-day stroke after VIV (2.3% VIV vs. 0% VIR). Although the mechanical trauma caused by VIV may theoretically facilitate the mobilization of debris from the MV apparatus and degenerating MV bioprosthesis, the low rate of clinically overt events in reported studies and the paucity of available data prevent reliable conclusions.

Interestingly, Schmidt et al. (60) recently reported a series of 15 patients undergoing transcatheter VIV implantation (13 aortic, 2 mitral) with concomitant use of the dual-filter Montage and Sentinel CEP systems (both Claret Medical). All procedures were successfully completed without CEP-related adverse events, indicating that CEP use during VIV is feasible and safe. At histopathologic analysis, debris was identified in all patients (15 proximal [100%] and 13 distal filters [87%]) and most commonly consisted of acute thrombus (found in all patients). This study supports the hypothesis that VIV, a complex procedure requiring significant manipulation and instrumentation in and adjacent to degenerating, fragile

TABLE 4 Early Experience and Published Studies Evaluating TMVI Devices

Study (Ref. #)	THV	Study Design	N	Approach	Age (yrs)	STS Score (%)	MV Pathology DMR (%)	MV Pathology FMR (%)	MV Pathology Mixed (%)	MV Pathology MS (%)	LVEF (%)	Mortality (In-Hospital/ 30-Day) (%)	Stroke (In-Hospital/ 30-Day) (%)
Tendyne global feasibility trial (33)	Tendyne	Prospective Multicenter	30	TA	76 ± 9	7.3 ± 5.7	10	77	13	–	47 ± 9	3.3 3.3	0 0
TIARA-I early feasibility trial + TIARA-II European CE Mark trial + SAP (34)	Tiara	Prospective Multicenter	37	TA	75 ± 10	9.9 (2.1–47.7)	17	68	16	–	36 ± 10	0 11.8	0 –
Compassionate use experience (35)	Fortis	Retrospective Multicenter	13	TA	71 ± 8	7.2 ± 3.6	–	92	8	–	34 ± 9	30.8 38.5	0 0
Intrepid global pilot study (36)	Intrepid	Prospective Multicenter	50	TA	73 ± 9	6.4 ± 5.5	16	72	12	–	43 ± 12	– 14.0	– 4.0
Safety and feasibility study + compassionate use (37)	HighLife	Prospective Multicenter	11	TF + TA/ TV-TS	69 (50–79)	–	28	72	–	–	35 (20–54)	27.3 27.3	0 0
Compassionate use experience (38)	CardiAQ	Retrospective	12	TA TV-TS	–	–	36	64	–	–	–	50.0	NA
PRELUDE study + SAP (39)	Caisson	Prospective Multicenter	15	TV-TS	79 ± 7	8.1 ± 3.6	14	57	29	–	45 ± 13	– 16.7	NA
TMVR in MAC global registry (40)	5 SAPIEN 38 SAPIEN XT 18 SAPIEN 3 2 Inovare	Retrospective Multicenter	64	26 TV-TS 29 TA 9 TAtr	73 ± 13	14.4 ± 9.5	6.5*			93.5	60 ± 11	– 29.7	6.9 –

Values are mean ± SD or median (range). *MR etiology not specified.

MAC = mitral annular calcification; MS = mitral stenosis; PRELUDE = Percutaneous Mitral Valve Replacement EvaLuation Utilizing IDE Early Feasibility Study; SAP = Special Access Program; TAtr = transatrial; THV = transcatheter heart valve; TIARA-I = Early Feasibility Study of the Neovasc Tiara Mitral Valve System; other abbreviations as in Tables 1 and 3.

bioprosthetic material, may carry significant risk of cerebral embolism—possibly higher than that associated with less complex THV interventions.

VIEWPOINT

As with any other left-sided structural heart intervention, catheter-based MV procedures are likely associated with the risk of cerebral embolic events. Recent studies provide insights into the incidence and mechanisms of cerebral embolic injury during MitraClip implantation: although clinically overt stroke is rare, subclinical neurological events are common (19), and embolic debris traveling to the brain is identified in all investigated patients (20). Several factors seem to be linked with an increased risk of cerebral embolization during MitraClip, including: 1) procedural complexity and duration (procedure time, number of clips implanted); 2) the use of foreign body material; 3) formation of acute thrombus, probably enhanced by transient phases of suboptimal anticoagulation during the procedure and/or by the occurrence of new-onset AF; 4) mobilization of chronic thrombotic material, mainly in patients with pre-existing AF; and 5) small (subclinical) damage to atrial, valvular, or ventricular tissue. Besides the MitraClip, available data concerning the other transcatheter MV interventions are limited and prevent reliable conclusions: the presence of severe mitral annular/valvular calcification and procedural trauma (implantation of a mitral prosthesis, especially in a VIV procedure) may theoretically increase cerebral embolic risk, yet future studies are needed to confirm these hypotheses.

Beyond the discussed potential sources of embolic damage, other factors could conceivably enhance the risk of neurological events during percutaneous MV interventions. Periprocedural hypotensive events, mainly related to the anesthesia management, may favor cerebral ischemic injury. In a recent large TAVR study, general anesthesia was associated with a higher adjusted risk of in-hospital/30-day mortality or stroke compared with conscious sedation (61). Although the safety and feasibility of the MitraClip procedure under deep sedation has been recently reported (62,63), no study to date has specifically focused on the impact of anesthesia management on cerebral events during transcatheter MV interventions. Furthermore, given the complexity of new catheter-based MV procedures and the need for transesophageal echocardiographic

JACC: CARDIOVASCULAR INTERVENTIONS VOL. 11, NO. 6, 2018
MARCH 26, 2018:517–28

TABLE 5 Studies Evaluating Transcatheter Mitral VIV and VIR Procedures

Study (Ref. #)	N	Procedure	Study Design	THV	Approach	Age (yrs)	STS Score (%)	LVEF (%)	Mortality (In-Hospital/ 30-Day) (%)	Stroke (In-Hospital/ 30-Day) (%)
Mitral VIVID registry (44)	437	VIV 349 VIR 88	Retrospective Multicenter	347 Cribier/SAPIEN/XT 28 Melody 17 SAPIEN 3 12 Inovare 3 Direct Flow 3 Lotus	345 TA 81 TV-TS 11 TAtr	VIV 75 ± 12 VIR 69 ± 14	VIV 13.4 ± 12.3 VIR 11.0 ± 8.1	VIV 54 ± 12 VIR 44 ± 17	VIV 7.7 VIR 11.4	VIV 2.9* VIR 1.1*
Yoon et al. 2017 (45)	248	VIV 176 VIR 72	Retrospective Multicenter	24 SAPIEN 93 SAPIEN XT 102 SAPIEN 3 4 Melody 14 Lotus 11 Direct Flow	165 TA 82 TV-TS 1 TAtr	VIV 73 ± 13 VIR 71 ± 10	VIV 9.3 ± 7.0 VIR 8.1 ± 6.2	VIV 55 ± 11 VIR 46 ± 17	VIV 5.7 VIR 8.3	VIV 2.3 VIR 0
Eleid et al. 2016 (46)	48	VIV 33 VIR 9 MS (MAC) 6	Retrospective Multicenter	SAPIEN/XT/S3	TV-TS	76 ± 11	13.2 ± 7.4	56 ± 12	8.3	0
Frerker et al. 2016 (47)	24	VIV 14 VIR 10	Retrospective Single-center	SAPIEN/XT/S3	13 TA 11 TV-TS	72 ± 13	11.2 ± 8.3	49 ± 16	12.5	4.2
Wilbring et al. 2014 (48)	12	VIV 10 VIR 2	Retrospective Single-center	SAPIEN XT	TA	75 ± 5	11.6 ± 3.1	45 ± 17	15.4	0
Schäfer et al. 2014 (49)	12	VIV 8 VIR 4	Case series Single-center	SAPIEN/XT	TA TV-TS	69 ± 13	10.1 ± 5.3	–	0	8.3
Whisenant et al. 2015 (50)	9	VIV 7 VIR 2	Case series Single-center	SAPIEN/XT	7 TA 2 TF	–	–	–	0	0
Bouleti et al. 2015 (51)	17	VIV 6 VIR 11	Single-center	SAPIEN XT	TV-TS	61 ± 24	18.3 ± 21.8	55 ± 12	5.9	0
Ye et al. 2015 (52)	31	VIV	Consecutive patients Single-center	SAPIEN/XT	TA	79 ± 9	9.7 [5.0–16.6]	60 [40–65]	0	3.2†
Cheung et al. 2013 (53)	23	VIV	Consecutive patients Single-center	SAPIEN/XT	TA	81 ± 6	12.6 ± 6.9	55 ± 12	0	4.4
Cullen et al. 2013 (54)	9	VIV	Case series Single-center	Melody	TV-TS	75 ± 11	13.3 ± 5.6	50 ± 18	11.1	0
Seiffert et al. 2012 (55)	6	VIV	Case series Single-center	SAPIEN/XT	TA	74 ± 14	18.8 ± 10.8	56 ± 4	16.7	0
Cerillo et al. 2011 (56)	3	VIV	Case series Single-center	SAPIEN	TA	68 ± 21	15.2 ± 9.3	37 ± 13	33.3	0
Kliger et al. 2015 (57)	5	VIV	Case series Single-center	Melody	TV-TS TA	73 ± 12	15.1 ± 12.1	54 ± 13	0	0
Himbert 2016 (58)	28	VIR	–	SAPIEN XT/S3	TV-TS	67 (38–76)	–	56 ± 9	7.1	0
Descoutures et al. 2013 (59)	17	VIR	Case series Multicenter	SAPIEN XT	8 TV-TS 9 TA	70 ± 16	13.4 ± 8.9	–	11.8	0

Values are mean ± SD, median [interquartile range], or median (range). *Procedural major stroke. †30-day disabling stroke.
VIR = valve-in-ring; VIV = valve-in-valve; VIVID = Valve-in-Valve International Data; other abbreviations as in Tables 1, 3, and 4.

guidance, most interventions will still be performed under general anesthesia until procedural duration is markedly reduced and imaging technology significantly evolves; hence, a large study comparing deep sedation and general anesthesia during new transcatheter MV interventions is unlikely to be performed in the near future.

A factor that may potentially be associated with neurological damage is the presence and extent of prior cerebral injury. The SENTINEL (Cerebral Protection in Transcatheter Aortic Valve Replacement) trial (64) showed that baseline cerebral lesion volume (detected by T2/fluid-attenuated inversion recovery [FLAIR] MRI) was the strongest predictor of new DW-MRI lesions after TAVR, suggesting that prior neurological damage is a crucial risk factor for cerebral injury after catheter-based structural interventions. Hence, baseline cerebral disease burden may play an important role in predicting the occurrence and extent of new neurological injury after percutaneous MV procedures.

Drawing inspiration from available evidence, several procedure- and patient-related factors may be identified that potentially enhance the risk of cerebral embolic injury during percutaneous MV interventions (**Central Illustration**). Future research is needed to

CENTRAL ILLUSTRATION **Cerebral Embolic Risk During Transcatheter MV Interventions**

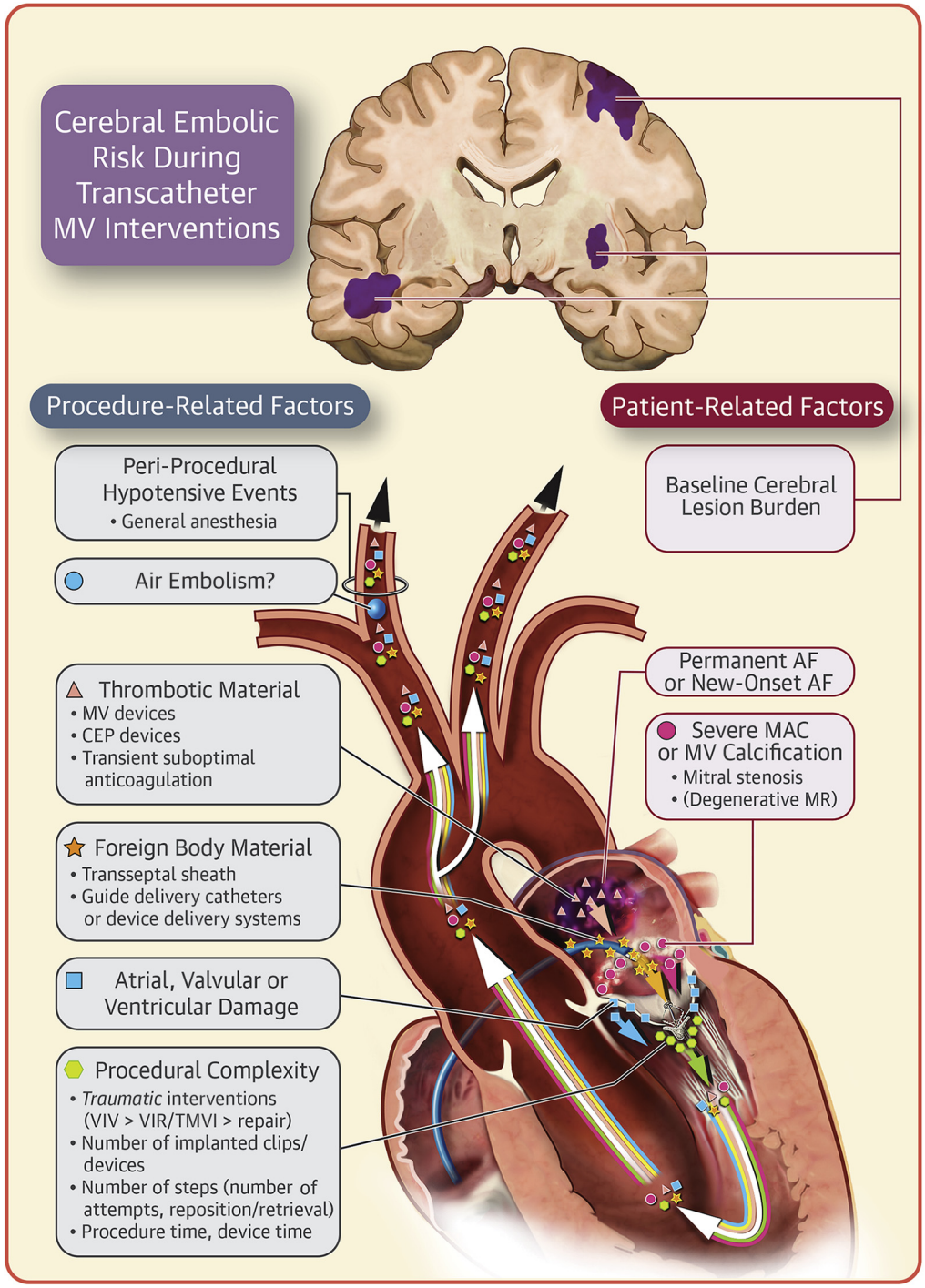

Pagnesi, M. et al. J Am Coll Cardiol Intv. 2018;11(6):517–28.

Several procedure- and patient-related factors may enhance the risk of cerebral embolic damage during catheter-based MV intervention. AF = atrial fibrillation; CEP = cerebral embolic protection; CNS = central nervous system; MAC = mitral annular calcification; MR = mitral regurgitation; MV = mitral valve; SENTINEL = Cerebral Protection in Transcatheter Aortic Valve Replacement; TAVR = transcatheter aortic valve replacement; TMVI = transcatheter mitral valve implantation; VIR = valve-in-ring; VIV = valve-in-valve.

confirm the relevance of these factors, to investigate the relative importance and contribution of each of them, and to provide more insights into the pathophysiological mechanisms of periprocedural cerebral embolic risk.

FUTURE PERSPECTIVES

As the number of patients treated by transcatheter MV interventions increases over time, a complete characterization of the risk of periprocedural cerebral injury cannot be neglected and deserve rightful attention. Dedicated studies evaluating cerebral damage during all MV interventions (TMVI, TMVR, VIV, and VIR) are needed for a full understanding of the risks, mechanisms, and prognostic implications of these procedure-related neurological events.

The Neurologic Academic Research Consortium has recently proposed standardized definitions and assessments for neurological endpoints during cardiovascular clinical trials (18). As reported by this consensus, the full spectrum of neurological injury can be captured only with a careful evaluation of clinically overt events (e.g., stroke), functional impairment (e.g., by means of National Institutes of Health Stroke Scale, modified Rankin Scale, or Barthel Index), and neuroimaging endpoints (e.g., cerebral infarction detected by magnetic resonance imaging). Furthermore, specific recommendations are provided on neurocognitive impairment, because covert cerebral injury may lead to subsequent cognitive decline (64). Global cognitive screening (by means of the simple and fast MoCA score) is strongly recommended for all cardiovascular trials (18); hence, we hope that future dedicated studies on MV interventions will perform it at several time points. A comprehensive neurocognitive assessment can be challenging, especially in older patients in the first few days after the procedure, and is dependent on the time of day and alertness of the patient: an extended battery evaluating several cognitive domains has greater accuracy than a simpler global tool (e.g., MoCA score), but it can cause fatigue and inaccurate results. Large studies including neuroimaging and neurocognitive outcomes will help in defining the occurrence and consequences of cerebral damage during transcatheter MV interventions.

A detailed analysis of all procedure- and patient-related factors potentially associated with neurological injury is also desirable. Beyond the procedural and device-related endpoints recommended by the Mitral Valve Academic Research Consortium (65), the assessment of the following aspects could be useful in future studies investigating cerebral embolic risk:

1. Evaluation of the impact of mitral annular and valve calcification, detected and quantified by preoperative computed tomography (preferably) or echocardiographic assessment; and
2. Meticulous assessment of procedural complexity, by means of documentation of all procedural steps, number of devices implanted and implantation attempts performed (e.g., number of grasps in the MitraClip procedure), and description of device repositioning before release or device retrieval.

Furthermore, because CEP during TAVR is safe and seems to be effective (6,64,66-68), we hope that future research will also investigate the need and benefit of CEP devices during catheter-based MV procedures.

CONCLUSIONS

Early scientific evidence suggests that cerebral embolization during transcatheter MV interventions is common (rates of overt and covert cerebral injury up to 7% and 86%, respectively) and remains poorly defined; however, the paucity of available data prevents definitive conclusions on the incidence, mechanisms, and implications of periprocedural neurological injury. Only future large, dedicated studies will tell us whether this risk represents a real clinical issue or just an academic curiosity.

ADDRESS FOR CORRESPONDENCE: Dr. Azeem Latib, Interventional Cardiology Unit, San Raffaele Scientific Institute, Via Olgettina 60, 20132 Milan, Italy. E-mail: alatib@gmail.com.

REFERENCES

1. Nkomo VT, Gardin JM, Skelton TN, Gottdiener JS, Scott CG, Enriquez-Sarano M. Burden of valvular heart diseases: a population-based study. Lancet 2006;368:1005–11.

2. Maisano F, Alfieri O, Banai S, et al. The future of transcatheter mitral valve interventions: competitive or complementary role of repair vs. replacement? Eur Heart J 2015;36:1651–9.

3. Gress DR. The problem with asymptomatic cerebral embolic complications in vascular procedures: what if they are not asymptomatic? J Am Coll Cardiol 2012;60:1614–6.

4. Bendszus M, Stoll G. Silent cerebral ischaemia: hidden fingerprints of invasive medical procedures. Lancet Neurol 2006;5:364–72.

5. Auffret V, Regueiro A, Del Trigo M, et al. Predictors of early cerebrovascular events in patients with aortic stenosis undergoing transcatheter aortic valve replacement. J Am Coll Cardiol 2016;68:673–84.

6. Pagnesi M, Martino EA, Chiarito M, et al. Silent cerebral injury after transcatheter aortic valve implantation and the preventive role of embolic

protection devices: a systematic review and meta-analysis. Int J Cardiol 2016;221:97–106.

7. Van Mieghem NM, El Faquir N, Rahhab Z, et al. Incidence and predictors of debris embolizing to the brain during transcatheter aortic valve implantation. J Am Coll Cardiol Intv 2015;8:718–24.

8. Schmidt T, Akdag O, Wohlmuth P, et al. Histological findings and predictors of cerebral debris from transcatheter aortic valve replacement: the ALSTER experience. J Am Heart Assoc 2016;5:e004399.

9. Sürder D. The MitraSwiss Registry: updated 6 and 12 months results. Paper presented at: Transcatheter Cardiovascular Therapeutics (TCT); October 11, 2015; San Francisco, CA.

10. Sorajja P, Vemulapalli S, Feldman T, et al. Outcomes with transcatheter mitral valve repair in the United States: an STS/ACC TVT registry report. J Am Coll Cardiol 2017;70:2315–27.

11. Nickenig G, Estevez-Loureiro R, Franzen O, et al. Percutaneous mitral valve edge-to-edge repair: in-hospital results and 1-year follow-up of 628 patients of the 2011-2012 Pilot European Sentinel Registry. J Am Coll Cardiol 2014;64:875–84.

12. Puls M, Lubos E, Boekstegers P, et al. One-year outcomes and predictors of mortality after MitraClip therapy in contemporary clinical practice: results from the German transcatheter mitral valve interventions registry. Eur Heart J 2016;37:703–12.

13. Feldman T, Foster E, Glower DD, et al. Percutaneous repair or surgery for mitral regurgitation. N Engl J Med 2011;364:1395–406.

14. Herrmann HC. EVEREST II REALISM CAR: non-high and high risk cohorts. Paper presented at: Transcatheter Valve Therapies (TVT); June 4, 2015; Chicago, IL.

15. Glower DD, Kar S, Trento A, et al. Percutaneous mitral valve repair for mitral regurgitation in high-risk patients: results of the EVEREST II study. J Am Coll Cardiol 2014;64:172–81.

16. Maisano F, Franzen O, Baldus S, et al. Percutaneous mitral valve interventions in the real world: early and 1-year results from the ACCESS-EU, a prospective, multicenter, nonrandomized post-approval study of the MitraClip therapy in Europe. J Am Coll Cardiol 2013;62:1052–61.

17. Grasso C, Capodanno D, Scandura S, et al. One- and twelve-month safety and efficacy outcomes of patients undergoing edge-to-edge percutaneous mitral valve repair (from the GRASP Registry). Am J Cardiol 2013;111:1482–7.

18. Lansky AJ, Messé SR, Brickman AM, et al. Proposed standardized neurological endpoints for cardiovascular clinical trials. J Am Coll Cardiol 2017;69:679–91.

19. Blazek S, Lurz P, Mangner N, et al. Incidence, characteristics and functional implications of cerebral embolic lesions after the MitraClip procedure. EuroIntervention 2015;10:1195–203.

20. Frerker C, Schlüter M, Sanchez OD, et al. Cerebral protection during MitraClip implantation: initial experience at 2 centers. J Am Coll Cardiol Intv 2016;9:171–9.

21. Feld GK, Tiongson J, Oshodi G. Particle formation and risk of embolization during transseptal catheterization: comparison of standard transseptal needles and a new radiofrequency transseptal needle. J Interv Card Electrophysiol 2011;30:31–6.

22. Thourani VH. Cardioband direct annuloplasty for functional MR: data synthesis and RCT progress. Paper presented at: Transcatheter Cardiovascular Therapeutics (TCT); October 30, 2017; Denver, CO.

23. Nickenig G, Schueler R, Dager A, et al. Treatment of chronic functional mitral valve regurgitation with a percutaneous annuloplasty system. J Am Coll Cardiol 2016;67:2927–36.

24. Worthley SG. MAVERIC:6-Month outcomes of transcatheter MV repair in patients with severe secondary mitral regurgitation. Paper presented at: Transcatheter Cardiovascular Therapeutics (TCT); November 1, 2017; Denver, CO.

25. Colli A. Transcatheter echo guided mitral valve repair with NeoChord implantation: results from NeoChord Independent International Registry. Paper presented at: Transcatheter Cardiovascular Therapeutics (TCT); October 31, 2016; Washington, DC.

26. Sievert H. Neochord: outcomes follows anatomy. Paper presented at: Transcatheter Valve Therapies (TVT); June 17, 2016; Chicago, IL.

27. Seeburger J, Rinaldi M, Nielsen SL, et al. Off-pump transapical implantation of artificial neochordae to correct mitral regurgitation: the TACT trial (Transapical Artificial Chordae Tendinae) proof of concept. J Am Coll Cardiol 2014;63:914–9.

28. Colli A, Manzan E, Zucchetta F, et al. Transapical off-pump mitral valve repair with Neochord implantation: early clinical results. Int J Cardiol 2016;204:23–8.

29. Park YH, Chon MK, Lederman RJ, et al. Mitral loop cerclage annuloplasty for secondary mitral regurgitation: first human results. J Am Coll Cardiol Intv 2017;10:597–610.

30. Schofer J, Siminiak T, Haude M, et al. Percutaneous mitral annuloplasty for functional mitral regurgitation: results of the CARILLON Mitral Annuloplasty Device European Union study. Circulation 2009;120:326–33.

31. Siminiak T, Wu JC, Haude M, et al. Treatment of functional mitral regurgitation by percutaneous annuloplasty: results of the TITAN Trial. Eur J Heart Fail 2012;14:931–8.

32. Lipiecki J, Siminiak T, Sievert H, et al. Coronary sinus-based percutaneous annuloplasty as treatment for functional mitral regurgitation: the TITAN II trial. Open Heart 2016;3:e000411.

33. Muller DWM, Farivar RS, Jansz P, et al. Transcatheter mitral valve replacement for patients with symptomatic mitral regurgitation: a global feasibility trial. J Am Coll Cardiol 2017;69:381–91.

34. Cheung A. Tiara: device description, strengths and weaknesses, and updated summary outcomes. Paper presented at: Transcatheter cardiovascular therapeutics (TCT); October 31, 2017; Denver, CO.

35. Rodés-Cabau J. Fortis: Design highlights and clinical update. Paper presented at: Transcatheter Valve Therapies (TVT); June 16, 2016; Chicago, IL.

36. Bapat V, Rajagopal V, Meduri C, et al. Early experience with new transcatheter mitral valve replacement. J Am Coll Cardiol 2018;71:12–21.

37. Piazza N. Highlife: device description, strengths and weaknesses, and updated summary outcomes. Paper presented at: Transcatheter Cardiovascular Therapeutics (TCT); October 31, 2017; Denver, CO.

38. Herrmann HC. CardiAQ-Edwards TMVR: design highlights and clinical update. Paper presented at: Transcatheter Valve Therapies (TVT); June 16, 2016; Chicago, IL.

39. Williams M. Caisson: device description, strengths and weaknesses, and updated summary outcomes. Paper presented at: Transcatheter Cardiovascular Therapeutics (TCT); October 31, 2017; Denver, CO.

40. Guerrero M, Dvir D, Himbert D, et al. Transcatheter mitral valve replacement in native mitral valve disease with severe mitral annular calcification: results from the first multicenter global registry. J Am Coll Cardiol Intv 2016;9:1361–71.

41. Rodriguez CJ, Bartz TM, Longstreth WT, et al. Association of annular calcification and aortic valve sclerosis with brain findings on magnetic resonance imaging in community dwelling older adults: the cardiovascular health study. J Am Coll Cardiol 2011;57:2172–80.

42. Benjamin EJ, Plehn JF, D'Agostino RB, et al. Mitral annular calcification and the risk of stroke in an elderly cohort. N Engl J Med 1992;327:374–9.

43. Kizer JR, Wiebers DO, Whisnant JP, et al. Mitral annular calcification, aortic valve sclerosis, and incident stroke in adults free of clinical cardiovascular disease: the Strong Heart Study. Stroke 2005;36:2533–7.

44. Dvir D. TAV in mitral surgical valves and rings: lessons from the VIVID registry. Paper presented at: Transcatheter Valve Therapies (TVT); June 16, 2017; Chicago, IL.

45. Yoon SH, Whisenant BK, Bleiziffer S, et al. Transcatheter mitral valve replacement for degenerated bioprosthetic valves and failed annuloplasty rings. J Am Coll Cardiol 2017;70:1121–31.

46. Eleid MF, Cabalka AK, Williams MR, et al. Percutaneous transvenous transseptal transcatheter valve implantation in failed bioprosthetic mitral valves, ring annuloplasty, and severe mitral annular calcification. J Am Coll Cardiol Intv 2016;9:1161–74.

47. Frerker C, Schmidt T, Schlüter M, et al. Transcatheter implantation of aortic valve prostheses into degenerated mitral valve bioprostheses and failed annuloplasty rings: outcomes according to access route and Mitral Valve Academic Research Consortium (MVARC) criteria. EuroIntervention 2016;12:1520–6.

48. Wilbring M, Alexiou K, Tugtekin SM, et al. Pushing the limits-further evolutions of transcatheter valve procedures in the mitral position, including valve-in-valve, valve-in-ring, and

valve-in-native-ring. J Thorac Cardiovasc Surg 2014;147:210–9.

49. Schäfer U, Bader R, Frerker C, et al. Balloon-expandable valves for degenerated mitral xenografts or failing surgical rings. EuroIntervention 2014;10:260–8.

50. Whisenant B, Jones K, Miller D, Horton S, Miner E. Thrombosis following mitral and tricuspid valve-in-valve replacement. J Thorac Cardiovasc Surg 2015;149:e26–9.

51. Bouleti C, Fassa AA, Himbert D, et al. Transfemoral implantation of transcatheter heart valves after deterioration of mitral bioprosthesis or previous ring annuloplasty. J Am Coll Cardiol Intv 2015;8:83–91.

52. Ye J, Cheung A, Yamashita M, et al. Transcatheter aortic and mitral valve-in-valve implantation for failed surgical bioprosthetic valves: an 8-year single-center experience. J Am Coll Cardiol Intv 2015;8:1735–44.

53. Cheung A, Webb JG, Barbanti M, et al. 5-year experience with transcatheter transapical mitral valve-in-valve implantation for bioprosthetic valve dysfunction. J Am Coll Cardiol 2013;61:1759–66.

54. Cullen MW, Cabalka AK, Alli OO, et al. Transvenous, antegrade Melody valve-in-valve implantation for bioprosthetic mitral and tricuspid valve dysfunction: a case series in children and adults. J Am Coll Cardiol Intv 2013;6:598–605.

55. Seiffert M, Conradi L, Baldus S, et al. Transcatheter mitral valve-in-valve implantation in patients with degenerated bioprostheses. J Am Coll Cardiol Intv 2012;5:341–9.

56. Cerillo AG, Chiaramonti F, Murzi M, et al. Transcatheter valve in valve implantation for failed mitral and tricuspid bioprosthesis. Catheter Cardiovasc Interv 2011;78:987–95.

57. Kliger C, Angulo R, Maranan L, et al. Percutaneous complete repair of failed mitral valve prosthesis: simultaneous closure of mitral paravalvular leaks and transcatheter mitral valve implantation—single-centre experience. EuroIntervention 2015;10:1336–45.

58. Himbert D. Transcatheter valve replacement for ring annuloplasty failures: valve-in-ring results. Paper presented at: Transcatheter Cardiovascular Therapeutics (TCT); October 30, 2016; Washington, DC.

59. Descoutures F, Himbert D, Maisano F, et al. Transcatheter valve-in-ring implantation after failure of surgical mitral repair. Eur J Cardiothorac Surg 2013;44:e8–15.

60. Schmidt T, Schlüter M, Alessandrini H, et al. Histology of debris captured by a cerebral protection system during transcatheter valve-in-valve implantation. Heart 2016;102:1573–80.

61. Hyman MC, Vemulapalli S, Szeto WY, et al. Conscious sedation versus general anesthesia for transcatheter aortic valve replacement: insights from the NCDR® STS/ACC TVT registry. Circulation 2017;136:2132–40.

62. Horn P, Hellhammer K, Minier M, et al. Deep sedation vs. general anesthesia in 232 patients undergoing percutaneous mitral valve repair using the MitraClip® system. Catheter Cardiovasc Interv 2017;90:1212–9.

63. de Waha S, Seeburger J, Ender J, et al. Deep sedation versus general anesthesia in percutaneous edge-to-edge mitral valve reconstruction using the MitraClip system. Clin Res Cardiol 2016;105:535–43.

64. Kapadia SR, Kodali S, Makkar RR, et al. Protection against cerebral embolism during transcatheter aortic valve replacement. J Am Coll Cardiol 2017;69:367–77.

65. Stone GW, Adams DH, Abraham WT, et al. Clinical trial design principles and endpoint definitions for transcatheter mitral valve repair and replacement: part 2: endpoint definitions: a consensus document from the Mitral Valve Academic Research Consortium. J Am Coll Cardiol 2015;66:308–21.

66. Giustino G, Mehran R, Veltkamp R, Faggioni M, Baber U, Dangas GD. Neurological outcomes with embolic protection devices in patients undergoing transcatheter aortic valve replacement: a systematic review and meta-analysis of randomized controlled trials. J Am Coll Cardiol Intv 2016;9:2124–33.

67. Latib A, Pagnesi M. Cerebral embolic protection during transcatheter aortic valve replacement: a disconnect between logic and data? J Am Coll Cardiol 2017;69:378–80.

68. Giustino G, Sorrentino S, Mehran R, Faggioni M, Dangas G. Cerebral embolic protection during TAVR: a clinical event meta-analysis. J Am Coll Cardiol 2017;69:465–6.

KEY WORDS cerebral embolism, neurological events, repair, replacement, transcatheter mitral valve intervention