

# iREVIEW

## FOCUS ISSUE: IMAGING THE TRICUSPID VALVE-PART II

### STATE-OF-THE-ART PAPER

# Cardiac Implantable Electronic Device Lead-Induced Tricuspid Regurgitation



Karima Addetia, MD,<sup>a</sup> Serge C. Harb, MD,<sup>a</sup> Rebecca T. Hahn, MD,<sup>b</sup> Samir Kapadia, MD,<sup>c</sup> Roberto M. Lang, MD<sup>c</sup>

### ABSTRACT

With the expanding use of cardiac implantable electronic device (CIEDs) in an ever-aging population, the looming problem of CIED-associated interference with the tricuspid valve is significant. The first pacemaker was implanted in 1958 for severe symptomatic bradycardia. The concept of a device to avert sudden cardiac death (i.e., the defibrillator) was first published in 1970 by Mirowski and Mower. The first reports of CIED-mediated tricuspid valve apparatus interference surfaced in the late 1990s, but it was not until recently that concentrated efforts have been made to better define the scope of CIED-mediated interference with the tricuspid valve apparatus. Because stopping implantation of these devices is not an option, better understanding of their mechanical complications could potentially lead to improvements in device design or epicardial device implantation, as an alternative, in select patients. This review covers existing evidence for CIED-mediated tricuspid regurgitation, discusses potential mechanisms of CIED-mediated interference of the tricuspid valve apparatus, provides an overview of how to diagnose CIED-mediated interference on echocardiography, and discusses management strategies for patients who have CIED-mediated severe tricuspid regurgitation. (J Am Coll Cardiol Img 2019;12:622-36) © 2019 by the American College of Cardiology Foundation.

Approximately 730,000 new permanent pacemakers (PPM) and 330,000 implantable cardioverter-defibrillators (ICDs) were implanted worldwide, according to the 2009 survey of cardiac PPM and ICDs (1). By far the largest number of devices, approximately 200,000 PPM and 120,000 ICDs, were implanted annually in the United States. These numbers will likely increase as the population continues to age. PPM, ICD, and cardiac resynchronization therapy (CRT) device-related tricuspid valve (TV) dysfunction includes regurgitation and less commonly stenosis. Both dysfunctions are primary (organic) causes of TV dysfunction. The occurrence of tricuspid regurgitation (TR) after device lead implantation was first described nearly 5 decades ago. Since then, numerous case reports, case series, and retrospective cohort studies have demonstrated an

association between device lead presence and TR. Interest in this topic has increased recently because of the understanding that TR is not a benign condition (2,3).

The current review provides an overview of the problem of cardiac implantable electronic device (CIED) lead-mediated TR, including how to recognize it, and a discussion of current management options (Central Illustration), with a focus on some of the issues that still need to be answered.

### ASSOCIATION BETWEEN CIED AND TRICUSPID REGURGITATION

The reported frequency of developing significant TR following CIED implantation varies, ranging from 7% to 45% (4-17). Initial studies using 2-dimensional (2D)

From the <sup>a</sup>Section of Cardiology, Department of Medicine, University of Chicago, Chicago, Illinois; <sup>b</sup>Columbia University Medical Center, New York Presbyterian Hospital, New York, New York; and the <sup>c</sup>Department of Cardiovascular Medicine, Heart and Vascular Institute, Cleveland Clinic, Cleveland, Ohio. Dr. Kapadia has stock options with Navigate Valve. All other authors have reported that they have no relationships relevant to the contents of this paper to disclose.

Manuscript received June 15, 2018; revised manuscript received September 4, 2018, accepted September 6, 2018.

echocardiography described conflicting results regarding the association between TR severity and the presence of a CIED (18). Specifically, although animal studies and early prospective human studies showed no significant differences between TR severity pre- and post-endocardial lead implantation, later studies suggested an increase in TR severity associated with CIED implantation (5-7,15,19,20). Most, but not all, studies attributed a higher incidence of worsening TR with ICD leads because of their greater thickness and stiffness. In contrast, other investigators reported subgroups of patients with improved TR after device lead implantation. This observation was attributed to improved RV hemodynamics with pacing after right ventricular (RV) lead placement (4,14). These conflicting reports can probably be explained by limitations of the existing studies. First, these reports are based largely on case reports and retrospective and observational studies. Second, there are minimal data reported for outcomes. Third, control groups were generally not included in these studies, and fourth, PPM, ICD, and CRT devices were often studied together. Some of the conflicting observations likely also originate from the pitfalls associated with the exclusive use of 2D transthoracic echocardiography (TTE) for the diagnosis of CIED-induced TR. With 2D TTE, device leads are fully visualized as they traverse the TV annulus in only 15% of cases (21). Comparisons between TR degree before and after device lead implantation are also frequently confounded by the strong reflectivity of the device lead as well as lead-generated acoustic artifact, both of which may lead to underestimation of TR degree by color Doppler. This underestimation is more pronounced with TTE than with TEE. In 1 study, preoperative TTE in patients undergoing surgery for device lead-mediated TR underestimated TR severity in 37% of patients who were later found to have severe TR on intraoperative TEE (22). In addition, many of those patients (at least those with ICD and CRT devices) had underlying left ventricular dysfunction which, over time, leads to RV enlargement, tricuspid annular dilation, and functional TR, a scenario that may develop even in the absence of a CIED.

More recently, studies have incorporated outcomes in their methods and have shown that CIED-induced TR is associated with a poorer prognosis (5,9,11). A single-center study examined the prevalence of significant TR in a cohort of 634 consecutive patients over a 6-year period. PPM leads were associated with a higher risk of developing significant TR and higher likelihood of mortality even after adjustment for left ventricular dysfunction and pulmonary hypertension (9). **Table 1** summarizes the studies addressing the

frequency of occurrence or worsening of TR following CIED implantation.

Interestingly, early ICD studies showed that, although sudden death was reduced in patients who received ICDs, heart failure-related hospitalizations and deaths were increased (23-25). This raises the issue of whether right heart failure was the cause of morbidity in these patients or whether these patients had lead-related interference of the tricuspid valve causing new or worsening TR which subsequently predisposed patients to develop worsening heart failure. Of note, several studies have demonstrated that patients with CIED-induced TR had worsening of right heart function compared with that in patients without significant lead-induced TR (9,11,26).

#### MECHANISMS OF CIED-INDUCED TRICUSPID REGURGITATION

Mechanisms proposed to explain CIED-induced TR can be classified as implantation-related, pacing-related, and device-mediated. The implantation technique used for CIEDs varies from operator to operator and has evolved over the years. Certain technical factors have been associated with increased likelihood of damage to the TV apparatus. Some experts advocate that, in comparison to the “prolapsing” technique (27) used for lead implantation, the direct crossing of the tricuspid valve results in decreased risk of trauma and damage to the tricuspid apparatus and therefore less TR; however, the outcomes of this technique have not been rigorously studied. There are limited data regarding the physical properties of the leads and their effect on TR development. One report (22) found a higher number of silicone-insulated leads in patients who developed severe symptomatic TR requiring tricuspid valve surgery. However, that observation could have simply reflected the older generation leads that were included in that particular retrospective study. Other studies have suggested that the higher the number of leads crossing the tricuspid annulus results in the higher risk for developing worsening TR (8,28). Although some studies have suggested that the bulkier and stiffer defibrillator leads have a higher incidence of worsening TR than pacemaker leads (12), this observations has not been reproduced in other studies (5,6,10,14). It remains unclear whether lead location has an impact on the development of TR. Few reports have suggested less TR with RV outflow tract compared to apical pacing (14,29); however, this

#### ABBREVIATIONS AND ACRONYMS

**CIED** = cardiac implantable electronic device

**CRT** = cardiac resynchronization therapy

**ICD** = implantable cardioverter-defibrillator

**PPM** = permanent pacemakers

**RV** = right ventricular

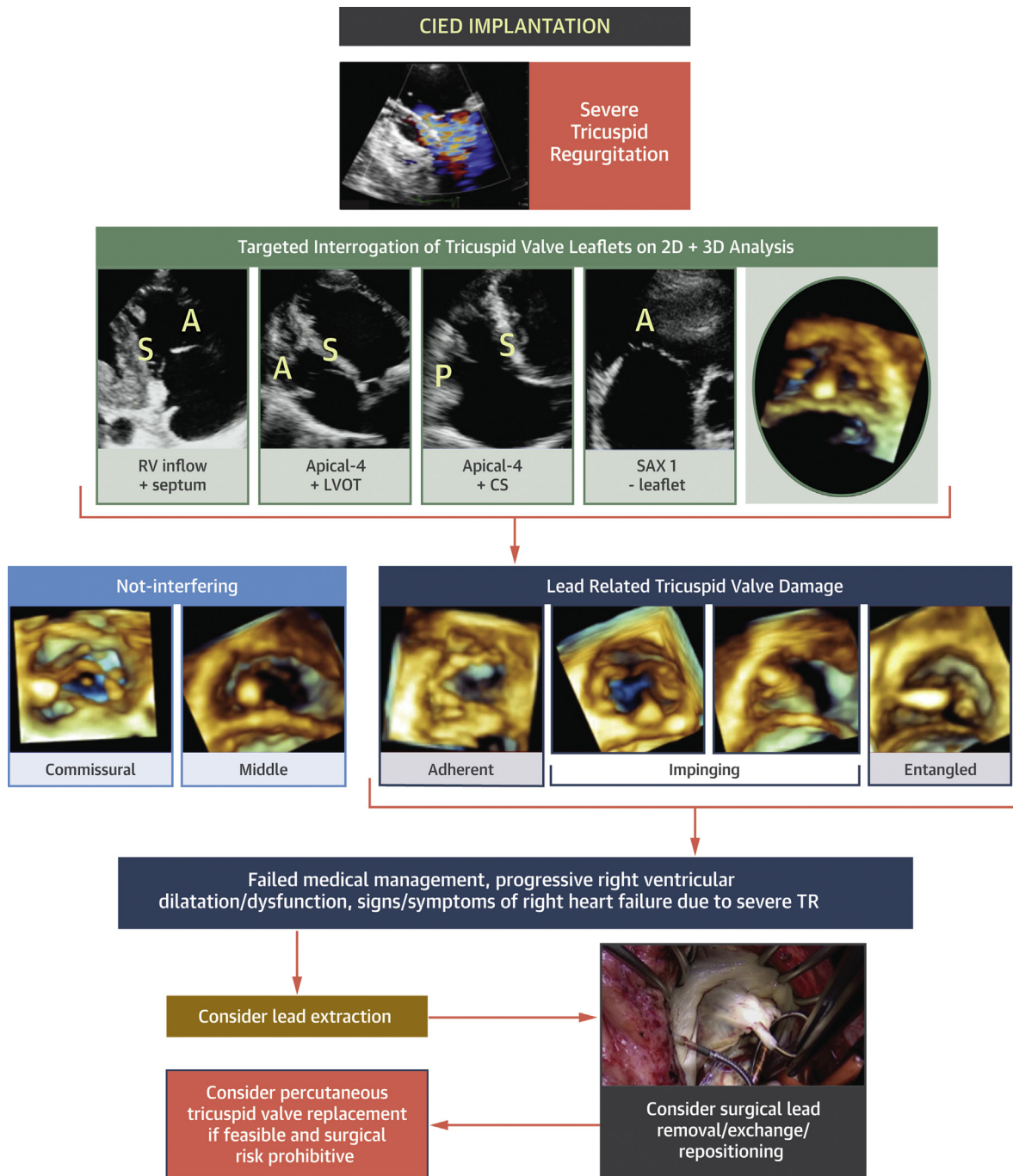
**TA** = tricuspid annular

**TEE** = transesophageal echocardiography

**TR** = tricuspid regurgitation

**TTE** = transthoracic echocardiography

**TV** = tricuspid valve

**CENTRAL ILLUSTRATION** Pictorial Representation of Possible Decision Pathway for a Patient Who Presented With Severe Tricuspid Regurgitation in the Presence of a Device Lead

Addetia, K. *et al.* *J Am Coll Cardiol Img.* 2019;12(4):622-36.

The first step (**second row**) would be to image the tricuspid valve using a targeted 2D approach aimed at determining whether the CIED was interfering with 1 or more tricuspid valve leaflets or a subvalvular apparatus. Three-dimensional echocardiography can also be used to help with this step (**third row**). If the device is felt to be instrumental in the cause of tricuspid regurgitation and the patient shows progressive right ventricular dilatation or dysfunction of the tricuspid valve, then the decision may be made to perform lead extraction. If lead extraction fails or is not an option, then a surgical approach may be required. If the patient is at too much of risk for a surgical approach and intervention is preferred, then percutaneous options may be needed (**bottom rows**).

**TABLE 1** Frequency of CIED-Related Tricuspid Regurgitation

First Author (Ref. #)	Year	N	CIED	Timing of TR Assessment After Implantation	Assessment of Onset or Worsening of TR	Reported Frequency, %	Comments
Paniagua et al. (15)	1998	374	All PPM	NA	Onset	7	Severe TR was defined as 3 to 4+ TR
de Cock et al. (8)	2000	96	All PPM	Mean: 7.4 ± 2 yrs	Onset	21	Severity of TR was not specified
Seo et al. (16)	2008	87 (TR data available only in 82)	50 PPM, 17 ICD, 20 CRT	Range: 0 to 240 months	Onset	15	10 of the 12 patients who developed severe TR had nonsevere TR prior to CIED implantation
Kim et al. (12)	2008	248	174 PPM, 74 ICD	Range: 23 to 199 days	Worsening by at least 1 grade	24	21.2% of patients developed new, clinically significant TR (1.5 to 3+)
Webster et al. (17)	2008	123	All PPM	Median: 827 days	Worsening by at least 1 grade	25	Study population consisted of pediatric and congenital heart disease patients
Klutstein et al. (13)	2009	410	All PPM	Range: 1 to 3,549 days	Worsening by at least 2 grades	18	Improvement by at least 2 grades was observed in 4.4%
Höke et al. (11)	2014	239	191 ICD, 48 PPM	Within 1.5 yrs	Worsening to a grade ≥2	38	Significant TR was defined as grade ≥2
Fanari et al. (64)	2015	206	120 PPM, 86 ICD	Mean: 29 ± 19 months	Worsening by at least 1 grade	45	Post-implantation echocardiography was performed at least 6 months after lead insertion
Lee et al. (14)	2015	382	203 PPM, 179 ICD	Range: 1-1,200 days	Worsening by at least 2 grades	10	TR was assessed on a 6-point scale
Arabi et al. (6)	2015	41	7 PPM, 25 ICD, 9 CRT	1, 6, and 12 months	Worsening by at least 2 grades	17	TR was worsening by 1 grade in 71% of patients
Al-Bawardy et al. (5)	2015	1,596	611 PPM, 985 ICD	Range: 1 day-6.5 yrs	Prevalence of severe TR at 4 yrs	35	Prevalence of severe TR pre-implantation was 27%
Delling et al. (9)	2016	634	All PPM	NA	Onset	16	Significant TR was defined as ≥3+

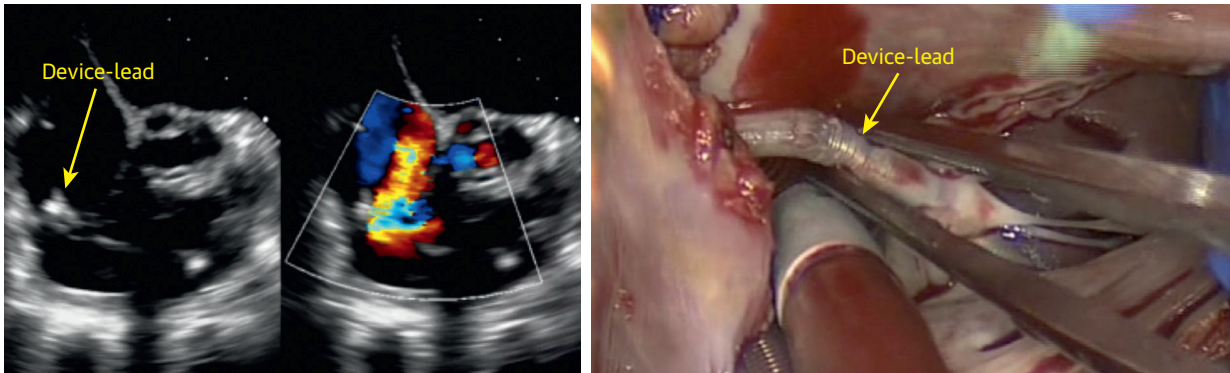
CIED = cardiac implantable electronic devices; ICD = implantable cardiac defibrillation; NA = not available; PPM = permanent pacemaker; TR = tricuspid regurgitation.

has not been observed consistently in studies comparing both strategies (30). Although mitral regurgitation has been shown to occur as a result of dys-synchronous contraction of the interventricular septum (10,31), a higher pacing burden has not been shown to correlate with worsening TR (5,7,10,14). Nevertheless, a number of studies have associated RV pacing with worsening degree of TR. The mechanism suggested for this is the alteration in RV geometry with pacing (32).

In vivo 2D and more recently 3D echocardiographic studies as well as post-mortem examinations of hearts with device leads have shown that leads can interfere with the tricuspid valve apparatus by impinging upon a leaflet, adhering to a leaflet, interfering with the subvalvular apparatus, perforating/lacerating a leaflet, and avulsion of a leaflet, which may uncommonly happen during lead extraction. It has been shown on post-mortem examinations in patients with device leads and during open heart surgery that a fibrotic process can entrap the device lead within the tricuspid valve leaflet and/or subvalvular apparatus (Figure 1, Video 1), resulting in various degrees of leaflet malalignment and malcoaptation. Although it is strictly not a form of device lead-mediated TV dysfunction, the presence of a device lead can predispose the patient to both thrombus formation and endocarditis. A case series

of 41 patients with CIED and severe TR who were undergoing surgery to repair or replace the tricuspid valve reported the mechanisms of TR according to intraoperative findings. The authors found that lead entrapment in the subvalvular apparatus was found in 4 patients, leaflet perforation occurred in 7 patients, lead impingement on a tricuspid valve leaflet was found in 6 patients, and lead adherence to the TV leaflet was found in 14 patients (22). Approximately 10% of CIEDs may fail or become infected, converting the patient to a candidate for lead extraction (33). Lead extraction can also result in damage to the TV apparatus and become an additional mechanism of lead-mediated TV dysfunction. Newer methods for lead extraction, including laser-assisted dissection of the lead from adherent material, has been shown to result in a lower incidence of complications such as worsening TR (0% to 6%) (7,33-35). Furthermore, if a lead is found to be resistant to extraction, it may be left in the chest cavity or, alternatively, surgically extracted if necessary. It has been shown that older leads are more likely to be encapsulated and require laser extraction tools than newer leads (33).

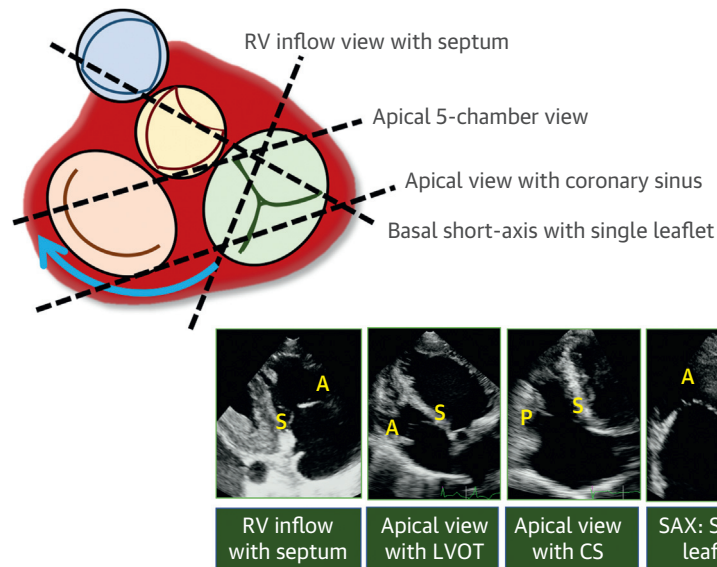
There are conflicting data as to whether patient-related clinical and echocardiographic data can predict lead-related TR. In a large, retrospective, single-center study (9), the following variables were

**FIGURE 1 Patient With Device Lead-Induced TR**

On 2D (**left**) and color Doppler (**middle**) views, the device leads can be seen traversing the TV (**left**) and a significant amount of TR is seen on the 2D color Doppler image. The location of TR suggests that the device lead may be interfering with leaflet motion. Intraoperative view (**right**) shows that the device lead is entrapped by fibrous/inflammatory tissue and is adhering to the TV leaflets and subvalvular apparatus. See [Video 1](#). TR = tricuspid regurgitation; TV = tricuspid valve.

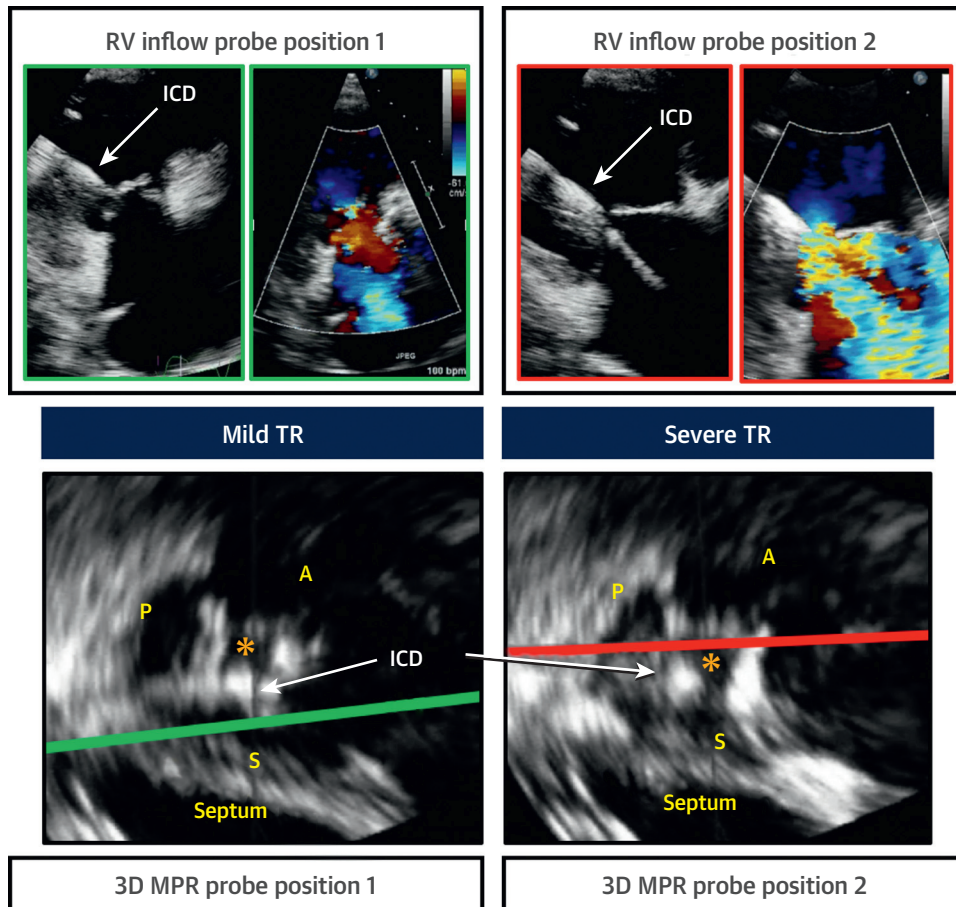
found to be significantly associated with CIED-related TR on multivariate analysis: increasing age, lower body mass index, higher heart rate, history of mitral valve repair or replacement, significant mitral

regurgitation, elevated pulmonary pressure (pulmonary artery systolic pressure  $\geq 37$  mm Hg), and RV dilation. However, in another retrospective study (14), right atrial area and RV systolic pressure were

**FIGURE 2 Targeted Imaging to Include Specific Landmarks Is Recommended to Allow More Predictable Imaging of Leaflets and Leaflet Pairs**

(**Top left**) Base of the heart shows general location of the valves with respect to each other. **Hatched lines** illustrate cut planes recommended for targeted imaging of the tricuspid valve leaflets. In the right ventricular inflow view (**bottom, far left**), when the interventricular septum and coronary sinus are seen, the leaflets imaged are the septal (S) and anterior (A). In the apical 5-chamber view (**bottom middle left**) the S and A leaflets are visualized. In the apical view, when visualizing the coronary sinus (**bottom middle right**), the S and posterior (P) leaflets are seen. In the short-axis view (**bottom far right**) when a single leaflet is visualized, the A leaflet is imaged. RV = right ventricle.

**FIGURE 3** Localization of Leaflet Pathology Is Possible With the Help of Targeted 2D and 3D Imaging of the Tricuspid Valve as Illustrated in This Case of a Patient With Dilated Cardiomyopathy



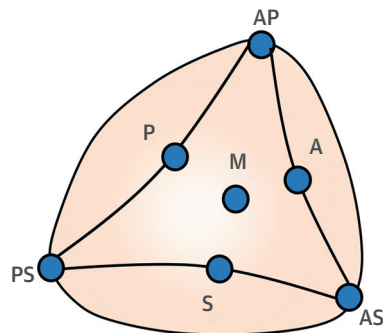
(Top left) RV inflow view obtained from the transducer in position 1 with mild tricuspid regurgitation on color Doppler. (Top right) Right ventricular inflow view obtained from a slightly different transducer position, revealing severe tricuspid regurgitation. To obtain the images in the bottom panels, 3D full-volume datasets were acquired in the identical transducer positions as the inflow positions 1 and 2 (bottom left and right, respectively). Multiplanar reconstruction was used to determine which pair of TV leaflets was being imaged in each transducer position. Transducer position 1 was cutting through the anterior and septal leaflets of the tricuspid valve, whereas transducer position 2 was intersecting the anterior and posterior leaflets. Both datasets in the bottom are presented in end-systole. There is a malcoaptation (orange star) between the anterior and posterior leaflets. ICD = implantable cardioverter-defibrillator; MPR = multi-planar reconstruction; other abbreviations as in Figures 1 and 2.

the only variables that remained associated with worsening TR after multivariate adjustments. Finally, in a retrospective study that included pacemaker and defibrillator leads, Höke et al. (11) did not find any significant differences between patients who developed lead-related TR and those who did not.

#### NATURAL HISTORY OF CIED-RELATED TRICUSPID REGURGITATION

There are scant data in which the timing of onset or worsening of TR after lead implantation was

assessed, with no prospective study specifically addressing this issue, although at least 1 such study is currently under way (36). In one of the largest retrospective studies of this topic (5), including 1,596 patients with early (1-month post-implantation) and late (4-year) follow-up examinations, there was a significant, albeit small, increase in the prevalence of moderate and severe TR, both acutely and chronically. There was a temporal trend toward more pronounced worsening in the acute period for grade 2+ and 3+ TR and more delayed worsening for grade 4+ TR. In another small report including 41 patients (6)

**FIGURE 4** Possible Locations of the CIED at the Level of the Tricuspid Valve

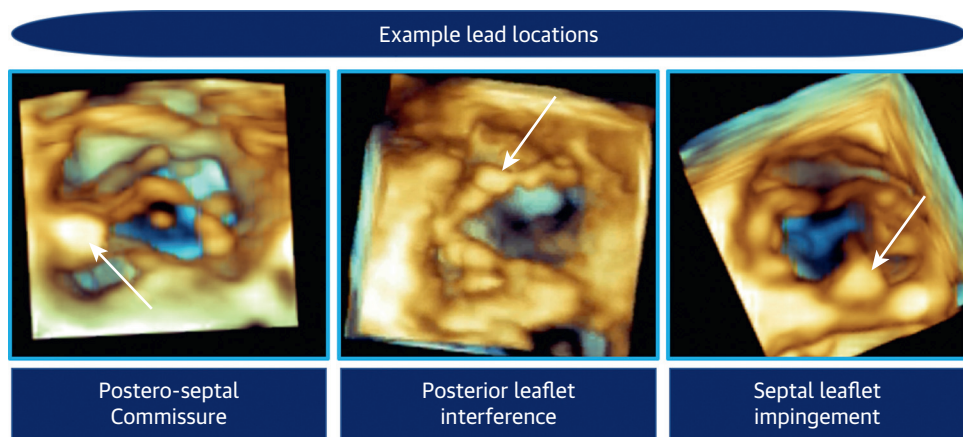
Each **blue dot** represents a possible device lead location along the tricuspid valve orifice. **Dots** positioned against the leaflets (A, S, P) are meant to describe leads that are impinging on or somehow interfering with the respective leaflet. **Dots** positioned in the commissures (AP, PS, AS) describe leads that are located in a commissural position. The **central dot** (M) depicts a device lead located in the middle of the valve, not interfering with leaflet motion. A = anterior leaflet impingement; AP = device lead in the anteroposterior commissure; AS = device lead in the antero-septal commissure; CIED = cardiac implantable electronic device; P = posterior leaflet impingement; PS = device lead in the postero-septal commissure; S = septal leaflet impingement.

with repeat echocardiographic assessment immediately after CIED and at 1-, 6-, and 12-month intervals, a varying pattern of worsening TR was identified based on the method of TR quantification. When

patients were assessed by color Doppler, there was an acute pattern of worsening within the first month after implantation and subsequent stabilization at 6- and 12-month intervals. However, when quantitative assessment was performed, the vena contracta and proximal isovelocity surface area gradually increased throughout the follow-up period. Similarly, there was a progressive increase in right-sided chamber sizes with a progressive decline in RV function.

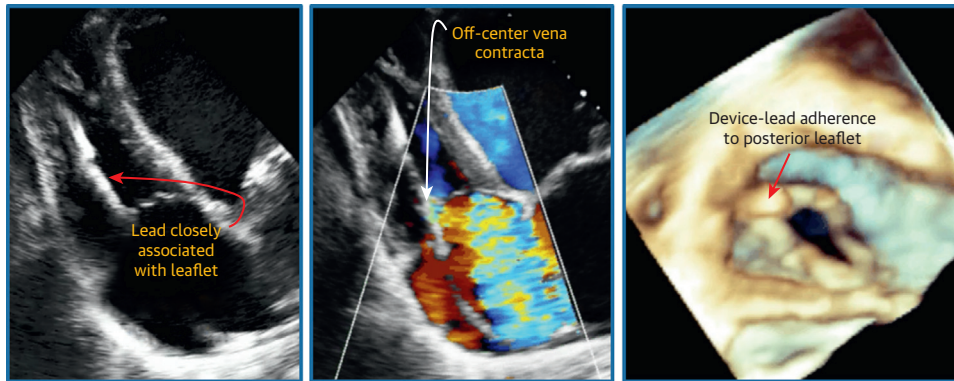
### ECHOCARDIOGRAPHY TO DIAGNOSE CIED INTERFERENCE

The TV can be imaged from both the transthoracic and TEE perspective, using both 2D and 3D echocardiography. Because the TV is anteriorly located in the mediastinum, it is often more easily accessible with the transthoracic rather than the transesophageal probe. With both TTE and TEE 3D echocardiography, all 3 leaflets can be visualized simultaneously from both the right atrial and the RV perspectives, and the location of the device lead is often well visualized in reference to the TV leaflets and annulus. Visualization of the device lead in this manner may help determine whether there is device lead-mediated interference with the TV leaflets in patients with suspected device lead-mediated TR. With full-volume datasets of the RV, it is also frequently possible to follow the trajectory of the device lead in the RV to establish the relationship between the CIED and the subvalvular tricuspid apparatus. Due to the high acoustic impedance and strong reflectivity of

**FIGURE 5** Three Possible Device Lead Tricuspid Leaflet/Valve Interactions

**(Left)** Device lead in the postero-septal commissure. **(Middle)** Device lead adhering to the posterior leaflet. **(Right)** Septal leaflet impingement by the device lead. See [Videos 2, 3, 4, and 5](#).

**FIGURE 6 ICD Lead Interference With a Tricuspid Valve Leaflet**



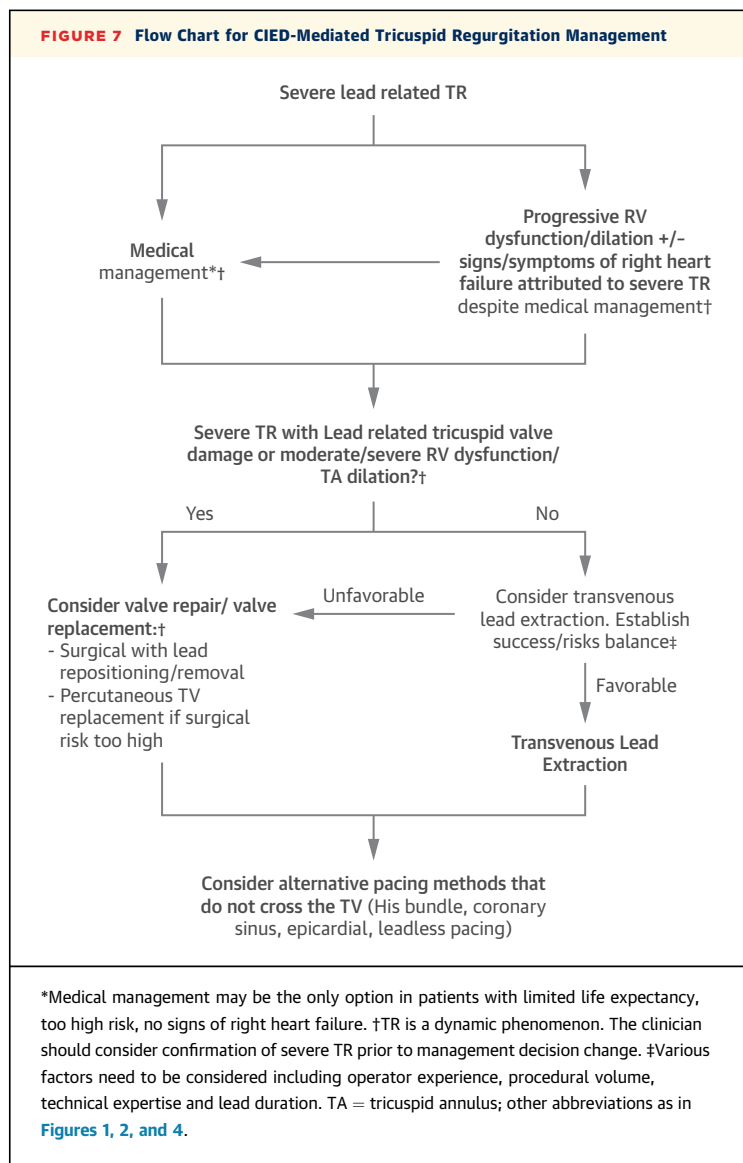
2D (left), 2D color Doppler (middle), and 3D zoom dataset of the tricuspid valve as seen from the right ventricular perspective in a patient with an ICD lead interfering with the posterior leaflet. Notice that, on color Doppler interrogation, the regurgitant jet appears to originate where the lead and leaflet interfere with each other. Also notice that, on the 3D image, the lead is adherent to the tricuspid valve leaflet. See Video 6.

the device lead, underestimation of the severity of TR with color Doppler imaging may occur. This underestimation is more pronounced on TTE than TEE. This was shown in 1 study where preoperative TTE in patients undergoing surgery for device lead-mediated TR underestimated TR severity in 37% of patients compared to those who underwent intraoperative TEE studies (22).

In order to reliably identify the mechanism of CIED interference with the TV apparatus on 2D echocardiography, it is important to interrogate the tricuspid valve by using a protocol that allows the operator to determine with certainty the specific TV leaflet combinations being imaged. Currently, textbooks and social guidelines are inconsistent when describing which tricuspid leaflet combinations are visualized from each of the standard tricuspid valve views (i.e., the RV focused view, the apical 4-chamber view, and the parasternal short-axis view) (37). What is frequently described is that the posterior and anterior TV leaflets are visualized in the RV-inflow view, whereas the septal and anterior leaflets are seen in both the parasternal short-axis and the apical 4-chamber views. Recent data, however, suggest that it is impossible to know with certainty which pair of leaflets are being imaged in each of the standard views (37,38). This is further confounded by the extreme variability of the size of the leaflets, as well as the number of tricuspid leaflets. Although the TV is typically described as being composed of 3 leaflets of

unequal sizes, in many cases, 2 (bicuspid) or more than 3 leaflets can be seen. Wafae et al. (39) found the tricuspid valve was not consistently tricuspid but was observed to have 2, 4, 5, or 6 cusps in 72% of cases (40). Accordingly, 2D imaging of the TV leaflets targeted with attention to specific adjacent anatomic landmarks has been suggested as a way to localize TV anatomy with precision (Figure 2) (37,41). For instance, in the RV inflow view, when the septum is seen, the septal leaflet is imaged in the far field with the anterior leaflet imaged in the near field. In the apical 4-chamber view, if the aortic valve is brought into view, the anterior and septal tricuspid leaflets are being imaged. However, when the coronary sinus is seen in this imaging plane, the septal and posterior leaflets are being imaged. In the parasternal short-axis view, if a single leaflet is visualized, this is always the anterior leaflet, which is the largest of all 3 TV leaflets. Targeted interrogation of the tricuspid valve leaflets is important to localize tricuspid regurgitation and hence TV pathology to a specific leaflet (Figure 3) and to understand the mechanism of TR in patients with CIEDs. The minimum number of 2D views required to localize TV pathology include the 3 standard views described above along with the RV-focused view (all with and without color Doppler interrogation), the RV inflow view with septum and coronary sinus, the apical view with left ventricular outflow tract, and the apical view with the coronary sinus. The information provided by these views must





be integrated to isolate the TR jet and connect it with the CIED. An echocardiogram obtained prior to device insertion may help, especially if it was normal and no new pathology affecting the right heart occurred in the interim. Sometimes CIED-induced TR can be suspected if the origin of the TR color Doppler jet is higher than the coaptation point of the TV leaflets, suggesting that TR may be caused by CIED-induced interference with the TV apparatus. Also, sometimes the CIED is seen to “move with” or appears attached to the septal leaflet. This also may suggest interference.

On 2D echocardiography the trajectory of the device lead is visualized in only 17% of cases (16). Identification of device lead-mediated interference of the tricuspid valve as a cause of TV dysfunction is

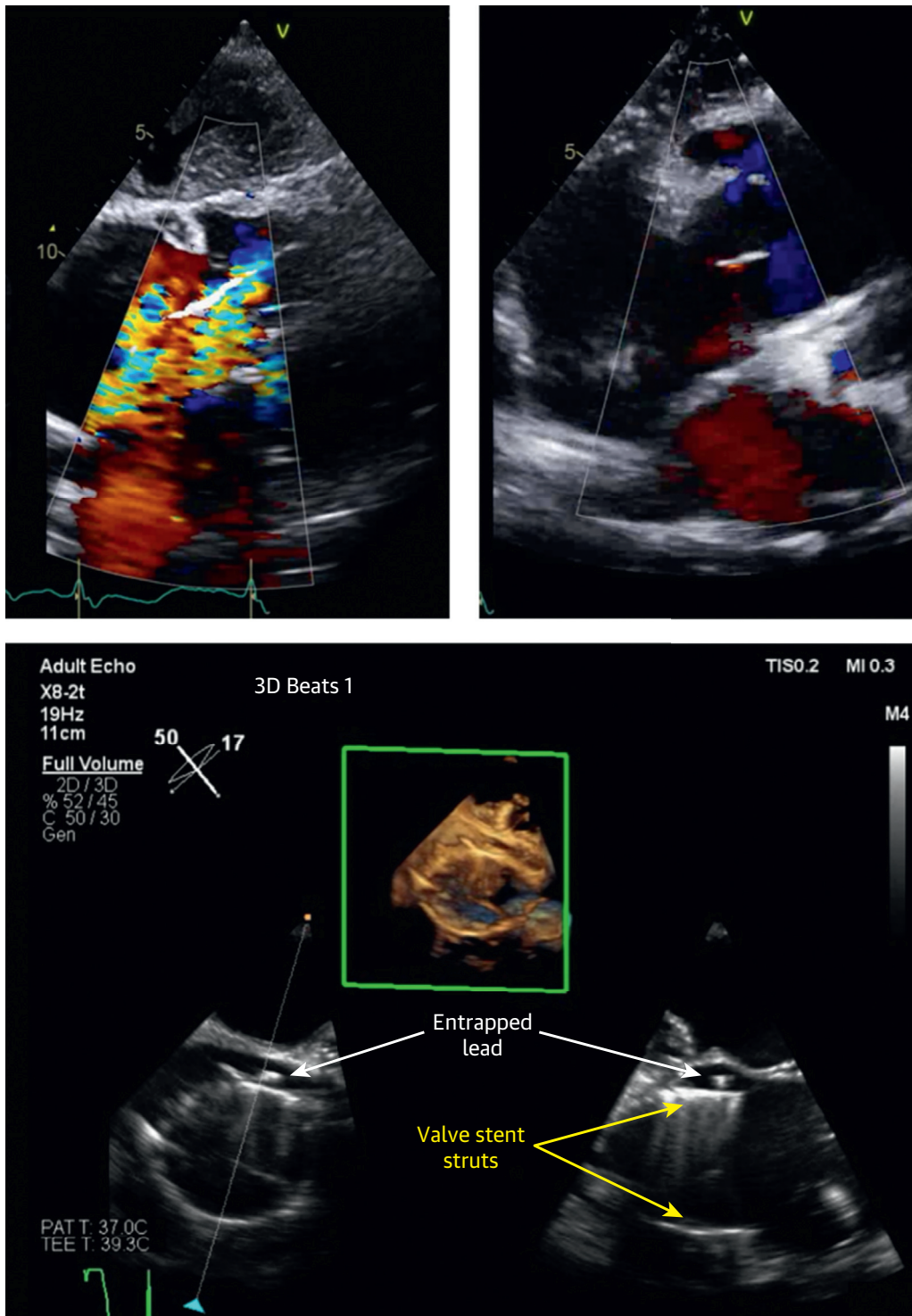
likewise extremely low (~12% of cases) (16,22). With 3D echocardiography, visualization of the device lead was more reliable, with a feasibility of 74% (153 of 207 patients) in a study which used 3D zoom views together with RV full-volume datasets (both 4-beat gated acquisitions in suspended respiration) (42). A similar study reported that 3D TTE images of the tricuspid valve can be visualized in 90% of patients with adequate 2D images (16). CIEDs can be visualized in a number of different positions relative to the tricuspid annulus and leaflets by using 3D echocardiography. They can be found in the commissures (anteroseptal, posteroseptal, or anteroposterior), against, impinging or adherent to a leaflet, or in the middle of the valve (Figures 4 and 5, Videos 2, 3, 4, and 5) (16,42). Leads labeled as “impinging” or “adherent” were associated with greater degrees of TR according to 1 retrospective, single-center high-volume referral tertiary care center. Leads located in commissural positions or in the “center of the valve” were less likely to be associated with significant TR (Video 5) (16). The “impinging” lead interferes directly with leaflet coaptation (Video 4). The adherent lead, on the other hand, is stuck to the leaflet/tricuspid apparatus but still moves along with it (Video 6). In a multivariable analysis of patients with device leads and pre- and post-device echocardiography, pre-implantation vena contracta width and presence of an interfering lead were independently associated with post-device TR (26).

CIED-induced TR should be suspected whenever a patient with a device lead has significant TR, especially when an echocardiogram acquired prior to device lead implantation had little or no TR. Some clues to possible lead-induced TR on 2D echocardiography include TR jet hugging the device lead, leaflet malcoaptation, and lead adherence to the subvalvular structures; these leads tend to move with the subvalvular apparatus (Figure 6, Video 6), extreme lead displacement against the septum, and non-RV outflow tract lead position (14).

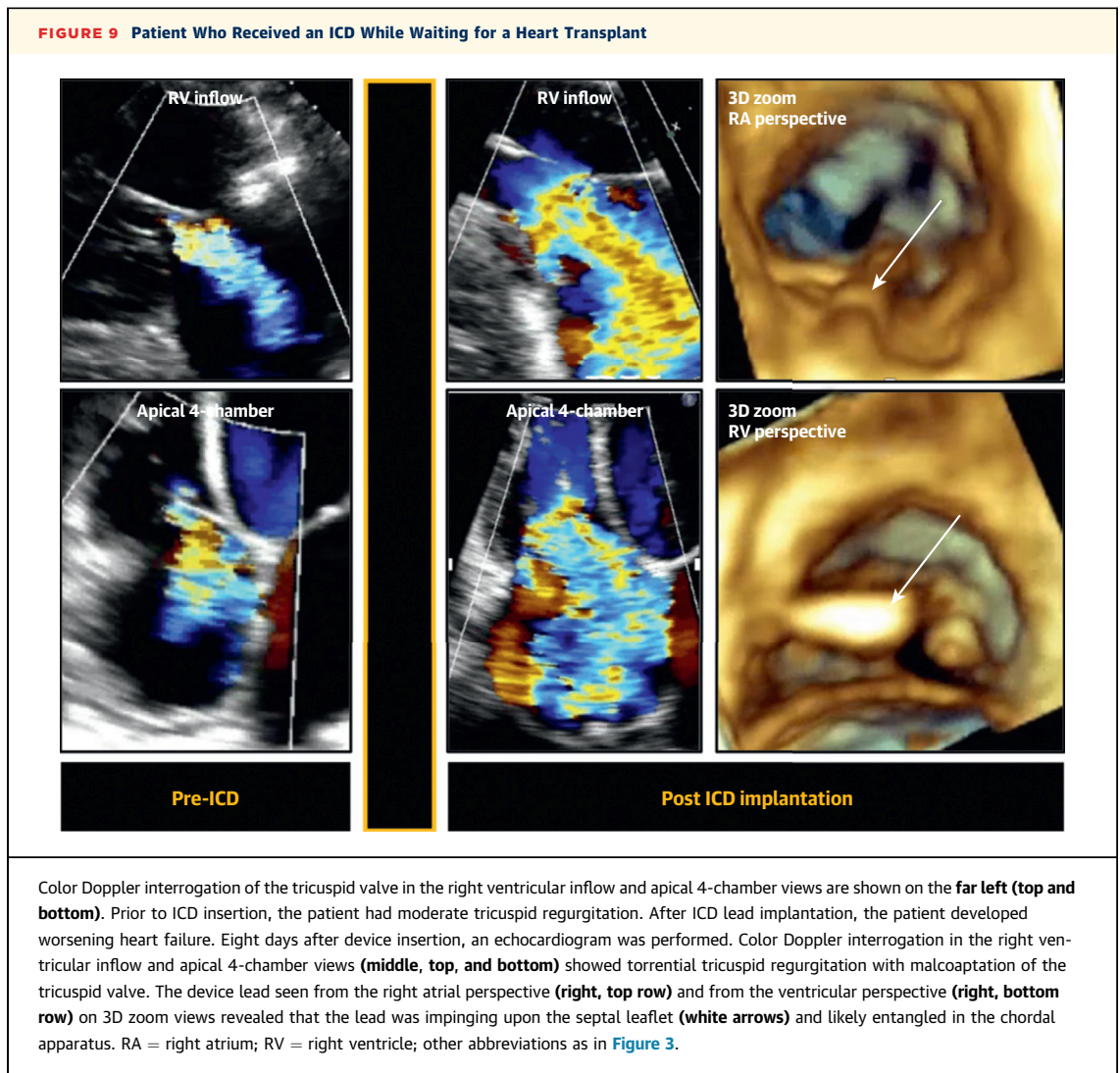
## CIED-INDUCED TRICUSPID REGURGITATION OUTCOMES

It is now well recognized that significant TR is associated with increased morbidity and mortality (3). CIED-related TR has been shown to result in remodeling of the right heart, with enlargement of right atrial and ventricular volumes and worsened RV function (6,11). In the worst-case scenario, lead-related TR may manifest clinically with right heart failure symptoms including hepatomegaly, ascites,

**FIGURE 8** Pre- and Post-TTVR



**(Top left)** Subcostal 4-chamber transthoracic echocardiogram view prior to transcatheter TV replacement showing severe lead-related TR. **(Top right)** Similar view after TTVR displaying the valve newly implanted with significant improvement in TR severity. **(Bottom)** Intra-procedural 3D transesophageal echocardiogram shows the relationship between the newly implanted valve stent struts and the entrapped pacemaker lead. See [Video 7](#). TTVR = transcatheter tricuspid valve-in-valve replacement; other abbreviations as in [Figure 1](#).



and peripheral edema. In a series of patients with severe lead-related TR requiring TV surgery, approximately 50% presented primarily with severe right heart failure symptoms (22). In another report, lead-related severe TR was associated with more heart failure-related events, that is, heart failure hospitalization, TV surgery, or upgrade to CRT, and worsening long-term survival (11). When specifically looking at the impact of TR on survival in patients with CIED (5,9,11), there was 40% to 75% excess mortality attributed to severe TR after multivariate adjustment.

Although 1 report (11) suggested pulmonary pressures were higher in patients who developed lead-related TR than in those who did not, other studies failed to show worsening pulmonary pressures on follow-up (5,6,12).

#### MANAGEMENT OF PACEMAKER-INDUCED TRICUSPID REGURGITATION

Management of CIED-related severe TR depends on the presence of right sided heart failure symptoms, severity of TR, extent of lead-related valvular damage, degree of RV dysfunction and tricuspid annular dilation, and critical, although often challenging, distinction between lead-related primary TR and secondary functional TR (7). The last differentiation is further complicated by the intricacy and frequent coexistence of both conditions, particularly in this group of patients. Pacemaker and/or defibrillator leads are often implanted in patients with left sided disease known to cause secondary right sided dysfunction and subsequent functional TR. In addition, lead-related severe primary TR, if not treated

promptly, can cause RV remodeling with tricuspid annular (TA) dilation and leaflet malcoaptation. This results in a superimposed secondary TR that frequently does not improve, even if the lead is removed and the leaflets' function are restored. Management strategies include medical therapy, consideration for transvenous lead extraction, and TV repair/replacement (**Figure 7**).

**MEDICAL THERAPY.** Diuretic agents are the mainstay of therapy (43) in patients with severe TR and symptomatic right heart failure. Loop diuretics are commonly used, with aldosterone antagonists advocated as useful additional agents, particularly in cases with hepatic congestion and secondary aldosterone increase. There is, however, a paucity of data regarding the long-term outcomes of this conservative medical strategy in patients with lead-related severe TR (4).

**TRANSVENOUS LEAD EXTRACTION.** Although the safety and efficacy of lead extraction has significantly improved in the past decade (44), there are still no prospective data and therefore no guideline recommendations (45,46) to support lead extraction for severe TR in the absence of device or lead infection. This is reflected by the finding that device infection still accounts for most extractions (47). In addition, lead extraction can be complicated by TV damage leading to worsening TR (48). However, left untreated, severe lead-related TR is associated with excess mortality that has been estimated to be approximately 40% to 75% (9,11), and significant morbidity, including adverse RV remodeling and TA dilation resulting in irreversible severe TR. Accordingly, when the operative risk is low, it should be determined whether the TR mechanism is thought to be lead related, and if there is no significant RV dysfunction/TA dilation, lead extraction should be expected to be of benefit and should be considered (7). When assessing the operative risk of lead extraction (46), procedural volume and technical expertise are important considerations. In addition, risk scores have been developed to aid in the decision process (49) in which the lead implant is a major determinant of procedural success and complications (46). Typically, lead explantation using simple traction techniques can be performed for leads implanted within 1 year, whereas more specialized equipment is usually required for leads that have been present for more than 1 year.

**SURGICAL TREATMENT.** Indications for TV surgery in cases of severe primary TR without left sided disease are not well established, and there are some

discrepancies in the strength of the recommendations between the American College of Cardiology and American Heart association and the (43) and the European Society of Cardiology (50) valvular guidelines. There are 2 scenarios where TV surgery should be considered for severe primary TR: first, in patients who remain symptomatic despite diuretic therapy (received a weak recommendation by AHA/ACC and a strong recommendation by ESC); and second, in patients with evidence of progressive RV dilation/dysfunction (received an uncertain/very weak recommendation by AHA/ACC and more favorable recommendation by ESC). An additional consideration should be given to cases of lead-related severe primary TR. Potential surgery in these cases should address both the valve and the lead. The valve-related lead damage can be repaired (suture or patch) and an annuloplasty performed, or the valve can be replaced if the damage is extensive. Options for lead management include extraction and replacement by a pacing method that does not cross the TV (coronary sinus, epicardial, leadless pacing) or lead repositioning, making sure it is secured in a location where it does not interfere with valve function. The latter option can be accomplished by securing the lead in the commissure between 2 leaflets, usually between the posterior and septal leaflet with suture approximation of both leaflets, as described by Raman et al. (51).

**PERCUTANEOUS TREATMENT.** There has been a recent surge in the percutaneous TV repair options (52). However, none of these is specifically designated for lead-related severe TR. Rather, these techniques are primarily aimed to treat functional TR, with some having specifically excluded patients with PPM or defibrillator leads (53,54). Nevertheless, when medical therapy has failed, and the patient is not a surgical candidate, other alternatives can be considered. For example, edge-to-edge repair using a MitraClip (Abbott Vascular, Santa Clara, California) has been performed in 64 patients in Europe, with 30% of patients having a pacing lead (55). In addition, the investigational FORMA transcatheter tricuspid valve repair system (Edwards Lifesciences, Irvine, California) was used in 3 of 18 patients who had a pacemaker lead in place at the time of the intervention (56). Finally, in the Trivalve Registry (International Multisite Transcatheter Tricuspid Valve Therapies Registry [TriValve]; NCT03416166), a large, international registry to evaluate different transcatheter TV approaches, for example, MitraClip (Abbott Vascular), FORMA (Edwards Lifesciences), Trialign (Mitralign, Tewksbury, Massachusetts),

Cardioband (Edwards Lifesciences), caval valve implantation (CAVI), and TriCinch (4TECH, Galway, Ireland), and to investigate patient characteristics, 25 of 206 patients (23.5%) had a transtricuspid pacing lead (57). An additional consideration arises with percutaneous TV replacement. The lead is typically displaced outside the new valve, ring, or stent and is entrapped against the native annulus (58,59). This appears to carry a risk for lead damage, although some reports have suggested that lead function was not impaired, indeed 39% of patients in the VIVID (Valve-in-Valve International Data Registry) for Tricuspid Valve-in-Valve therapy had a prior pacemaker (60). Other reports have suggested that the lead function was not impaired but precludes future transvenous lead extraction in cases of infection. **Figure 8** shows the case of a 79-year-old woman with severe, symptomatic, diuresis-unresponsive, lead-related TR and subsequent RV and TA dilation. Due to prohibitive surgical risk, the patient underwent percutaneous TV replacement with the NaviGate valved stent (NaviGate Cardiac Structures, Inc, NCSI, Lake Forest, California) with a reduction in TR severity together with a normally functioning lead.

**ALTERNATIVE PACING METHODS.** After the lead identified as the culprit causing severe symptomatic TR has been removed, the need for ventricular pacing should be reassessed, and if deemed necessary, alternative pacing strategies that do not interfere with the TV apparatus should be sought. These include His bundle pacing, lead placement in the coronary sinus or epicardium, or use of leadless pacemakers. Among these, His bundle pacing is the “closest” to physiological pacing from both electrical and hemodynamic standpoints, as it preserves normal ventricular activation pathways and prevents ventricular dyssynchrony. However, technical challenges and high capture thresholds have been the major obstacles to widespread use (61). These drawbacks are being addressed by the advent of dedicated sheaths and leads, with reports of improved procedural success and capture thresholds (62,63).

### SUMMARY AND FUTURE DIRECTIONS

---

Although it is clear that CIED-mediated TV dysfunction occurs, what is not clear is its true prevalence and whether it can be avoided. Should patients who are about to undergo device lead placement or lead extraction have a baseline echocardiogram to document TV size and function prior to lead implantation or extraction? Should follow-up echocardiography be

performed in patients after device lead implantation to monitor for TR just as a patient would be monitored for other valvulopathies? At this time, no data exist for surveillance of TR in patients after device lead implantation. From the procedural perspective, should echocardiography (intracardiac, TTE, or TEE) be used to provide intraprocedural guidance in order to confirm commissural position of the device lead prior to lead stabilization? It is not completely clear if TV dysfunction is directly related to the position of the device lead after implantation. It may be true that the lead does not stay in exactly the same position with respect to the TV apparatus overtime. The lead may in fact move at the level of the annulus or with respect to the subvalvular apparatus as time elapses. It may also be true that TV dysfunction does not occur immediately after implantation but occurs weeks or months later when inflammation and fibrosis have occurred. Given that most studies are retrospective, a future multicenter study with long term follow-up would be important to answer these questions. Prospective studies are currently underway to explore the association between device lead implantation and worsening or new TR. Another issue relates to assessment of TR with echocardiography. Newer methods for TR quantification using regurgitant volumes and fractions on 3D datasets may help better quantify TR severity in patients with device leads so that interventions aimed at decreasing the impact of severe TR can be performed earlier to avoid the morbidity associated with severe TR. At this time, cardiac magnetic resonance is not a reliable option for the assessment of TR in patients with device leads as reliable protocols for imaging patients with CIED-leads are still being perfected.

Providing answers to these questions is important as severe TR with evidence of right heart failure confers high morbidity and mortality (3). Perhaps early recognition of this problem in patients with device leads may potentially allow repositioning of the wire or extraction if the problem is recognized early enough versus surgical intervention and/or optimization of medical management if the problem is recognized late. If the problem is recognized too late, corrective options may no longer be available, unless the patient is a candidate for heart transplantation (**Figure 9**).

---

**ADDRESS FOR CORRESPONDENCE:** Dr. Roberto M. Lang, Section of Cardiology, University of Chicago Medical Center, 5758 South Maryland Avenue, MC 9067, Chicago, Illinois 60637. E-mail: [rlang@bsd.uchicago.edu](mailto:rlang@bsd.uchicago.edu).

## REFERENCES

1. Mond HG, Proclemer A. The 11th world survey of cardiac pacing and implantable cardioverter-defibrillators: calendar year 2009—a World Society of Arrhythmia's project. *Pacing and clinical electrophysiology*. *Pacing Clin Electrophysiol* 2011;34:1013-27.
2. Dreyfus GD, Corbi PJ, Chan KM, Bahrami T. Secondary tricuspid regurgitation or dilation: which should be the criteria for surgical repair? *Ann Thorac Surg* 2005;79:127-32.
3. Nath J, Foster E, Heidenreich PA. Impact of tricuspid regurgitation on long-term survival. *J Am Coll Cardiol* 2004;43:405-9.
4. Al-Bawardy R, Krishnaswamy A, Bhargava M, et al. Tricuspid regurgitation in patients with pacemakers and implantable cardiac defibrillators: a comprehensive review. *Clinical Cardiol* 2013;36:249-54.
5. Al-Bawardy R, Krishnaswamy A, Rajeswaran J, et al. Tricuspid regurgitation and implantable devices. *Pacing Clin Electrophysiol* 2015;38:259-66.
6. Arabi P, Ozer N, Ates AH, Yorgun H, Oto A, Aytemir K. Effects of pacemaker and implantable cardioverter defibrillator electrodes on tricuspid regurgitation and right sided heart functions. *J Cardiol* 2015;22:637-44.
7. Chang JD, Manning WJ, Ebrille E, Zimetbaum PJ. Tricuspid valve dysfunction following pacemaker or cardioverter-defibrillator implantation. *J Am Coll Cardiol* 2017;69:2331-41.
8. de Cock CC, Vinkers M, Van Campe LC, Verhorst PM, Visser CA. Long-term outcome of patients with multiple (> or = 3) noninfected transvenous leads: a clinical and echocardiographic study. *Pacing Clin Electrophysiol* 2000;23:423-6.
9. Dellling FN, Hassan ZK, Piatkowski G, et al. Tricuspid regurgitation and mortality in patients with transvenous permanent pacemaker leads. *Am J Cardiol* 2016;117:988-92.
10. Fanari Z, Hammami S, Hammami MB, Hammami S, Shuraih M. The effects of right ventricular apical pacing with transvenous pacemaker and implantable cardioverter defibrillator on mitral and tricuspid regurgitation. *J Electrocardiol* 2015;48:791-7.
11. Hoke U, Auger D, Thijssen J, et al. Significant lead-induced tricuspid regurgitation is associated with poor prognosis at long-term follow-up. *Heart* 2014;100:960-8.
12. Kim JB, Spevack DM, Tunick PA, et al. The effect of transvenous pacemaker and implantable cardioverter defibrillator lead placement on tricuspid valve function: an observational study. *J Am Soc Echocardiogr* 2008;21:284-7.
13. Klutstein M, Balkin J, Butnaru A, Ilan M, Lahad A, Rosenmann D. Tricuspid incompetence following permanent pacemaker implantation. *Pacing Clin Electrophysiol* 2009;32 Suppl 1: S135-7.
14. Lee RC, Friedman SE, Kono AT, Greenberg ML, Palac RT. Tricuspid regurgitation following implantation of endocardial leads: incidence and predictors. *Pacing Clin Electrophysiol* 2015;38:1267-74.
15. Paniagua D, Aldrich HR, Lieberman EH, Lamas GA, Agatston AS. Increased prevalence of significant tricuspid regurgitation in patients with transvenous pacemakers leads. *Am J Cardiol* 1998;82:1130-2.
16. Seo Y, Ishizu T, Nakajima H, Sekiguchi Y, Watanabe S, Aonuma K. Clinical utility of 3-dimensional echocardiography in the evaluation of tricuspid regurgitation caused by pacemaker leads. *Circ J* 2008;72:1465-70.
17. Webster G, Margossian R, Alexander ME, et al. Impact of transvenous ventricular pacing leads on tricuspid regurgitation in pediatric and congenital heart disease patients. *J Interv Card Electrophysiol* 2008;21:65-8.
18. Greenspon AJ, Patel JD, Lau E, et al. Trends in permanent pacemaker implantation in the United States from 1993 to 2009: increasing complexity of patients and procedures. *J Am Coll Cardiol* 2012;60:1540-5.
19. Lee ME, Chau A, Matloff JM. Avulsion of a tricuspid valve leaflet during traction on an infected, entrapped endocardial pacemaker electrode. The role of electrode design. *J Thorac Cardiovasc Surg* 1977;74:433-5.
20. Ong LS, Barold SS, Craver WL, Falkoff MD, Heinle RA. Partial avulsion of the tricuspid valve by tined pacing electrode. *Am Heart J* 1981;102:798-9.
21. Al-Mohaisen MA, Chan KL. Prevalence and mechanism of tricuspid regurgitation following implantation of endocardial leads for pacemaker or cardioverter-defibrillator. *J Am Soc Echocardiogr* 2012;25:245-52.
22. Lin G, Nishimura RA, Connolly HM, Dearani JA, Sundt TM III, Hayes DL. Severe symptomatic tricuspid valve regurgitation due to permanent pacemaker or implantable cardioverter-defibrillator leads. *J Am Coll Cardiol* 2005;45:1672-5.
23. Goldenberg I, Moss AJ, Hall WJ, et al. Causes and consequences of heart failure after prophylactic implantation of a defibrillator in the multicenter automatic defibrillator implantation trial II. *Circulation* 2006;113:2810-7.
24. Marijon E, Trinquart L, Otmani A, et al. Predictors for short-term progressive heart failure death in New York Heart Association II patients implanted with a cardioverter defibrillator—the EVADEF study. *Am Heart J* 2010;159:659-64.
25. Packer DL, Prutkin JM, Hellkamp AS, et al. Impact of implantable cardioverter-defibrillator, amiodarone, and placebo on the mode of death in stable patients with heart failure: analysis from the sudden cardiac death in heart failure trial. *Circulation* 2009;120:2170-6.
26. Addetia K, Maffessanti F, Mediratta A, et al. Impact of implantable transvenous device lead location on severity of tricuspid regurgitation. *J Am Soc Echocardiogr* 2014;27:1164-75.
27. Rajappan K. Permanent pacemaker implantation technique: part II. *Heart* 2009;95:334-42.
28. Postaci N, Eksi K, Bayata S, Yesil M. Effect of the number of ventricular leads on right ventricular hemodynamics in patients with permanent pacemaker. *Angiology* 1995;46:421-4.
29. Zhang HX, Qian J, Hou FQ, Liu YN, Mao JH. Comparison of right ventricular apex and right ventricular outflow tract septum pacing in the elderly with normal left ventricular ejection fraction: long-term follow-up. *Kardiologia Polska* 2012;70:1130-9.
30. Hemayat S, Shafiee A, Oraii S, Roshanali F, Alaadini F, Aldoboni AS. Development of mitral and tricuspid regurgitation in right ventricular apex versus right ventricular outflow tract pacing. *J Interv Card Electrophysiol* 2014;40:81-6.
31. Dilaveris P, Pantazis A, Giannopoulos G, Synetos A, Gialafos J, Stefanadis C. Upgrade to biventricular pacing in patients with pacing-induced heart failure: can resynchronization do the trick? *Europace* 2006;8:352-7.
32. Vaturi M, Kusniec J, Shapira Y, et al. Right ventricular pacing increases tricuspid regurgitation grade regardless of the mechanical interference to the valve by the electrode. *Eur J Echocardiogr* 2010;11:550-3.
33. Byrd CL, Wilkoff BL, Love CJ, et al. Intravascular extraction of problematic or infected permanent pacemaker leads: 1994-1996. U.S. extraction database, MED Institute. *Pacing Clin Electrophysiol* 1999;22:1348-57.
34. Coffey JO, Sager SJ, Gangireddy S, Levine A, Viles-Gonzalez JF, Fischer A. The impact of transvenous lead extraction on tricuspid valve function. *Pacing Clin Electrophysiol* 2014;37:19-24.
35. Rodriguez Y, Mesa J, Arguelles E, Carrillo RG. Tricuspid insufficiency after laser lead extraction. *Pacing Clin Electrophysiol* 2013;36:939-44.
36. Dokainish H, Elbarasi E, Masiero S, et al. Prospective study of tricuspid valve regurgitation associated with permanent leads in patients undergoing cardiac rhythm device implantation: background, rationale, and design. *Glob Cardiol Sci Pract* 2015;2015:41.
37. Addetia K, Yamat M, Mediratta A, et al. Comprehensive two-dimensional interrogation of the tricuspid valve using knowledge derived from three-dimensional echocardiography. *J Am Soc Echocardiogr* 2016;29:74-82.
38. Stankovic I, Daraban AM, Jasaityte R, Neskovic AN, Claus P, Voigt JU. Incremental value of the en face view of the tricuspid valve by two-dimensional and three-dimensional echocardiography for accurate identification of tricuspid valve leaflets. *J Am Soc Echocardiogr* 2014;27:376-84.
39. Wafae N, Hayashi H, Gerola LR, Vieira MC. Anatomical study of the human tricuspid valve. *Surg Radiol Anat* 1990;12:37-41.
40. Xanthos T, Dalivigkas I, Ikemektzoglou KA. Anatomic variations of the cardiac valves and

- papillary muscles of the right heart. *Ital J Anat Embryol* 2011;116:111-26.
41. Hahn RT. State-of-the-art review of echocardiographic imaging in the evaluation and treatment of functional tricuspid regurgitation. *Circ Cardiovasc Imaging* 2016;9(12).
  42. Mediratta A, Addetia K, Yamat M, et al. 3D echocardiographic location of implantable device leads and mechanism of associated tricuspid regurgitation. *J Am Coll Cardiol Img* 2014;7:337-47.
  43. Nishimura RA, Otto CM, Bonow RO, et al. 2014 AHA/ACC guideline for the management of patients with valvular heart disease: a report of the American College of Cardiology/American Heart Association Task Force on Practice Guidelines. *J Am Coll Cardiol* 2014;63:e57-185.
  44. Rickard J, Wilkoff BL. Extraction of implantable cardiac electronic devices. *Curr Cardiol Rep* 2011;13:407-14.
  45. Wilkoff BL, Love CJ, Byrd CL, et al. Transvenous lead extraction: Heart Rhythm Society expert consensus on facilities, training, indications, and patient management: this document was endorsed by the American Heart Association (AHA). *Heart Rhythm* 2009;6:1085-104.
  46. Bongiorni MG, Burri H, Deharo JC, et al. 2018 EHRA expert consensus statement on lead extraction: recommendations on definitions, endpoints, research trial design, and data collection requirements for clinical scientific studies and registries: endorsed by APhRS/HRS/LAHRs. *Europace* 2018;20:1217.
  47. Di Monaco A, Pelargonio G, Narducci ML, et al. Safety of transvenous lead extraction according to centre volume: a systematic review and meta-analysis. *Europace* 2014;16:1496-507.
  48. Mehrotra D, Kejriwal NK. Tricuspid valve repair for torrential tricuspid regurgitation after permanent pacemaker lead extraction. *Texas Heart Inst J* 2011;38:305-7.
  49. Bontempi L, Vassanelli F, Cerini M, et al. Predicting the difficulty of a transvenous lead extraction procedure: validation of the LED index. *J Cardiovasc Electrophysiol* 2017;28:811-8.
  50. Joint Task Force on the Management of Valvular Heart Disease of the European Society of C, European Association for Cardio-Thoracic S, Vahanian A, et al. Guidelines on the management of valvular heart disease (version 2012). *Eur Heart J* 2012;33:2451-96.
  51. Raman J, Sugeng L, Lai DT, Jeevanandam V. Complex tricuspid valve repair in patients with pacer defibrillator-related tricuspid regurgitation. *Ann Thorac Surg* 2016;101:1599-601.
  52. Rodes-Cabau J, Hahn RT, Latib A, et al. Transcatheter therapies for treating tricuspid regurgitation. *J Am Coll Cardiol* 2016;67:1829-45.
  53. Latib A, Mangieri A. Transcatheter tricuspid valve repair: new valve, new opportunities, new challenges. *J Am Coll Cardiol* 2017;69:1807-10.
  54. Taramasso M, Maisano F. Novel Technologies for percutaneous treatment of tricuspid valve regurgitation. *Eur Heart J* 2017;38:2707-10.
  55. Nickenig G, Kowalski M, Hausleiter J, et al. Transcatheter treatment of severe tricuspid regurgitation with the edge-to-edge mitraclip technique. *Circulation* 2017;135:1802-14.
  56. Perlman G, Praz F, Puri R, et al. Transcatheter tricuspid valve repair with a new transcatheter coaptation system for the treatment of severe tricuspid regurgitation: 1-year clinical and echocardiographic results. *J Am Coll Cardiol Intv* 2017;10:1994-2003.
  57. Taramasso M, Hahn RT, Alessandrini H, et al. The International Multicenter TriValve Registry: which patients are undergoing transcatheter tricuspid repair? *J Am Coll Cardiol Intv* 2017;10:1982-90.
  58. Eleid MF, Asirvatham SJ, Cabalka AK, et al. Transcatheter tricuspid valve-in-valve in patients with transvalvular device leads. *Catheterization and cardiovascular interventions: official journal of the Society for Cardiac Angiography and Interventions* 2016;87:E160-5.
  59. Paradis JM, Bernier M, Houde C, et al. Jailing of a pacemaker lead during tricuspid valve-in-valve implantation with an Edwards SAPIEN XT transcatheter heart valve. *Can J Cardiol* 2015;31:819 e9-11.
  60. McElhinney DB, Cabalka AK, Aboulhosn JA, et al. Transcatheter tricuspid valve-in-valve implantation for the treatment of dysfunctional surgical bioprosthetic valves: an international, multicenter registry study. *Circulation* 2016;133:1582-93.
  61. Vijayaraman P, Bordachar P, Ellenbogen KA. The continued search for physiological pacing: where are we now? *J Am Coll Cardiol* 2017;69:3099-114.
  62. Vijayaraman P, Dandamudi G, Worsnick S, Ellenbogen KA. Acute his-bundle injury current during permanent his-bundle pacing predicts excellent pacing outcomes. *Pacing Clin Electrophysiol* 2015;38:540-6.
  63. Sharma PS, Dandamudi G, Naperkowski A, et al. Permanent His-bundle pacing is feasible, safe, and superior to right ventricular pacing in routine clinical practice. *Heart Rhythm* 2015;12:305-12.
  64. Fanari Z, Hammami S, Hammami MB, Shuraih M. The effects of right ventricular apical pacing with transvenous pacemaker and implantable cardioverter defibrillator on mitral and tricuspid regurgitation. *J Electrocardiol* 2015;48:791-7.

---

**KEY WORDS** 3D echocardiography, defibrillator, pacemaker, tricuspid regurgitation, tricuspid valve

---

**APPENDIX** For supplemental videos, please see the online version of this paper.