

## REVIEW ARTICLE

Jane A. Leopold, M.D., *Editor*

## Tricuspid Regurgitation

Rebecca T. Hahn, M.D.

From the Department of Medicine, Columbia University Irving Medical Center, New York–Presbyterian Hospital, New York. Dr. Hahn can be contacted at [rth2@columbia.edu](mailto:rth2@columbia.edu) or at Columbia University Irving Medical Center, New York–Presbyterian Hospital, 177 Fort Washington Ave., New York, NY 10032.

N Engl J Med 2023;388:1876–91.

DOI: 10.1056/NEJMra2216709

Copyright © 2023 Massachusetts Medical Society.

**CME**  
at [NEJM.org](https://www.nejm.org)

THE TRICUSPID VALVE, OFTEN REFERRED TO AS THE FORGOTTEN VALVE, has generated intense interest because of converging factors that make diagnosis and management of tricuspid regurgitation uniquely challenging. Historically, the tricuspid valve was considered to be a passive structure, on the systemic venous side of the heart, without clinically significant function. Surgeons believed that mitral-valve disease was the true culprit and that tricuspid regurgitation was a secondary finding that would resolve after surgical treatment of the primary mitral disease process. Because tricuspid regurgitation is most frequently diagnosed in patients with coexisting conditions, many clinicians have viewed it as an innocent bystander to the more consequential diseases of the left heart and pulmonary vasculature. In the absence of left heart disease, the clinical signs and symptoms of severe tricuspid regurgitation, such as edema, fatigue, and exercise intolerance, are often mistaken for normal signs and symptoms of aging, leading to delays in diagnosis and treatment. Natural history studies highlight the need for early diagnosis; survival is progressively shorter with the increasing severity of tricuspid regurgitation, even after adjustment for coexisting conditions.<sup>1–4</sup> Gaps in our understanding of the tricuspid-valve disease process, diagnostic challenges, and uncertainty about the appropriate timing of interventions have contributed to the high mortality among medically treated patients,<sup>4,5</sup> as well as nonmedically treated patients,<sup>6,7</sup> with severe tricuspid regurgitation.

## ANATOMY

Insight into the anatomical relationship between the tricuspid-valve apparatus and the right atrium, right ventricle, and pulmonary vasculature provides the basis for our current understanding of the pathophysiology of tricuspid regurgitation. The tricuspid valve is the largest valve in the heart and typically has three leaflets of unequal size. However, the number of leaflets may vary in healthy persons, with the most common variant consisting of two posterior leaflets.<sup>8,9</sup> Thinner than mitral-valve leaflets, the tricuspid-valve leaflets are supported by chordae attached to a major anterior papillary muscle along the lateral wall of the midright ventricle, as well as one or more smaller posterior papillary muscles.<sup>10</sup> The anterior papillary muscle supplies chordae to the anterior and posterior leaflets along their line of coaptation, whereas the posterior papillary muscles supply chordae to the posterior leaflet (or leaflets) and the posterior segment of the septal leaflet. The chordal attachments arising either from small septal papillary muscles or directly from the septum are unique to the tricuspid valve and support the anterior segment of the septal leaflet and the adjacent segments of the anterior or posterior leaflet. Given the complex chordal arcades and their attachment sites, the tricuspid valve is sensitive to changes in the position and function of the free wall of the right ventricle, as well as the interventricular septum.

The tricuspid annulus has very little fibrous tissue or collagen. Adipose tissue fills the inter-ventricular space between the right atrium and ventricle on the anterosuperior and inferior sides but not on the septal side.<sup>11</sup> There are sex-related differences in the histologic features of the annulus. Males have more myocardial cells and elastic fibers than do females,<sup>12</sup> and females have a larger annulus, even after correction for heart or body weight.<sup>12,13</sup> The normal annulus is saddle-shaped and dynamic, larger in early diastole and during atrial systole,<sup>13</sup> which allows for large flow volumes under low pressure. Given the large size of the tricuspid valve, benchtop modeling suggests that only 40% annular dilatation may result in clinically significant tricuspid regurgitation, whereas this was seen at 75% annular dilatation in mitral-valve studies.<sup>14</sup>

The right coronary artery and the atrioventricular node are adjacent to the annulus and are important anatomical considerations for surgical or transcatheter interventions. The right coronary artery lies within the atrioventricular groove along nearly the entire anterior and posterior annulus, with the separation narrowing to less than 3 mm inferiorly, placing the vessel at risk for injury with devices that anchor in the annulus.<sup>15</sup> The atrioventricular node and the bundle of His cross the septal leaflet attachment 3 to 5 mm from the anteroseptal commissure, and injury to the node may result in heart block.

#### CLINICAL PRESENTATION

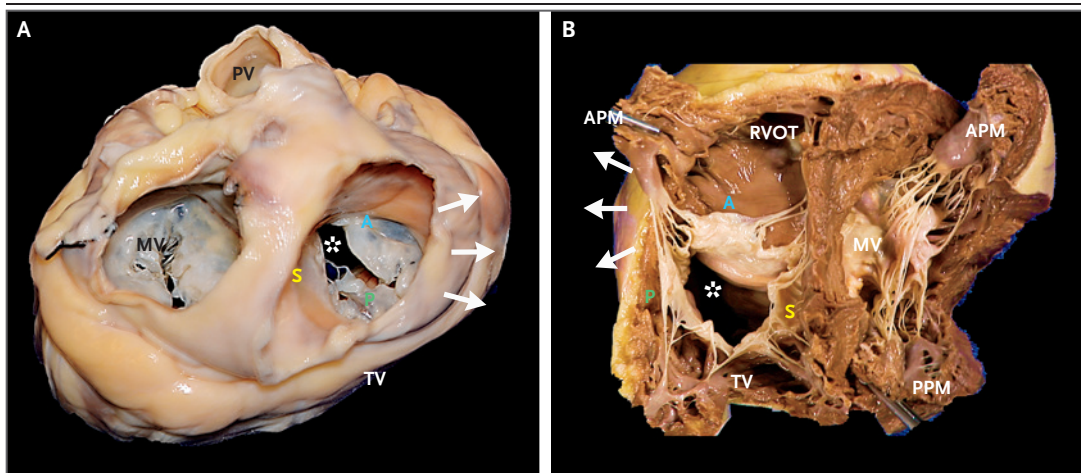
Patients with severe tricuspid regurgitation present with signs and symptoms of chronic right heart failure, including systemic fluid retention, leading to elevated jugular venous pressure, peripheral edema, and ascites; reduced intestinal absorption and anasarca; decreased cardiac reserve, resulting in exercise intolerance, dyspnea, and poor functional capacity; and decreased cardiac output, with progressive end-organ damage caused by a combination of end-organ venous congestion and underperfusion.<sup>16</sup> End-stage disease is associated with cachexia resulting from poor absorption of nutrients, as well as a systemic proinflammatory state. The signs and symptoms of reduced cardiac output may also be mistaken for left heart failure, further delaying

a timely diagnosis of tricuspid regurgitation. Although many signs and symptoms of severe tricuspid regurgitation may initially be responsive to diuretics, reduced cardiac output, as well as other neurohormonal changes, may result in liver disease (the cardiohepatic syndrome) and kidney disease (the cardiorenal syndrome).<sup>16,17</sup> The cardiohepatic syndrome not only increases the risk of bleeding in patients with tricuspid regurgitation but is also a strong independent predictor of death or hospitalization for heart failure within 1 year after transcatheter tricuspid-valve therapy.<sup>18</sup>

Atrial arrhythmias — in particular, atrial fibrillation — are common in patients with tricuspid regurgitation and occur in both incident and progressive valvular disease.<sup>19</sup> Atrial fibrillation has been associated with left and right atrial dilatation, annular dilatation, and atrioventricular valvular regurgitation,<sup>20</sup> and rhythm control is associated with a reduction in tricuspid regurgitation.<sup>21,22</sup> In patients with normal left ventricular function, atrial fibrillation may result in greater tricuspid annular dilatation than mitral annular dilatation.<sup>23</sup> Patients with heart failure and a preserved ejection fraction, with or without atrial fibrillation, also have a high prevalence of prognostically important tricuspid regurgitation resulting from dilatation of the annulus and right atrium.<sup>24,25</sup>

#### EPIDEMIOLOGY

As with other valvular heart diseases, the prevalence of tricuspid regurgitation increases with age.<sup>26-30</sup> Although clinically significant valvular disease is diagnosed more frequently in men than in women,<sup>28</sup> the overall prevalence of clinically significant tricuspid regurgitation may be up to four times as high among women.<sup>26</sup> Female sex is an independent predictor of the severity and progression of tricuspid regurgitation.<sup>4,19,31</sup> Although the basis for these differences is unknown, the higher female prevalence of heart failure with a preserved ejection fraction<sup>32,33</sup> and atrial fibrillation<sup>34</sup> may play a part. Besides older age, female sex, and atrial fibrillation, other clinical predictors of severe and progressive tricuspid regurgitation include elevated pulmonary-artery systolic pressure and increased left atrial size, which suggests that both pre- and postcap-



**Figure 1.** Anatomy of the Tricuspid Valve (TV).

As seen from the atrial aspect (Panel A), the valve has a D-shaped annulus, with the septal leaflet (S) adjacent to the interatrial and interventricular septum, the anterior leaflet (A) posterior to the aorta and pulmonic valve (PV), and the posterior leaflet (P) closest to the diaphragm. In this pathological specimen, the lateral annulus is dilated (arrows), resulting in a large leaflet coaptation gap (asterisk). The subvalvular complex is seen from the ventricular aspect (Panel B), with direct chordae from the septum to the septal and anterior leaflets and a large anterior papillary muscle (APM) supplying chordae to both the anterior and posterior leaflets. Displacement of the APM, caused by dilatation of the mid-to-apical right ventricular free wall (arrows) or a change in the position of the septum, will result in tethering of TV leaflets and a coaptation gap. MV denotes mitral valve, PPM posterior papillary muscle, and RVOT right ventricular outflow tract. Photographs courtesy of Dmitry Levin.

illary pulmonary hypertension contribute to this process.<sup>19</sup>

In two studies of patients with tricuspid regurgitation, medical management of severe disease was associated with 1-year mortality rates of 42% and 36%, respectively.<sup>4,5</sup> As compared with persons who had mild or no tricuspid regurgitation, those with moderate or severe regurgitation had a long-term risk of death from any cause that was increased by a factor of 2.0 to 3.2, after adjustment for age and sex.<sup>4</sup> Even mild tricuspid regurgitation was associated with a nearly 30% increase in all-cause, long-term mortality.<sup>4</sup> A recent study of outcomes for aortic, mitral, and tricuspid-valve disease showed that all-cause mortality was higher for tricuspid regurgitation (hazard ratio, 2.74; 95% confidence interval [CI], 2.24 to 3.37) than for aortic-valve disease (hazard ratio, 1.62; 95% CI, 1.44 to 1.82) or mitral-valve disease (hazard ratio, 1.25; 95% CI, 1.09 to 1.44).<sup>29</sup>

Morphologic predictors of progressive tricuspid regurgitation depend on the primary cardiovascular disease process. For patients with pulmonary arterial hypertension, predictors include right ventricular enlargement, increased right ven-

tricular sphericity, tricuspid annular dilatation, and increased tricuspid leaflet tenting area.<sup>35</sup> For patients with atrial fibrillation, the presence of tricuspid-valve tethering, increased left atrial volume, increased tricuspid annular diameter, and right ventricular remodeling predict severe tricuspid regurgitation.<sup>36</sup> Rapid progression to severe tricuspid regurgitation has been independently associated with all-cause mortality, and predictors of rapid progression include the presence of pacemaker or defibrillator leads, mild tricuspid regurgitation (vs. none), tricuspid annular dilatation, and any valvular heart surgery without concomitant tricuspid-valve surgery.<sup>31</sup> In patients who have undergone mitral-valve surgery, the progression of tricuspid regurgitation is associated with clinical adverse events.<sup>37</sup>

#### CAUSES AND CLASSIFICATION

The atrioventricular valves promote the transit of blood into the ventricles during diastole and prevent regurgitation during systole. Functioning under lower pressures, the right heart ejects the same stroke volume as the high-pressure left heart but in the presence of a closed mitral valve,

thus relying on the compliance of the pulmonary vasculature and left atrium. The large tricuspid-valve apparatus is particularly suited to optimizing diastolic filling of the right ventricle (Fig. 1), with the dynamic motion of the lateral annulus during ventricular relaxation (from the apex toward the base) allowing passive transfer of right atrial blood volume into the right ventricle. Changes in leaflet structure and annular size and dynamics, as well as changes in right ventricular support structures or function, can disrupt tricuspid-valve function.

The traditional subdivision of tricuspid regurgitation into primary leaflet disorders and secondary (nonleaflet) disorders has been refined with the current classification scheme, reflecting a more comprehensive understanding of different mechanisms of tricuspid regurgitation<sup>38,39</sup> and their associated outcomes.<sup>40,41</sup> Secondary tricuspid regurgitation has been subdivided into atrial secondary tricuspid regurgitation and ventricular secondary tricuspid regurgitation, and tricuspid regurgitation associated with a lead from a cardiac implantable electronic device is now a distinct category, separate from primary causes (Fig. 2).

#### PRIMARY TRICUSPID REGURGITATION

Primary tricuspid regurgitation occurs as a result of intrinsic valve disease and is attributable to congenital anomalies, infective endocarditis, rheumatic disease, carcinoid heart disease, toxic effects of chemicals, tumors, blunt trauma, or myxomatous degeneration. Congenital tricuspid regurgitation includes Ebstein's anomaly, tricuspid atresia, and the presence of a cleft valve typically associated with an atrioventricular canal defect, all of which are rare. An initial presentation of Ebstein's anomaly in adulthood is common and is frequently accompanied by atrial arrhythmias; however, biventricular failure and ventricular arrhythmias are associated with reduced survival.<sup>42</sup>

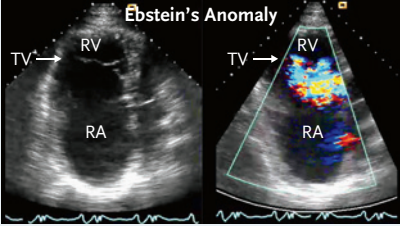
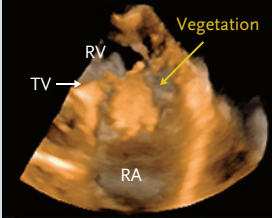
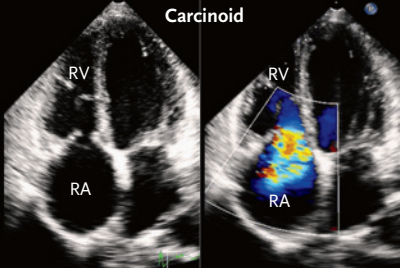
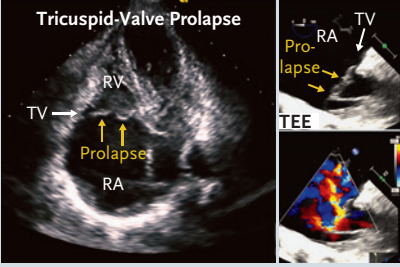
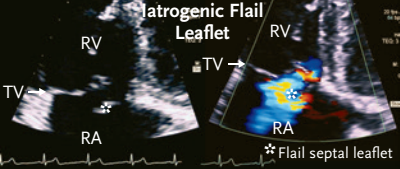
The incidence of tricuspid-valve endocarditis in the United States is increasing in parallel with increases in intravenous drug use, antibiotic resistance, and use of cardiac implantable electronic devices.<sup>43</sup> The use of AngioVac-assisted vegetation debulking is also increasing,<sup>44</sup> and a recent meta-analysis of 44 studies that included 301 patients undergoing this procedure showed that the vegetation size was reduced by more

than 50% in 89.2% of the patients.<sup>45</sup> Although valvectomy may be associated with higher operative mortality,<sup>46</sup> a meta-analysis of surgical management of infective tricuspid-valve endocarditis showed no significant difference in short-term outcomes between valvectomy and surgical valve replacement.<sup>47</sup> Nonetheless, valvectomy remains a controversial management strategy but may be an acceptable bridge to definitive surgery.<sup>48</sup> There is probably no difference in outcomes between repair and replacement, although repair is associated with a lower risk of a need for a permanent pacemaker.<sup>49</sup>

Thickening and restriction of tricuspid leaflet motion are commonly seen with rheumatic or carcinoid tricuspid-valve disease. Concomitant surgical management of rheumatic tricuspid regurgitation at the time of mitral-valve surgery reduces the progression of tricuspid regurgitation if the baseline disease is mild,<sup>50</sup> with an improvement in long-term survival when the baseline disease is moderate or severe (hazard ratio for death, 0.44; 95% CI, 0.23 to 0.87).<sup>51</sup> Carcinoid heart disease, which occurs in 20 to 50% of patients with the carcinoid syndrome, is due to fibrosis and endocardial thickening of the heart valves, probably as the result of chronic exposure of valve tissue to high levels of serotonin. Valve replacement for tricuspid regurgitation due to carcinoid heart disease may be challenging because of the systemic effects of the carcinoid syndrome, especially in patients with impaired hepatic function. The short-term mortality associated with valve replacement may be lower with earlier intervention and with careful preoperative planning.<sup>52</sup>

Other causes of primary tricuspid regurgitation include traumatic rupture of the tricuspid-valve apparatus from blunt chest trauma, a rare condition that may go undiagnosed until the chronic effects of volume overload result in symptoms of right heart failure.<sup>53,54</sup> The overall prevalence of tricuspid regurgitation after heart transplantation is approximately 20% but is highest in the first month after transplantation and decreases over time. There are multiple causes of tricuspid regurgitation in the transplanted heart. However, late tricuspid regurgitation in the recipient of a heart transplant is predominantly related to cardiac allograft vasculopathy and endomyocardial biopsy procedures.<sup>55</sup>



Causative Disease Process	Mechanism	Examples
<b>Primary tricuspid regurgitation (5–10% of cases)</b>		
Congenital anomaly	Apical displacement (e.g., Ebstein's anomaly) or leaflet defect (e.g., AV canal or tricuspid hypoplasia)	
Infection	Endocarditis	
Infiltrative process	Leaflet infiltration (due to tumor, carcinoid, or drugs) or fibrosis (due to rheumatic disease or radiation-related valvulopathy)	
Degenerative disease	Prolapse or flail leaflet	
Trauma or iatrogenic cause	Leaflet avulsion or damage (from trauma, biopsy, or lead extraction)	

**Figure 2. Classification of Tricuspid Regurgitation (TR) According to Cause and Presenting Abnormalities.**

AV denotes atrioventricular, CIED cardiovascular implantable electronic device, CTEPH chronic thromboembolic pulmonary hypertension, HFpEF heart failure with preserved ejection fraction, HFrEF heart failure with reduced ejection fraction, IAS interatrial septum, LAD left anterior descending artery, LVH left ventricular hypertrophy, MRI magnetic resonance imaging, PAH pulmonary arterial hypertension, PH pulmonary hypertension, PM papillary muscle, RA right atrial, RV right ventricular, 3D SAX three-dimensional short-axis view, TA tricuspid annular, TEE transesophageal echocardiography, and TTE transthoracic echocardiography.

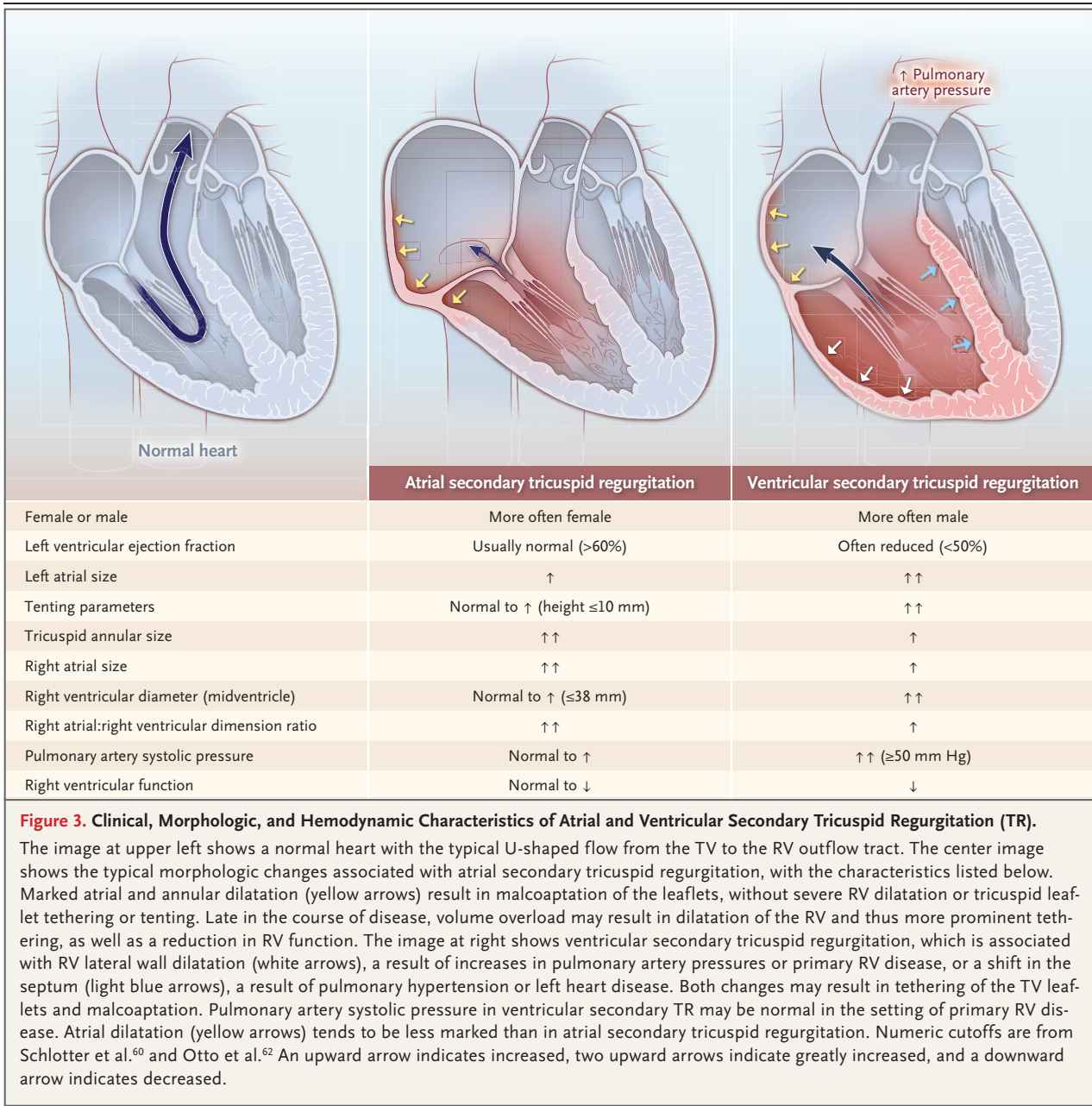
Causative Disease Process	Mechanism	Examples
<b>Secondary tricuspid regurgitation (approximately 80% of cases)</b>		
Ventricular secondary tricuspid regurgitation	Postcapillary PH due to left ventricular disease (HFpEF or HFrEF) or left valvular disease	
	Precapillary PH due to primary pulmonary arterial or pulmonary parenchymal disease (e.g., PAH, chronic lung disease, or CTEPH)	
	Primary RV dysfunction or remodeling (due to RV infarct or RV cardiomyopathy)	
Atrial secondary tricuspid regurgitation	RA or TA dilatation (related to age, atrial fibrillation, or HFpEF)	
<b>CIED-related tricuspid regurgitation (approximately 10–15% of cases)</b>		
Lead-related tricuspid regurgitation	Causative: leaflet impingement, perforation, or valvular or subvalvular adhesions or restriction	
	Incidental: presence of CIED without interference in valvular apparatus	

Figure 2. (Continued.)

**SECONDARY TRICUSPID REGURGITATION**

In patients with secondary tricuspid regurgitation, the intrinsic structure of the leaflets appears normal, but there can be abnormalities of

the right atrium, tricuspid annulus, or right ventricle that result in leaflet malcoaptation (Fig. 3). Atrial abnormalities are seen in 10 to 25% of patients with secondary tricuspid regur-



gitation.<sup>56-58</sup> Atrial secondary tricuspid regurgitation is characterized by normal-appearing leaflets that fail to coapt in the presence of marked annular and atrial dilatation. The leaflets exhibit minimal tethering or tenting, and the right ventricular structure and function are typically normal.<sup>56,59-61</sup> Atrial secondary tricuspid regurgitation is associated with the presence of atrial fibrillation, a normal left ventricular ejection fraction, minimal elevation of pulmonary-artery

pressures, and the absence of left-side valve disease.<sup>62</sup> Long-standing atrial secondary tricuspid regurgitation may also be associated with progressive right ventricular dilatation and may have a mixed morphologic appearance, with tethering of the leaflets.

Patients with ventricular secondary tricuspid regurgitation have dilatation of the right ventricle (mainly the midventricular free wall), leading to apical displacement of the papillary muscles

and tethering of the leaflets.<sup>56,59,63</sup> Right ventricular dilatation and dysfunction are most frequently due to remodeling in the context of elevated pulmonary-artery pressures resulting from precapillary or postcapillary pulmonary hypertension. However, ventricular secondary tricuspid regurgitation may also be attributable to other causes of right ventricular remodeling, including primary cardiomyopathies with right ventricular involvement, right ventricular ischemia, and infarction and arrhythmias.<sup>64</sup> In addition, left ventricular dilatation or dysfunction or concomitant left-side valvular disease may be present, contributing to septal abnormalities that may affect septal leaflet tethering and coaptation.

Discriminating atrial tricuspid regurgitation from the ventricular forms has prognostic and treatment implications.<sup>56,65-67</sup> Patients with ventricular secondary tricuspid regurgitation (and either pulmonary arterial hypertension or left heart disease) have higher mortality than patients with atrial secondary tricuspid regurgitation or primary disease.<sup>68</sup> In a study involving 211 patients with secondary tricuspid regurgitation, the ventricular form was associated with a risk of death or hospitalization for heart failure that was 2.7 times (95% CI, 1.3 to 5.7) the risk with the atrial form. Outcomes were predicted on the basis of the severity of tricuspid regurgitation in the group of patients with atrial secondary tricuspid regurgitation and on the basis of both the severity of tricuspid regurgitation and right ventricular function in those with ventricular secondary tricuspid regurgitation.<sup>56</sup> A large retrospective registry study supports these findings.<sup>69</sup> Risk scores for medically treated and surgically treated patients (see the Supplementary Appendix, available with the full text of this article at NEJM.org) require further validation.

#### TRICUSPID REGURGITATION ASSOCIATED WITH AN IMPLANTABLE ELECTRONIC DEVICE

Although tricuspid regurgitation associated with cardiac implantable electronic devices was once categorized as a primary form of tricuspid regurgitation, it has features of both primary and secondary tricuspid regurgitation.<sup>70-72</sup> However, implantable electronic device–induced tricuspid regurgitation has distinct epidemiologic features and management and therapeutic options. The diagnosis can be made noninvasively with the use of advanced imaging techniques such as

three-dimensional echocardiography<sup>71</sup> and computed tomography (CT),<sup>73</sup> although in most studies, electronic device interference with valve function has been assumed in patients with worsening tricuspid regurgitation.<sup>74,75</sup> Device leads can interfere with any component of the tricuspid-valve apparatus.<sup>71</sup>

The proportion of patients with tricuspid regurgitation related to or mediated by a cardiac implantable electronic device is expected to increase because of the aging of the population, an increasing number of device implantations, and device complications requiring lead extraction.<sup>31,76,77</sup> Approximately 25 to 29% of patients with permanent pacemakers have tricuspid regurgitation,<sup>78</sup> and the cardiac implantable electronic device is thought to be the cause of tricuspid regurgitation in 7 to 45% of patients.<sup>71</sup> In one study, moderate-to-severe tricuspid regurgitation occurred in 27% of patients after implantation of a cardiac implantable electronic device and was associated with an increased number of hospitalizations for heart failure.<sup>74</sup> However, not all cardiac implantable electronic devices cause tricuspid regurgitation; it may instead be an incidental finding. In one study, up to 60% of cases of worsened tricuspid regurgitation after implantation of a cardiac implantable electronic device were of another origin, such as atrial fibrillation or previous open-heart surgery.<sup>79</sup> If tricuspid regurgitation is caused by the cardiac implantable electronic device, lead removal performed in a timely fashion may prevent the development of severe right ventricular dilatation and dysfunction,<sup>80</sup> but removal results in worsening of tricuspid regurgitation in approximately 10% of patients, with injury to the valve in approximately 3%.<sup>81</sup>

#### DIAGNOSIS

Echocardiography remains the primary imaging technique for identifying the cause, morphologic features, and severity of tricuspid regurgitation, with the recognition that cardiac magnetic resonance imaging (MRI) and cardiac CT have expanding roles, particularly for patients who are being considered for transcatheter therapies.<sup>39</sup>

Echocardiography guidelines recommend a multiparametric approach to assess tricuspid regurgitation, with the use of a three-grade scheme (mild [1+], moderate [2+], and severe



[3+]) to describe the degree of regurgitation.<sup>39,82</sup> However, patients presenting for catheter-based interventions frequently present late in the disease process, and an extended grading scheme (severe [3+], massive [4+], and torrential [5+]) was developed to more precisely describe the severity of tricuspid regurgitation in such patients (Table S1 in the Supplementary Appendix).<sup>83</sup> Data from early trials of transcatheter therapy for tricuspid regurgitation that used this grading scheme showed that even improvement limited to a single grade reduction was associated with short-term improvement in functioning and quality of life.<sup>84,85</sup> An additional study has shown that the extended severity of tricuspid regurgitation grades are associated with worse outcomes.<sup>86</sup> In light of these results, the European Society of Cardiology<sup>77</sup> and European Association of Cardiovascular Imaging<sup>39</sup> guidelines suggest use of the five-grade scheme to subcategorize patients referred for transcatheter intervention. Color Doppler imaging is not recommended as the primary method for assessing the severity of tricuspid regurgitation, given the lower pressures of the right heart and the potential to underestimate severity. When mild tricuspid regurgitation is seen on color Doppler imaging, patients should undergo a comprehensive, multiparametric, and multimodal echocardiographic assessment.<sup>39,77</sup>

Cardiac MRI is considered the reference standard for assessing right ventricular chamber size and volumes and can be used to quantify the severity of tricuspid regurgitation.<sup>39,82,87</sup> A regurgitant volume of at least 45 ml or a regurgitant fraction of at least 50% may identify patients at highest risk for death.<sup>87</sup> In general, cardiac MRI is indicated when the echocardiographic assessment is suboptimal or there is discordance between the echocardiographic grading of tricuspid regurgitation and the patient's clinical presentation. A comprehensive cardiac MRI study also quantitates cardiac remodeling (both atrial and ventricular) and provides insights into the mechanism of tricuspid regurgitation. Alternatively, three-dimensional echocardiography may be useful for assessing right ventricular and tricuspid annular dimensions.<sup>59,88</sup> Cardiac CT may also confirm chamber remodeling, with planimetric assessment of the anatomical orifice area in determining the severity of tricuspid regurgitation still investigational. In addition, CT has become a

standard imaging technique for assessment of the tricuspid valve and right heart in patients who are candidates for transcatheter device therapies.<sup>38</sup>

## THERAPY

### MEDICAL AND RHYTHM MANAGEMENT

In the absence of robust evidence, guideline-directed medical therapy for tricuspid regurgitation is currently limited to diuretics and the treatment of underlying causes of secondary tricuspid regurgitation, both of which are class IIa recommendations.<sup>39,62,77,89</sup> Although congestive symptoms associated with tricuspid regurgitation can respond initially to diuretics, unresponsiveness may develop as a result of neurohormonal activation (i.e., up-regulation of the renin-angiotensin-aldosterone system axis), an increased volume of diuretic distribution, visceral edema causing impaired drug absorption and tubular drug delivery, and rebound sodium absorption in the hypertrophied distal renal nephrons.<sup>16</sup> In patients with tricuspid regurgitation who are being treated for heart failure, diuretic resistance is associated with a worse prognosis,<sup>90</sup> and stage D right heart failure, defined as refractory right heart failure at rest,<sup>17</sup> is associated with an increased risk of death.<sup>91</sup> A stepwise approach to diuretic management is suggested, with loop diuretics initially used to reduce volume load and thereby reduce pulmonary pressures (i.e., right ventricular afterload) and mineralocorticoid antagonists in natriuretic doses added to reduce decongestion in patients with more advanced disease.

Medical treatment of secondary tricuspid regurgitation requires a comprehensive evaluation of the type and severity of pulmonary hypertension, assessment of left ventricular function, and consideration of rhythm control for atrial fibrillation.<sup>62,77</sup> Current management of pulmonary arterial hypertension requires an understanding of the underlying arterial disease and directed therapy to promote pulmonary vasodilatation or reduce pulmonary vasoconstriction.<sup>92</sup> Because of the poor prognosis for patients with tricuspid regurgitation and precapillary pulmonary hypertension, recent European Society of Cardiology and European Association for Cardio-Thoracic Surgery guidelines for managing pulmonary hypertension give a class I recommendation for right heart catheterization in patients who have

severe tricuspid regurgitation with or without left heart disease, before surgical or catheter-based valve interventions are performed.<sup>92</sup> Medical treatment of pulmonary arterial hypertension is associated with right ventricular reverse remodeling and reversal of tricuspid annular dilatation, tricuspid-valve tenting, and regression of tricuspid regurgitation, with improved clinical outcomes.<sup>35</sup>

Guideline-directed medical management of heart failure affects clinical outcomes and should be instituted.<sup>93</sup> There are few studies that assess the direct effect of first-line therapeutics for left heart failure on tricuspid regurgitation. In one study of cardiac resynchronization therapy,<sup>94</sup> approximately 41% of patients had a reduction in the severity of tricuspid regurgitation after undergoing cardiac resynchronization therapy for left heart failure, and this improvement was associated with improved clinical outcomes. Severe tricuspid regurgitation at follow-up after cardiac resynchronization therapy was independently associated with all-cause mortality. Other studies have shown that guideline-directed medical treatment of left heart failure may lead to changes in left heart hemodynamics that could reduce tricuspid regurgitation — specifically, a reduction in mitral regurgitation and improvements in left ventricular systolic and diastolic function.<sup>93</sup>

Reduction of mitral regurgitation with the use of transcatheter devices has also been associated with an improvement in tricuspid regurgitation. In a study of mitral transcatheter edge-to-edge repair (TEER) for severe secondary mitral regurgitation, more than one third of patients had a reduction in tricuspid regurgitation soon after the intervention.<sup>95</sup> This improvement was associated with reduced heart failure symptoms and lower mortality, as compared with unchanged or worsened tricuspid regurgitation. Tricuspid regurgitation of 2+ or less, regardless of the baseline grade, was independently associated with a 42% reduction in the relative risk of long-term death from any cause.

Atrial fibrillation is a common clinical feature in patients with atrial secondary tricuspid regurgitation.<sup>20,24,60</sup> Active restoration of sinus rhythm through cardioversion or ablation results in a reduction in both right and left atrial volumes, leading to improvement in tricuspid regurgitation.<sup>21,22</sup>

## SURGICAL MANAGEMENT

The late presentation of patients with severe symptomatic tricuspid regurgitation is largely responsible for the 10 to 12% in-hospital mortality associated with isolated surgical tricuspid-valve replacement.<sup>6,7</sup> Guidelines give a class I level of recommendation for surgical treatment of severe tricuspid regurgitation at the time of left heart surgery.<sup>62</sup> Management of severe, symptomatic secondary tricuspid regurgitation remains controversial, in part because of the heterogeneous patient population, the delay in diagnosis resulting from a late clinical presentation, and the absence of appropriate risk scores (see the discussion in the Supplementary Appendix and Fig. S1). The guidelines give a class IIa recommendation for isolated tricuspid-valve surgery for symptomatic, severe primary tricuspid regurgitation or symptomatic, severe secondary tricuspid regurgitation in patients in whom medical therapy has failed and who have no pulmonary hypertension or left heart disease. Given the high mortality rate associated with reoperation, guidelines give a class IIb recommendation for tricuspid-valve surgery in patients with symptomatic, severe tricuspid regurgitation and prior left-sided valve surgery in the absence of severe pulmonary hypertension or right ventricular systolic dysfunction. A class IIb recommendation is also given for surgical intervention in patients with severe, asymptomatic primary tricuspid regurgitation and progressive right ventricular dilatation or dysfunction.

The new classification of atrial and ventricular secondary tricuspid regurgitation based on valvular and ventricular morphologic features is supported by the differences in surgical annuloplasty outcomes.<sup>38</sup> Although surgical repair with an annuloplasty ring is the preferred procedure, recurrent tricuspid regurgitation is seen more frequently in patients with marked tethering of the leaflets and right ventricular dysfunction — features of ventricular secondary tricuspid regurgitation — prompting surgeons to replace valves in these patients.<sup>62,77</sup> Given the association of tricuspid-valve tethering and right ventricular remodeling with disease that is chronic and severe, adjusted outcomes for repair and replacement therapies do not appear to differ substantially, although the outcomes are more favorable with valve replacement in patients with a tricuspid annular diameter larger than 44 mm.<sup>96</sup>

**Table 1. Current Transcatheter Devices.**

Strategy	Ideal Anatomy
Annuloplasty (direct and indirect) devices	Annular dilatation as primary mechanism of tricuspid regurgitation Mild tethering (tenting height <0.76 cm, tenting area <1.63 cm <sup>2</sup> , and three-dimensional tenting volume <2.3 ml) Central jet location Sufficient landing zone for anchoring
Leaflet coaptation devices	Small septolateral gap ≤7 mm Anteroseptal jet location Confined prolapse or flail region if degenerative disease Trileaflet morphology
Heterotopic valve implantation (in inferior vena cava or both inferior and superior venae cavae)	Appropriate caval diameters or intercaval distances No other direct valve treatment option Preserved right ventricular function Reversal of flow in hepatic vein due to tricuspid regurgitation
Orthotopic valve replacement	Previous surgical repair or bioprosthetic valve replacement Leaflet thickening or shortening (rheumatic cause, carcinoid) feasible depending on anchoring Incidental or causative cardiac implantable electronic device feasible depending on anchoring Any leaflet morphology

**TRANSCATHETER MANAGEMENT**

Transcatheter solutions are being pursued aggressively as lower-risk interventions in higher-risk patients with tricuspid regurgitation (Table 1). Leveraging the success of the TEER devices for mitral regurgitation, proceduralists began using the commercially available mitral-valve devices to treat tricuspid regurgitation. Given the wide availability of this device, tricuspid TEER currently remains the most common transcatheter therapy around the world.<sup>38</sup>

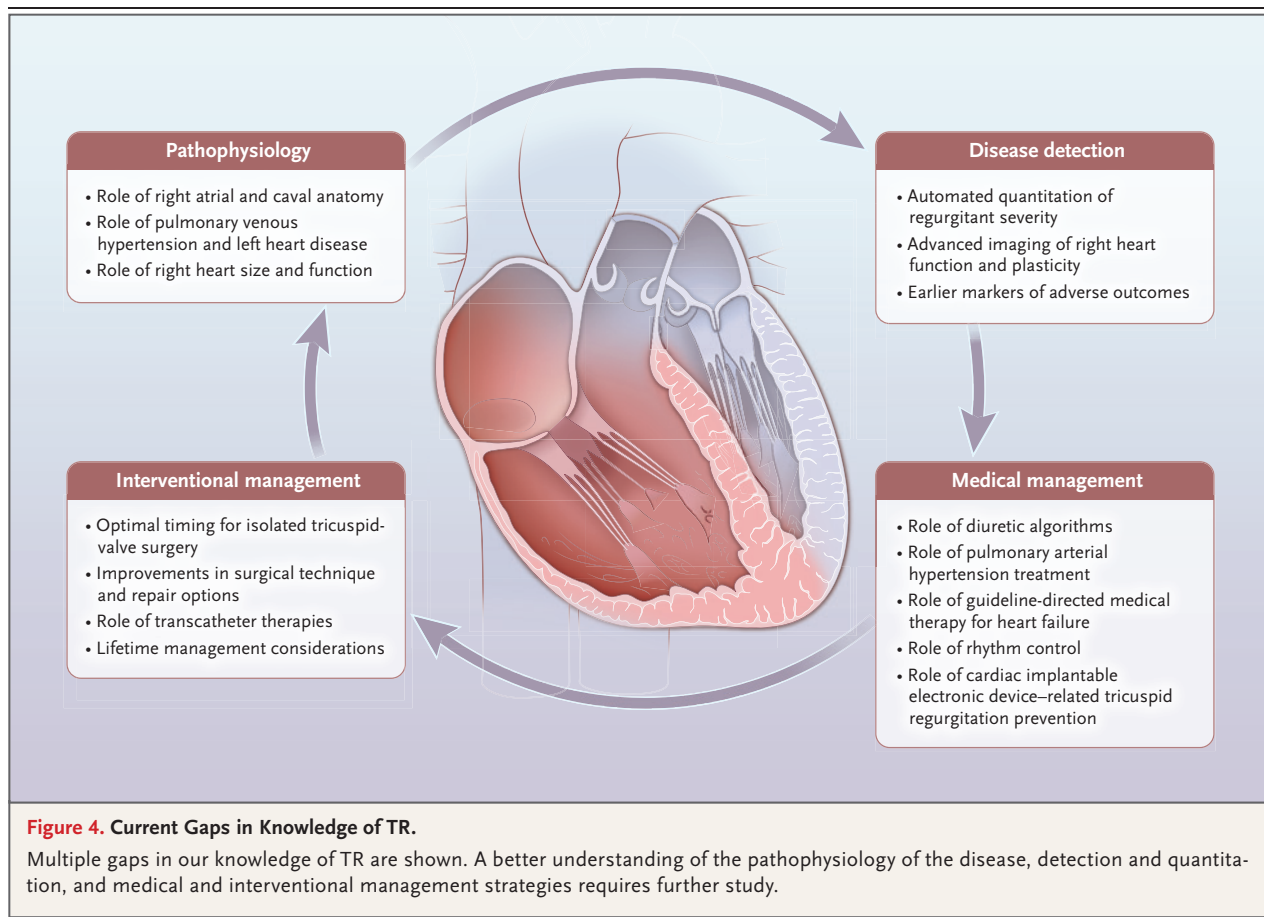
The multinational TriValve Registry was developed to better understand the characteristics of patients undergoing transcatheter interventions and the treatment outcomes.<sup>97</sup> In a study of registry data, the average age ( $\pm$ SD) of the patients was  $76\pm 9$  years and 60.4% were women. More than one third of the patients had previously undergone left heart surgery (in most cases, valve surgery), and 79.0% were in permanent atrial fibrillation. Peripheral edema was observed in 81.0% of the patients, and 27.3% had ascites, despite the maximal tolerated diuretic therapy. A total of 56.6% of the patients had been hospitalized in the preceding 6 months

for right ventricular heart failure. The baseline median N-terminal pro-B-type natriuretic peptide level was 2253 pg per milliliter (interquartile range, 1416 to 5252), and nearly all the patients were being treated with a diuretic. These clinical characteristics have been consistent among patients treated with a transcatheter tricuspid valve.<sup>98</sup>

When patients in the registry were propensity-matched with a medically treated cohort, transcatheter tricuspid-valve intervention was associated with a lower incidence ( $\pm$ SD) of the composite end point of death and rehospitalization ( $32\pm 4\%$  vs.  $49\pm 3\%$ ), as well as a lower incidence of the individual outcomes of death ( $23\pm 3\%$  vs.  $36\pm 3\%$ ) and rehospitalization ( $26\pm 3\%$  vs.  $47\pm 3\%$ ).<sup>5</sup> A meta-analysis that included 21 transcatheter device studies showed an overall mortality of 5% (95% CI, 4 to 8) at 30 days, and an analysis of 6 studies showed an overall mortality of 25% (95% CI, 12 to 45) at 1 year.<sup>98</sup> Outcomes were improved for patients in whom the procedure was successful, with success defined as a reduction in the tricuspid regurgitation grade to 2+ or less, as compared with those in whom the procedure failed (odds ratio, 0.42; 95% CI, 0.27 to 0.66).<sup>98</sup>

Predictors of short- and long-term outcomes after transcatheter interventions remain ill defined, in part because of the wide range of coexisting conditions in patients who undergo these procedures, as well as the range of pathophysiological and morphologic features that define the anatomical restrictions for specific device therapies. As with surgical repair, isolated transcatheter annuloplasty devices may be most useful primarily in patients who have annular dilatation without marked leaflet tethering. The success of the TEER devices has been studied most extensively, with the location of the regurgitant jet, leaflet coaptation gap, extent of pacemaker lead impingement, complexity of leaflet structure, and chordal density identified as the major determinants of success.<sup>38</sup> These limitations may result in reduced efficacy of the device. TEER devices can reduce tricuspid regurgitation to moderate or less in 80 to 85% of patients and to mild or less in only 30 to 50% of patients.

Early feasibility studies suggested that the class of device with the greatest efficacy in reducing tricuspid regurgitation is the orthotopic



tricuspid-valve replacement, which reduces tricuspid regurgitation to mild or less in more than 90% of patients; mortality at 1 year may be lower with this intervention than 1-year mortality in natural history studies of severe tricuspid regurgitation and in recent meta-analyses of mainly repair devices.<sup>99</sup> Elimination of tricuspid regurgitation, however, is associated with an increase in effective afterload to the right ventricle and unmasking of mechanical dysfunction, which may limit the hemodynamic benefits of this device. Despite reductions in right ventricular function, however, improvements in forward stroke volume can be seen.<sup>100</sup>

Device therapy continues to evolve, and both early feasibility studies and randomized, controlled trials of transcatheter devices as compared with medical therapy will help define the appropriate treatment, patient population, and management approach. These trials should help fill the current gaps in our understanding of optimal medical therapy and anatomical limita-

tions of specific devices, as well as the efficacy of the devices and their impact on outcomes. Understanding the role of left ventricular dysfunction, pulmonary arterial hypertension, right ventricular dysfunction, and concomitant valvular heart disease, as well as renal and hepatic dysfunction, will also help inform physicians about treatment options.

The marked improvements in functioning and quality of life that patients with severe, symptomatic tricuspid regurgitation had in early device feasibility trials<sup>84,85</sup> contributed to the justification for the Trial to Evaluate Cardiovascular Outcomes in Patients Treated with the Tricuspid Valve Repair System Pivotal (TRLUMINATE Pivotal) to use a novel hierarchical end point of three outcomes: death from any cause or tricuspid-valve surgery, hospitalization for heart failure, and an improvement in quality of life as measured with a patient-reported outcomes instrument.<sup>101</sup> After 1 year of follow-up, the incidence of death or tricuspid-valve surgery and



the rate of hospitalization for heart failure did not differ significantly between the device and medical therapy groups; however, the trial met the primary end point because of significant improvements in the quality-of-life measure (win ratio, 1.48; 95% CI, 1.06 to 2.13;  $P=0.02$ ). The results of this trial have highlighted gaps in our understanding of TEER in patients with severe tricuspid regurgitation: what are the benefits of device therapy, who are the patients who may benefit from it, and how can we predict a good outcome? As both device and surgical therapies continue to evolve, and optimal medical management is better defined, the answers to these questions are likely to be forthcoming.

#### CONCLUSIONS AND FUTURE DIRECTIONS

The grim natural history of tricuspid regurgitation has stimulated the search for a better understanding of the pathophysiology of the disease, early detection, optimal medical management, and ideal interventional timing and technique. Our understanding of clinical outcomes for patients with tricuspid regurgitation continues to expand, with the most recent large observational study suggesting that even mild tricuspid-valve disease is associated with reduced long-term survival.<sup>4</sup> Recognition of the complexity of tricuspid-valve disease has led to a better

classification scheme, which is supported by studies showing differences in patient outcomes that are associated with the refined disease categories.<sup>56</sup> Finally, there has been rapid growth in the development of less invasive transcatheter options for disease management as a means of overcoming the reported poor outcomes of isolated tricuspid-valve surgery.<sup>38</sup>

The pitfalls of current algorithms for detecting tricuspid-valve disease have necessitated the adoption of new methods for quantitation and grading of tricuspid regurgitation and have fostered an appreciation of the role of the right heart and pulmonary vasculature. Because of our nascent understanding of the pathophysiology, detection, and medical management of tricuspid regurgitation, patients are sent for surgical intervention late in the disease process, thereby increasing the risk of adverse outcomes. In this new era of transcatheter therapeutics, the number of devices to treat tricuspid regurgitation is rapidly increasing. Several knowledge gaps, however, impede our management of severe, symptomatic tricuspid regurgitation (Fig. 4). Improvement in outcomes will rely heavily on early recognition of tricuspid regurgitation by clinicians and referral to a level 1 comprehensive valve center, which has the medical, surgical, and interventional expertise to evaluate and manage this complex disease.<sup>62</sup>

Disclosure forms provided by the author are available with the full text of this article at NEJM.org.

#### REFERENCES

1. Wang N, Fulcher J, Abeysuriya N, et al. Tricuspid regurgitation is associated with increased mortality independent of pulmonary pressures and right heart failure: a systematic review and meta-analysis. *Eur Heart J* 2019;40:476-84.
2. Messika-Zeitoun D, Verta P, Gregson J, et al. Impact of tricuspid regurgitation on survival in patients with heart failure: a large electronic health record patient-level database analysis. *Eur J Heart Fail* 2020;22:1803-13.
3. Chorin E, Rozenbaum Z, Topilsky Y, et al. Tricuspid regurgitation and long-term clinical outcomes. *Eur Heart J Cardiovasc Imaging* 2020;21:157-65.
4. Offen S, Playford D, Strange G, Stewart S, Celermajer DS. Adverse prognostic impact of even mild or moderate tricuspid regurgitation: insights from the national echocardiography database of Australia. *J Am Soc Echocardiogr* 2022;35:810-17.
5. Taramasso M, Benfari G, van der Bijl P, et al. Transcatheter versus medical treatment of patients with symptomatic severe tricuspid regurgitation. *J Am Coll Cardiol* 2019;74:2998-3008.
6. Scotti A, Sturla M, Granada JF, et al. Outcomes of isolated tricuspid valve replacement: a systematic review and meta-analysis of 5,316 patients from 35 studies. *EuroIntervention* 2022;18:840-51.
7. Dreyfus J, Flagiello M, Bazire B, et al. Isolated tricuspid valve surgery: impact of aetiology and clinical presentation on outcomes. *Eur Heart J* 2020;41:4304-17.
8. Holda MK, Zhingre Sanchez JD, Bate-man MG, Iaizzo PA. Right atrioventricular valve leaflet morphology redefined: implications for transcatheter repair procedures. *JACC Cardiovasc Interv* 2019;12:169-78.
9. Hahn RT, Weckbach LT, Noack T, et al. Proposal for a standard echocardiographic tricuspid valve nomenclature. *JACC Cardiovasc Imaging* 2021;14:1299-305.
10. Tretter JT, Sarwark AE, Anderson RH, Spicer DE. Assessment of the anatomical variation to be found in the normal tricuspid valve. *Clin Anat* 2016;29:399-407.
11. Yamane K, Takahashi Y, Fujii H, et al. Histology of the tricuspid valve annulus and right atrioventricular muscle distance. *Interact Cardiovasc Thorac Surg* 2022;35(2):ivac175.
12. El-Busaid H, Hassan S, Odula P, Ogeng'o J, Ndung'u B. Sex variations in the structure of human atrioventricular annuli. *Folia Morphol (Warsz)* 2012;71:23-7.
13. Addetia K, Muraru D, Veronesi F, et al. 3-dimensional echocardiographic analysis of the tricuspid annulus provides new insights into tricuspid valve geometry and dynamics. *JACC Cardiovasc Imaging* 2019;12:401-12.

14. Spinner EM, Shannon P, Buice D, et al. In vitro characterization of the mechanisms responsible for functional tricuspid regurgitation. *Circulation* 2011;124:920-9.
15. Dahou A, Levin D, Reisman M, Hahn RT. Anatomy and physiology of the tricuspid valve. *JACC Cardiovasc Imaging* 2019;12:458-68.
16. Konstam MA, Kiernan MS, Bernstein D, et al. Evaluation and management of right-sided heart failure: a scientific statement from the American Heart Association. *Circulation* 2018;137(20):e578-e622.
17. Haddad F, Doyle R, Murphy DJ, Hunt SA. Right ventricular function in cardiovascular disease, part II: pathophysiology, clinical importance, and management of right ventricular failure. *Circulation* 2008;117:1717-31.
18. Stolz L, Orban M, Besler C, et al. Cardiohepatic syndrome is associated with poor prognosis in patients undergoing tricuspid transcatheter edge-to-edge valve repair. *JACC Cardiovasc Interv* 2022;15:179-89.
19. Mutlak D, Khalil J, Lessick J, Kehat I, Agmon Y, Aronson D. Risk factors for the development of functional tricuspid regurgitation and their population-attributable fractions. *JACC Cardiovasc Imaging* 2020;13:1643-51.
20. Muraru D, Guta AC, Ochoa-Jimenez RC, et al. Functional regurgitation of atrioventricular valves and atrial fibrillation: an elusive pathophysiological link deserving further attention. *J Am Soc Echocardiogr* 2020;33:42-53.
21. Itakura K, Hidaka T, Nakano Y, et al. Successful catheter ablation of persistent atrial fibrillation is associated with improvement in functional tricuspid regurgitation and right heart reverse remodeling. *Heart Vessels* 2020;35:842-51.
22. Soulat-Dufour L, Lang S, Addetia K, et al. Restoring sinus rhythm reverses cardiac remodeling and reduces valvular regurgitation in patients with atrial fibrillation. *J Am Coll Cardiol* 2022;79:951-61.
23. Ortiz-Leon XA, Posada-Martinez EL, Trejo-Paredes MC, et al. Tricuspid and mitral remodeling in atrial fibrillation: a three-dimensional echocardiographic study. *Eur Heart J Cardiovasc Imaging* 2022;23:944-55.
24. Harada T, Obokata M, Omote K, et al. Functional tricuspid regurgitation and right atrial remodeling in heart failure with preserved ejection fraction. *Am J Cardiol* 2022;162:129-35.
25. Ikoma T, Obokata M, Okada K, et al. Impact of right atrial remodeling in heart failure with preserved ejection fraction. *J Card Fail* 2021;27:577-84.
26. Singh JP, Evans JC, Levy D, et al. Prevalence and clinical determinants of mitral, tricuspid, and aortic regurgitation (the Framingham Heart Study). *Am J Cardiol* 1999;83:897-902.
27. Coffey S, d'Arcy JL, Loudon MA, Mant D, Farmer AJ, Prendergast BD. The OxVALVE population cohort study (OxVALVE-PCS)-population screening for undiagnosed valvular heart disease in the elderly: study design and objectives. *Open Heart* 2014;1(1):e000043.
28. Nkomo VT, Gardin JM, Skelton TN, Gottdiener JS, Scott CG, Enriquez-Sarano M. Burden of valvular heart diseases: a population-based study. *Lancet* 2006;368:1005-11.
29. Tung M, Nah G, Tang J, Marcus G, Delling FN. Valvular disease burden in the modern era of percutaneous and surgical interventions: the UK Biobank. *Open Heart* 2022;9(2):e002039.
30. Topilsky Y, Maltais S, Medina Inojosa J, et al. Burden of tricuspid regurgitation in patients diagnosed in the community setting. *JACC Cardiovasc Imaging* 2019;12:433-42.
31. Prihadi EA, van der Bijl P, GURSOY E, et al. Development of significant tricuspid regurgitation over time and prognostic implications: new insights into natural history. *Eur Heart J* 2018;39:3574-81.
32. Beale AL, Nanayakkara S, Segan L, et al. Sex differences in heart failure with preserved ejection fraction pathophysiology: a detailed invasive hemodynamic and echocardiographic analysis. *JACC Heart Fail* 2019;7:239-49.
33. Beale AL, Cosentino C, Segan L, et al. The effect of parity on exercise physiology in women with heart failure with preserved ejection fraction. *ESC Heart Fail* 2020;7:213-22.
34. Siddiqi HK, Vinayagamoorthy M, Gencer B, et al. Sex differences in atrial fibrillation risk: the VITAL rhythm study. *JAMA Cardiol* 2022;7:1027-35.
35. Medvedofsky D, Aronson D, Gombberg-Maitland M, et al. Tricuspid regurgitation progression and regression in pulmonary arterial hypertension: implications for right ventricular and tricuspid valve apparatus geometry and patients outcome. *Eur Heart J Cardiovasc Imaging* 2017;18:86-94.
36. Park J-H, Shin S-H, Lee M-J, et al. Clinical and echocardiographic factors affecting tricuspid regurgitation severity in the patients with lone atrial fibrillation. *J Cardiovasc Ultrasound* 2015;23:136-42.
37. Bertrand PB, Overbey JR, Zeng X, et al. Progression of tricuspid regurgitation after surgery for ischemic mitral regurgitation. *J Am Coll Cardiol* 2021;77:713-24.
38. Praz F, Muraru D, Kreidel F, et al. Transcatheter treatment for tricuspid valve disease. *EuroIntervention* 2021;17:791-808.
39. Lancellotti P, Pibarot P, Chambers J, et al. Multi-modality imaging assessment of native valvular regurgitation: an EACVI and ESC council of valvular heart disease position paper. *Eur Heart J Cardiovasc Imaging* 2022;23(5):e171-e232.
40. Prihadi EA, Delgado V, Leon MB, Enriquez-Sarano M, Topilsky Y, Bax JJ. Morphologic types of tricuspid regurgitation: characteristics and prognostic implications. *JACC Cardiovasc Imaging* 2019;12:491-9.
41. Dietz MF, Prihadi EA, van der Bijl P, et al. Sex-specific differences in etiology and prognosis in patients with significant tricuspid regurgitation. *Am J Cardiol* 2021;147:109-15.
42. Holst KA, Connolly HM, Dearani JA. Ebstein's anomaly. *Methodist Debakey Cardiovasc J* 2019;15:138-44.
43. Nappi F, Spadaccio C, Mihos C, Shaikhrezai K, Acar C, Moon MR. The quest for the optimal surgical management of tricuspid valve endocarditis in the current era: a narrative review. *Ann Transl Med* 2020;8:1628.
44. Shmueli H, Thomas F, Flint N, Setia G, Janjic A, Siegel RJ. Right-sided infective endocarditis 2020: challenges and updates in diagnosis and treatment. *J Am Heart Assoc* 2020;9(15):e017293.
45. Mhanna M, Beran A, Al-Abdough A, et al. AngioVac for vegetation debulking in right-sided infective endocarditis: a systematic review and meta-analysis. *Curr Probl Cardiol* 2022;47:101353.
46. Slaughter MS, Badhwar V, Ising M, et al. Optimum surgical treatment for tricuspid valve infective endocarditis: an analysis of the Society of Thoracic Surgeons national database. *J Thorac Cardiovasc Surg* 2021;161(4):1227-1235.e1.
47. Luc JGY, Choi J-H, Kodja K, et al. Valvectomy versus replacement for the surgical treatment of infective tricuspid valve endocarditis: a systematic review and meta-analysis. *Ann Cardiothorac Surg* 2019;8:610-20.
48. Bin Mahmood SU, Nguemeni Tiako MJ, Mori M, et al. Isolated tricuspid valvectomy: a series of cases with intravenous drug abuse associated tricuspid valve endocarditis. *Thorac Cardiovasc Surg* 2019;67:631-6.
49. Yanagawa B, Elbatarny M, Verma S, et al. Surgical management of tricuspid valve infective endocarditis: a systematic review and meta-analysis. *Ann Thorac Surg* 2018;106:708-14.
50. Kim WK, Kim SE, Yoo JS, et al. Impact of valve repair on mild tricuspid insufficiency in rheumatic mitral surgery. *J Thorac Cardiovasc Surg* 2023;165(4):1374-1383.e7.
51. Itzhaki Ben Zadok O, Sagie A, Vaturi M, et al. Long-term outcomes after mitral valve replacement and tricuspid annuloplasty in rheumatic patients. *Ann Thorac Surg* 2019;107:539-45.
52. Nguyen A, Schaff HV, Abel MD, et al. Improving outcome of valve replacement

- for carcinoid heart disease. *J Thorac Cardiovasc Surg* 2019;158(1):99-107.e2.
53. van Son JA, Danielson GK, Schaff HV, Miller FA Jr. Traumatic tricuspid valve insufficiency: experience in thirteen patients. *J Thorac Cardiovasc Surg* 1994;108:893-8.
54. Bateson B, Ham PB III, Patel V, Shah R. Delayed presentation of traumatic tricuspid valve injury during index hospitalization. *Am Surg* 2018;84(2):e67-e69.
55. López-Vilella R, Paniagua-Martín MJ, González-Vilchez F, et al. Prevalence of tricuspid regurgitation after orthotopic heart transplantation and its evolution in the follow-up period: a long-term study. *Transplant Proc* 2022;54:2486-9.
56. Gavazzoni M, Heilbron F, Badano LP, et al. The atrial secondary tricuspid regurgitation is associated to more favorable outcome than the ventricular phenotype. *Front Cardiovasc Med* 2022;9:1022755.
57. Wang TKM, Akyuz K, Mentias A, et al. Contemporary etiologies, outcomes, and novel risk score for isolated tricuspid regurgitation. *JACC Cardiovasc Imaging* 2022;15:731-44.
58. Vieitez JM, Monteagudo JM, Mahia P, et al. New insights of tricuspid regurgitation: a large-scale prospective cohort study. *Eur Heart J Cardiovasc Imaging* 2021;22:196-202.
59. Muraru D, Addetia K, Guta AC, et al. Right atrial volume is a major determinant of tricuspid annulus area in functional tricuspid regurgitation: a three-dimensional echocardiographic study. *Eur Heart J Cardiovasc Imaging* 2021;22:660-9.
60. Schlotter F, Dietz MF, Stolz L, et al. Atrial functional tricuspid regurgitation: novel definition and impact on prognosis. *Circ Cardiovasc Interv* 2022;15(9):e011958.
61. Guta AC, Badano LP, Tomaselli M, et al. The pathophysiological link between right atrial remodeling and functional tricuspid regurgitation in patients with atrial fibrillation: a three-dimensional echocardiography study. *J Am Soc Echocardiogr* 2021;34(6):585-594.e1.
62. Otto CM, Nishimura RA, Bonow RO, et al. 2020 ACC/AHA guideline for the management of patients with valvular heart disease: a report of the American College of Cardiology/American Heart Association joint committee on clinical practice guidelines. *J Am Coll Cardiol* 2021;77(4):e25-e197.
63. Spinner EM, Lerakis S, Higginson J, et al. Correlates of tricuspid regurgitation as determined by 3D echocardiography: pulmonary arterial pressure, ventricle geometry, annular dilatation, and papillary muscle displacement. *Circ Cardiovasc Imaging* 2012;5:43-50.
64. Harjola V-P, Mebazaa A, Čelutkien J, et al. Contemporary management of acute right ventricular failure: a statement from the Heart Failure Association and the Working Group on Pulmonary Circulation and Right Ventricular Function of the European Society of Cardiology. *Eur J Heart Fail* 2016;18:226-41.
65. Topilsky Y, Nkomo VT, Vatury O, et al. Clinical outcome of isolated tricuspid regurgitation. *JACC Cardiovasc Imaging* 2014;7:1185-94.
66. Chen E, L'official G, Guérin A, et al. Natural history of functional tricuspid regurgitation: impact of cardiac output. *Eur Heart J Cardiovasc Imaging* 2021;22:878-85.
67. Hell MM, Emrich T, Kreidel F, et al. Computed tomography imaging needs for novel transcatheter tricuspid valve repair and replacement therapies. *Eur Heart J Cardiovasc Imaging* 2021;22:601-10.
68. Topilsky Y, Khanna A, Le Tourneau T, et al. Clinical context and mechanism of functional tricuspid regurgitation in patients with and without pulmonary hypertension. *Circ Cardiovasc Imaging* 2012;5:314-23.
69. Itelman E, Vatury O, Kuperstein R, et al. The Association of severe tricuspid regurgitation with poor survival is modified by right ventricular pressure and function: insights from SHEBAHEART big data. *J Am Soc Echocardiogr* 2022;35:1028-36.
70. Polewczyk A, Kutarski A, Tomaszewski A, et al. Lead dependent tricuspid dysfunction: analysis of the mechanism and management in patients referred for transvenous lead extraction. *Cardiol J* 2013;20:402-10.
71. Addetia K, Harb SC, Hahn RT, Kapadia S, Lang RM. Cardiac implantable electronic device lead-induced tricuspid regurgitation. *JACC Cardiovasc Imaging* 2019;12:622-36.
72. Vaturi M, Kusniec J, Shapira Y, et al. Right ventricular pacing increases tricuspid regurgitation grade regardless of the mechanical interference to the valve by the electrode. *Eur J Echocardiogr* 2010;11:550-3.
73. Ehieli WL, Boll DT, Marin D, Lewis R, Piccini JP, Hurwitz LM. Use of preprocedural MDCT for cardiac implantable electronic device lead extraction: frequency of findings that change management. *AJR Am J Roentgenol* 2017;208:770-6.
74. Kanawati J, Ng ACC, Khan H, et al. Long-term follow-up of mortality and heart failure hospitalisation in patients with intracardiac device-related tricuspid regurgitation. *Heart Lung Circ* 2021;30:692-7.
75. Tatum R, Maynes EJ, Wood CT, et al. Tricuspid regurgitation associated with implantable electrical device insertion: a systematic review and meta-analysis. *Pacing Clin Electrophysiol* 2021;44:1297-302.
76. Anvardeen K, Rao R, Hazra S, et al. Prevalence and significance of tricuspid regurgitation post-endocardial lead placement. *JACC Cardiovasc Imaging* 2019;12:562-4.
77. Vahanian A, Beyersdorf F, Praz F, et al. 2021 ESC/EACTS Guidelines for the management of valvular heart disease. *Eur Heart J* 2022;43:561-632.
78. Al-Bawardy R, Krishnaswamy A, Bhargava M, et al. Tricuspid regurgitation in patients with pacemakers and implantable cardiac defibrillators: a comprehensive review. *Clin Cardiol* 2013;36:249-54.
79. Seo J, Kim DY, Cho I, Hong GR, Ha JW, Shim CY. Prevalence, predictors, and prognosis of tricuspid regurgitation following permanent pacemaker implantation. *PLoS One* 2020;15(6):e0235230.
80. Chang JD, Manning WJ, Ebrille E, Zimetbaum PJ. Tricuspid valve dysfunction following pacemaker or cardioverter-defibrillator implantation. *J Am Coll Cardiol* 2017;69:2331-41.
81. Polewczyk A, Jacheć W, Nowosielecka D, et al. Tricuspid valve damage related to transvenous lead extraction. *Int J Environ Res Public Health* 2022;19:12279.
82. Zoghbi WA, Adams D, Bonow RO, et al. Recommendations for noninvasive evaluation of native valvular regurgitation: a report from the American Society of Echocardiography developed in collaboration with the Society for Cardiovascular Magnetic Resonance. *J Am Soc Echocardiogr* 2017;30:303-71.
83. Hahn RT, Zamorano JL. The need for a new tricuspid regurgitation grading scheme. *Eur Heart J Cardiovasc Imaging* 2017;18:1342-3.
84. Nickenig G, Weber M, Lurz P, et al. Transcatheter edge-to-edge repair for reduction of tricuspid regurgitation: 6-month outcomes of the TRILUMINATE single-arm study. *Lancet* 2019;394:2002-11.
85. Kodali S, Hahn RT, Eleid MF, et al. Feasibility study of the transcatheter valve repair system for severe tricuspid regurgitation. *J Am Coll Cardiol* 2021;77:345-56.
86. Peri Y, Sadeh B, Sherez C, et al. Quantitative assessment of effective regurgitant orifice: impact on risk stratification, and cut-off for severe and torrential tricuspid regurgitation grade. *Eur Heart J Cardiovasc Imaging* 2020;21:768-76.
87. Zhan Y, Debs D, Khan MA, et al. Natural history of functional tricuspid regurgitation quantified by cardiovascular magnetic resonance. *J Am Coll Cardiol* 2020;76:1291-301.
88. Badano LP, Caravita S, Rella V, Guida V, Parati G, Muraru D. The added value of 3-dimensional echocardiography to understand the pathophysiology of functional tricuspid regurgitation. *JACC Cardiovasc Imaging* 2021;14:683-9.
89. Heidenreich PA, Bozkurt B, Aguilar D, et al. 2022 AHA/ACC/HFSA guideline for the management of heart failure: a report of the American College of Cardiol-

- ogy/American Heart Association joint committee on clinical practice guidelines. *J Am Coll Cardiol* 2022;79(17):e263-e421.
90. Felker GM, Ellison DH, Mullens W, Cox ZL, Testani JM. Diuretic therapy for patients with heart failure: JACC state-of-the-art review. *J Am Coll Cardiol* 2020;75:1178-95.
91. Dietz MF, Prihadi EA, van der Bijl P, Ajmone Marsan N, Delgado V, Bax JJ. Prognostic implications of staging right heart failure in patients with significant secondary tricuspid regurgitation. *JACC Heart Fail* 2020;8:627-36.
92. Humbert M, Kovacs G, Hoeper MM, et al. 2022 ESC/ERS guidelines for the diagnosis and treatment of pulmonary hypertension. *Eur Heart J* 2022;43:3618-731.
93. Heidenreich PA, Bozkurt B, Aguilar D, et al. 2022 AHA/ACC/HFSA guideline for the management of heart failure: a report of the American College of Cardiol-
- ogy/American Heart Association joint committee on clinical practice guidelines. *Circulation* 2022;145(18):e895-e1032.
94. Stassen J, Galloo X, Hirasawa K, et al. Tricuspid regurgitation after cardiac resynchronization therapy: evolution and prognostic significance. *Europace* 2022;24:1291-9.
95. Adamo M, Pagnesi M, Ghizzoni G, et al. Evolution of tricuspid regurgitation after transcatheter edge-to-edge mitral valve repair for secondary mitral regurgitation and its impact on mortality. *Eur J Heart Fail* 2022;24:2175-84.
96. Park SJ, Oh JK, Kim SO, et al. Determinants of clinical outcomes of surgery for isolated severe tricuspid regurgitation. *Heart* 2021;107:403-10.
97. Taramasso M, Hahn RT, Alessandrini H, et al. The international multicenter trivalve registry: which patients are undergoing transcatheter tricuspid repair? *JACC Cardiovasc Interv* 2017;10:1982-90.
98. Sannino A, Ilardi F, Hahn RT, et al. Clinical and echocardiographic outcomes of transcatheter tricuspid valve interventions: a systematic review and meta-analysis. *Front Cardiovasc Med* 2022;9:919395.
99. Webb JG, Chuang AM, Meier D, et al. Transcatheter tricuspid valve replacement with the EVOQUE system: 1-year outcomes of a multicenter, first-in-human experience. *JACC Cardiovasc Interv* 2022;15:481-91.
100. Weckbach LT, Stolz L, Chatfield AG, et al. Right ventricular reverse remodeling after transcatheter tricuspid valve replacement in patients with heart failure. *J Am Coll Cardiol* 2023;81:708-10.
101. Sorajja P, Whisenant B, Hamid N, et al. Transcatheter repair for patients with tricuspid regurgitation. *N Engl J Med* 2023;388:1833-42.

Copyright © 2023 Massachusetts Medical Society.

#### IMAGES IN CLINICAL MEDICINE

The *Journal* welcomes consideration of new submissions for Images in Clinical Medicine. Instructions for authors and procedures for submissions can be found on the *Journal's* website at [NEJM.org](http://NEJM.org). At the discretion of the editor, images that are accepted for publication may appear in the print version of the *Journal*, the electronic version, or both.