

Accuracy of Multislice Computed Tomography in the Preoperative Assessment of Coronary Disease in Patients With Aortic Valve Stenosis

Martine Gilard, MD,* Jean-Christophe Cornily, MD,* Pierre-Yves Pennec, MD,* Cedric Joret,* Grégoire Le Gal, MD,† Jacques Mansourati, MD,* Jean-Jacques Blanc, MD,* Jacques Boschat, MD*

Brest, France

OBJECTIVES To evaluate multislice computed tomography (MSCT) as an alternative to coronary angiography, we prospectively studied its diagnostic accuracy for the detection of significant coronary artery lesions in patients with significant aortic valve stenosis undergoing valve surgery.

BACKGROUND In patients with aortic valve stenosis, coronary angiography is still recommended before surgery. Multislice computed tomography is a promising noninvasive technique for the detection of significant coronary artery lesions.

METHODS Fifty-five consecutive patients scheduled for coronary angiography in the preoperative assessment of aortic valve stenosis underwent 16-slice MSCT 24 h before coronary angiography. We analyzed coronary lesions, image quality, and arterial calcium score.

RESULTS The sensitivity of the MSCT-based strategy in detecting significant stenosis was 100%, and its specificity 80%. The positive and negative predictive values were respectively 55% and 100%. For calcium scores <1,000 (77% of patients), MSCT detected all patients without coronary artery disease, enabling conventional coronary angiography to be avoided in 35 of 55 cases (80%). For calcium scores >1,000, MSCT enabled conventional coronary angiography to be avoided in only 6% of cases, either because significant stenosis was found with a possible indication of revascularization, or because the examination was not interpretable.

CONCLUSIONS The results of this initial experience in relatively few patients suggest that MSCT-based coronary angiography may serve as an alternative to invasive coronary angiography to rule out significant coronary artery disease in patients scheduled for elective aortic valve replacement. Larger studies are necessary to fully explore the potential of coronary MSCT to improve preoperative risk stratification. (J Am Coll Cardiol 2006;xx:xxx) © 2006 by the American College of Cardiology Foundation

Multislice computed tomography (MSCT) is a promising noninvasive technique for the detection of obstructive epicardial coronary artery disease (CAD) (1–5). In all forms of valvular heart disease, significant associated CAD worsens the peri-operative prognosis. Although no large-scale clinical trial has assessed the contribution of coronary angiography, this invasive investigation is recommended in the preoperative assessment of patients with valvular heart disease (class I American College of Cardiology/American Heart Association guidelines) (6). To evaluate MSCT as an alternative to coronary angiography, we prospectively studied its diagnostic accuracy for the detection of significant coronary artery lesions in patients with significant aortic valve stenosis undergoing valve surgery.

METHODS

Study population. A total of 63 consecutive patients referred for conventional coronary angiography in the preoperative assessment of aortic valve stenosis were considered for inclusion (Fig. 1). Eight patients were excluded because of the presence of one of the following exclusion criteria:

irregular heart rate (n = 4), contrast agent contraindications (n = 1), or renal insufficiency (n = 3). Patients with a heart rate >70 beats/min received additional intravenous beta-blocker therapy (5 mg atenolol). Thus, our final sample was composed of 55 patients with severe aortic valve stenosis (mean transvalvular pressure gradient, 57 ± 16 mm Hg; aortic valve area, 0.35 ± 0.06 cm²/m²), who were additionally studied using MSCT 24 h before angiography. The characteristics of the study group are listed in Table 1. Surgical aortic valve replacement was performed in 47 patients (85%). All patients signed an informed consent form.

MSCT protocol and image reconstruction. The MSCT data sets were acquired using a 16-slice MSCT (Philips Mx8000 IDT 16, Eindhoven, the Netherlands). Briefly, a native scan without contrast medium was performed to determine total coronary and aortic valve calcium. Then, a volume data set was acquired (16 × 0.75-mm cross-section; gantry rotation time, 420 ms; table feed, 2.8 mm per rotation) covering the distance from the carina to the diaphragmatic side of the heart. Tube current was 400 mA, with a tube voltage of 120 kv. The entire heart was scanned during a single breath-hold; 120 ml of contrast agent (Xenetix 350, Guerbet, Aulnay sous Bois, France) was continuously injected at a rate of 4 ml/s. Automated

From the *Department of Cardiology and †EA 3878 and the Department of Internal Medicine, Brest University Hospital, Brest, France.

Manuscript received July 18, 2005; revised manuscript received November 28, 2005, accepted November 30, 2005.

Abbreviations and Acronyms

ASE	=	Agatston score equivalent
CAD	=	coronary artery disease
MSCT	=	multislice spiral computed tomography
ROC	=	receiver-operating characteristic

detection of peak enhancement in the aortic root was used to time the scan.

Cross-sectional images were reconstructed with a slice thickness of 0.8 mm at 0.4-mm intervals with retrospective gating, to obtain an image acquisition window of 100 ms. Axial images at 0%, 20%, 30%, 40%, 50%, 65%, 75%, and 85% of the RR interval were reconstructed for each patient and analyzed for motion artifacts.

A scoring method analogous to the Agatston score (7) was used to quantify coronary calcium. A calcified lesion was defined as an area of ≥ 3 connected pixels >130 Hounsfield units, and expressed as Agatston score equivalent (ASE).

All data sets were independently analyzed by two blinded physicians experienced in MSCT, using multiplanar reformations and three-dimensional reconstructions by the volume rendering technique. They were then asked to give a consensus regarding the presence of significant CAD per vessel and per patient. Image quality was classified as good (no or only minor motion artifacts), moderate (substantial

Table 1. Patient Characteristics

Total number of patients	55
Male (%)	38
Weight (kg)	71 \pm 17
Creatinine clearance (ml/min)	73.8 \pm 25.4
Age (yrs)	70 \pm 10
Smokers (%)	31
Dyslipidemia (%)	54.5
Diabetes mellitus (%)	16.4
Hypertension (%)	58.2
Family history (%)	16.4
Symptoms of angina (%)	40
Syncope (%)	15
NYHA functional class 1 (%)	7
NYHA functional class 2 (%)	69
NYHA functional class 3 (%)	10
NYHA functional class 4 (%)	0

NYHA = New York Heart Association.

motion artifacts), or bad (significant motion artifacts and/or low signal-to-noise ratio, and no luminal assessment of significant stenosis possible in at least one vessel). In addition, the observers were asked to state what would have been their recommendations for patient management (coronary angiography indicated or not).

Quantitative coronary angiography. Invasive coronary angiograms were obtained one day after MSCT, after intracoronary injection of 0.5 mg isosorbide dinitrate. Angiograms were evaluated by a blinded independent observer using quantitative coronary angiography (Numeric System,

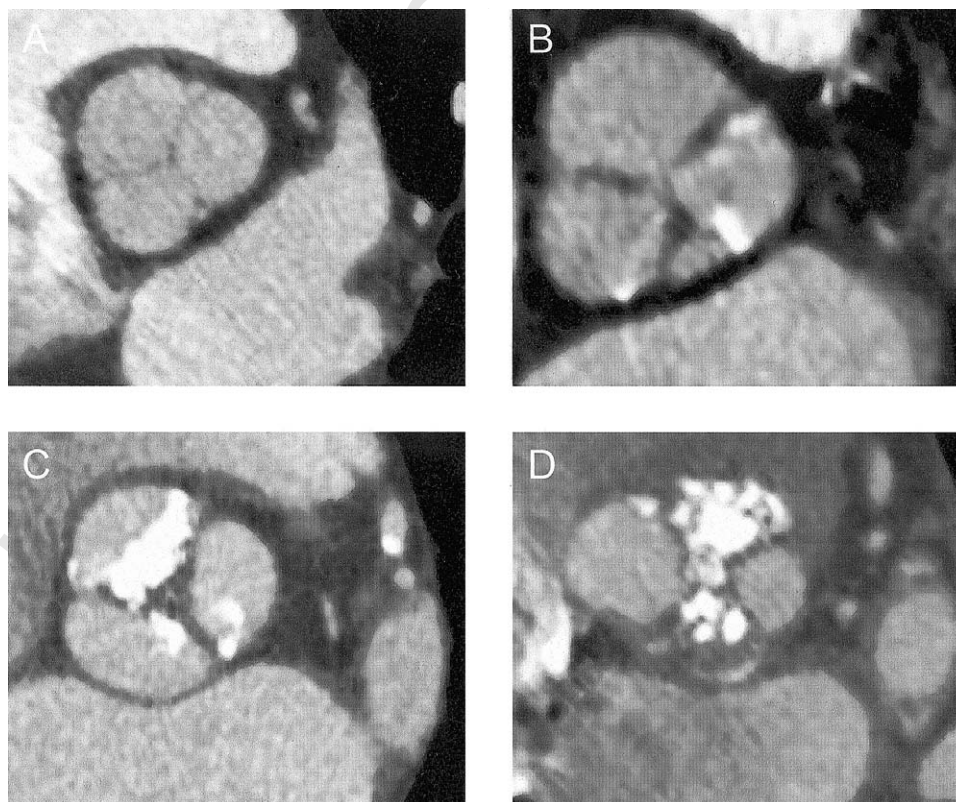


Figure 1. Different grades of aortic valve calcification. (A) Grade 1 = normal valve without calcification. (B) Grade 2 = moderate calcification. (C) Grade 3 = heavy calcification. (D) Heavily calcified bicuspid aortic valve.

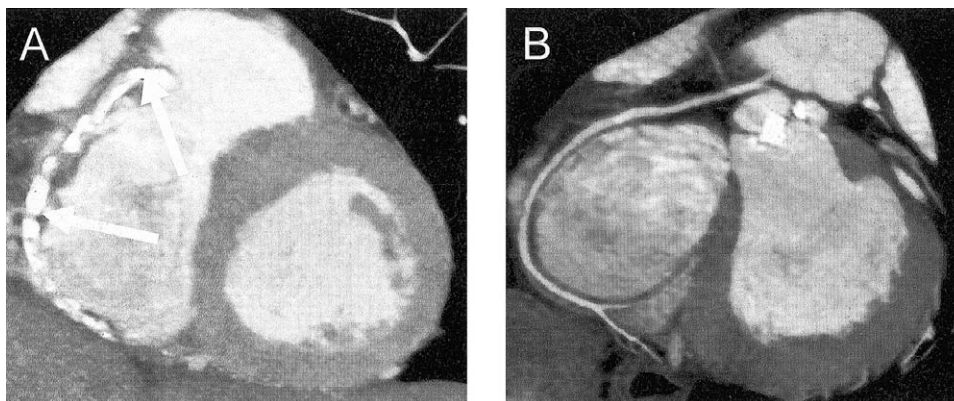


Figure 2. (A) Calcified, nonassessable right coronary artery. **White arrow** = heavily calcified areas. (B) Normal, assessable right coronary artery.

DX-DLX, General Electric Medical Systems, Buc, France) as stenosis detection gold standard. Lesions with $\geq 50\%$ diameter reduction counted as significant stenosis.

Statistics. General characteristics of the study sample were assessed by means and standard deviations for continuous variables, and by percentages for categorical variables. We estimated the sensitivity, specificity, and their 95% confidence intervals, and positive and negative predictive values for an MSCT-based strategy with coronary angiography performed in case of abnormal or inconclusive MSCT.

A receiver-operating characteristic (ROC) curve analysis was performed to assess the ability of ASE to detect patients in whom conventional coronary angiography would be required under the above strategy. All analyses used SPSS analysis software (release 12.0, SPSS Inc., Chicago, Illinois).

RESULTS

All patients underwent MSCT without any complications. Mean scan duration was 23.7 ± 4.7 s. Mean heart rate was 66 ± 6 beats/min. Intravenous beta-blocking was performed in eight patients (14%). Image quality was good in

41 patients (75%), moderate in 10 patients (18%), and poor in 4 patients (7%).

Coronary artery analysis. The prevalence of significant CAD (at least one $\geq 50\%$ stenosis) was 20% (11 of 55 patients), on the basis of conventional coronary angiography (one-vessel disease in 4 patients, two-vessel disease in 5 patients, and three-vessel disease in 2 patients). In 14 of the 55 patients (25%), lumen assessment by MSCT was prevented in at least one vessel by heavy calcification ($n = 11$) (Fig. 2) and/or motion artifact ($n = 5$) and/or low signal-to-noise ratio ($n = 5$); 5 of these patients had CAD on conventional coronary angiography. The MSCT did not show significant CAD in 35 patients (64%), none of whom had CAD on conventional coronary angiography. Finally, MSCT showed evidence of CAD in six patients, all of whom had CAD on conventional coronary angiography (Fig. 3). No patients with significant CAD were considered normal on MSCT.

All 11 patients with CAD had either evidence of CAD on MSCT or calcification and/or motion artifact that precluded interpretation of the MSCT. The sensitivity of a strategy based on MSCT with coronary angiography in case

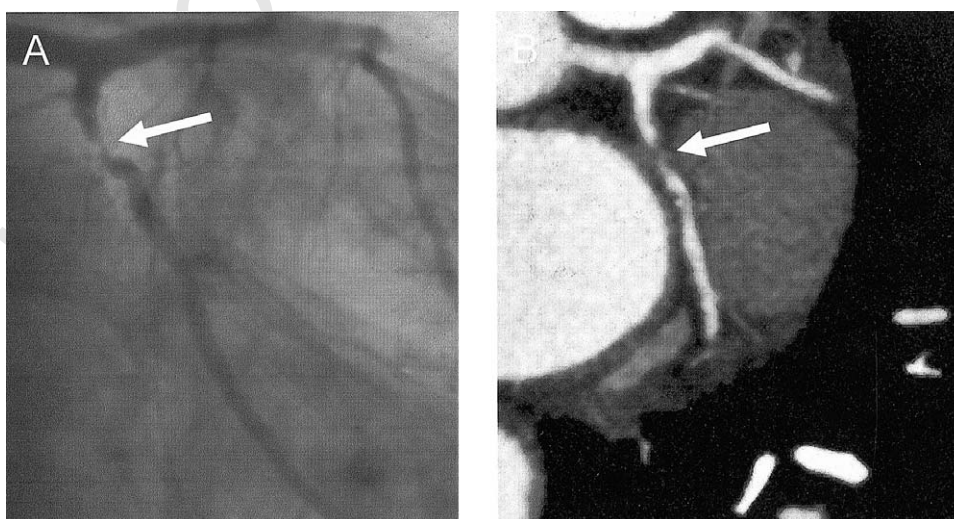


Figure 3. Angiogram (A) and multislice spiral computed tomography (MSCT) (B) of a subocclusive left circumflex artery.

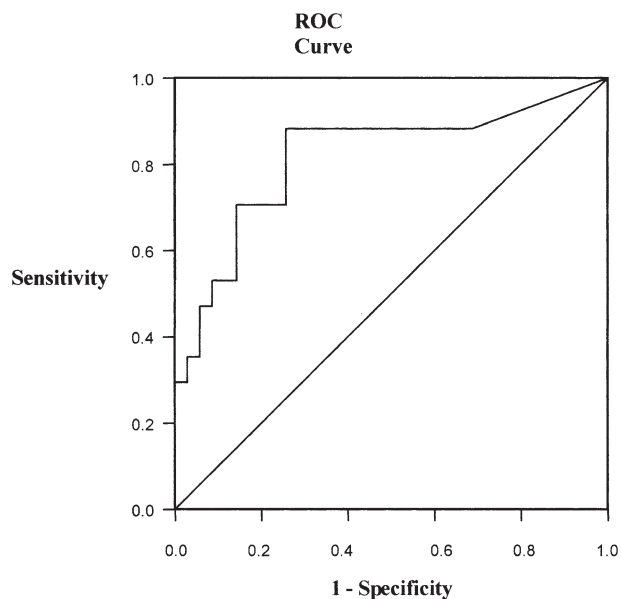


Figure 4. Receiver-operating characteristic (ROC) curve. Angiography is necessary according to calcium score. Area under the curve = 0.84.

of abnormal or inconclusive MSCT was 100% (95% confidence interval [CI] 75 to 100), and the specificity was 80% (95% CI 66 to 89). The positive and negative predictive values were respectively 55% and 100%.

Calcium scoring. Calcification was successfully assessed in all patients. The mean calcium score, expressed as ASE, was 609 ± 860 . The ability of the calcium score to detect patients in whom conventional coronary angiography was indicated was plotted as an ROC curve; the area under the ROC curve was 0.84 (Fig. 4). A cut-off of 1,000 was chosen as the best compromise between as low as possible a proportion of noninterpretable MSCTs and as high as possible a proportion of patients in whom the MSCT alone could rule out CAD.

DISCUSSION

In our study population of 55 patients with significant aortic valve stenosis, we found moderate positive predictive value (55%) and specificity (80%) but high negative predictive value (100%) and sensitivity (100%) for 16-slice MSCT in the detection of significant coronary stenosis.

The 20% prevalence of CAD in our study might seem surprising when compared with some series from North America (8). However, this prevalence is in accordance with the actual pattern in our geographic area. For example, CAD prevalence was 16% in the report by Logeais et al. (9) on 4,129 patients who underwent valvular replacement for calcified aortic stenosis in western France. Most practitioners feel compelled to assess coronary anatomy ahead of valve surgery and to treat significant stenosis during surgery by percutaneous intervention or bypass graft in the hope of avoiding subsequent reoperation. All patients with chest pain or noninvasive evidence of CAD should undergo coronary angiography (class I American College of Cardi-

ology/American Heart Association guidelines) (6). It still seems advisable to perform coronary angiography in patients who are at increased risk of CAD because of age or other risk factors (6). An MSCT with 16 to 64 rows has been shown to be accurate in detecting CAD (1–5). In many studies, sensitivity (72% to 95%) and specificity (86% to 98%) (1–5,10) were calculated on the interpretable artery segments, whereas 0 to 20% of segments were not analyzable because of artifacts or calcification. We chose to evaluate coronary arteries on a per-vessel instead of a per-segment basis because a single distal segment stenosis (number 4, 8, 15, or 16 of the classification of the American Heart Association [11]) will not have any impact on the management of such patients. Calcifications obscure the lumen because of beam hardening artifacts and therefore may impair assessment of luminal obstruction (5,12). Coronary calcifications are very frequent in patients with aortic valve stenosis—as in the present study, with a mean calcium score of 609 to 860. Kuettner et al. (13) showed calcification to be an important factor in analyzing coronary artery scans: when the ASE score falls below 1,000, stenosis detection sensitivity increases from 0.72% to 0.98%. In the present study, for an ASE <1,000 (77% of patients), MSCT detected all patients without CAD, enabling us to avoid conventional coronary angiography in 35 of these 41 patients (85%). For an ASE >1,000, MSCT enabled us to avoid conventional coronary angiography in only 6% of cases, either because significant stenosis was found with a possible indication of revascularization or because the examination could not be interpreted (Fig. 4). In those patients with an AS >1,000, we do not recommend a contrast-enhanced scan, which would be of virtually no benefit. Nevertheless, the positive predictive value for significant stenosis of a calcium score of >1,000 was no more than 45%.

Study limitations. The limitations of MSCT are radiation exposure (1.5 to 2 mSv for calcium scoring and 4 to 12 mSv for a contrast-enhanced scan) (5,11,14), the need for iodinated contrast agents, and the necessity of a relatively low heart rate. Our study may also be potentially limited by the low prevalence of CAD; CAD is, however, much less prevalent in Southern Europe than in Northern Europe or North America.

Conclusions. The results of this initial experience in relatively few patients suggest that MDCT-based coronary angiography may serve as an alternative to invasive coronary angiography to rule out significant CAD in patients scheduled for elective aortic valve replacement. Larger studies are necessary to fully explore the potential of coronary MDCT to improve preoperative risk stratification.

Reprint requests and correspondence: Dr. Martine Gilard, Department of Cardiology, La Cavale Blanche Hospital, 29609 Brest Cedex, France. E-mail: martine.gilard@chu-brest.fr.

REFERENCES

1. Nieman K, Cademartiri F, Lemos PA, Raaijmakers R, Pattynama PM, de Feyter PJ. Reliable noninvasive coronary angiography with fast submillimeter multislice spiral computed tomography. *Circulation* 2002;106:2051-4.
2. Ropers D, Baum U, Pohle K, et al. Detection of coronary artery stenoses with thin-slice multidetector row spiral computed tomography and multiplanar reconstruction. *Circulation* 2003;107:664-6.
3. Martuscelli E, Romagnoli A, D'Eliseo A, et al. Accuracy of thin-slice computed tomography in the detection of coronary stenoses. *Eur Heart J* 2004;25:1043-8.
4. Mollet NR, Cademartiri F, Krestin GP, et al. Improved diagnostic accuracy with 16-row multislice computed tomography coronary angiography. *J Am Coll Cardiol* 2005;45:128-32.
5. Leschka S, Alkadhi H, Plass A, et al. Accuracy of MSCT coronary angiography with 64-slice technology: first experience. *Eur Heart J* 2005.
6. Scanlon PJ, Faxon DP, Audet AM, et al. ACC/AHA guidelines for coronary angiography. A report of the American College of Cardiology/American Heart Association Task Force on practice guidelines (Committee on Coronary Angiography). Developed in collaboration with the Society for Cardiac Angiography and Interventions. *J Am Coll Cardiol* 1999;33:1756-824.
7. Agatston AS, Janowitz WR, Hildner FJ, Zusmer NR, Viamonte M Jr., Detrano R. Quantification of coronary artery calcium using ultrafast computed tomography. *J Am Coll Cardiol* 1990;15:827-32.
8. Potter D, Sundt T, Zehr K, et al. Operative risk of reoperative aortic valve replacement. *J Thorac Cardiovasc Surg* 2005;129:94-103.
9. Logeais Y, Leguerrier A, Rioux C, et al. Results of surgical treatment of calcified aortic valve stenosis: report of a series of 4129 interventions. *Bull Acad Natl Med* 2001;185:163-74.
10. Kuettner A, Beck T, Drosch T, et al. Diagnostic accuracy of noninvasive coronary imaging using 16-detector slice spiral computed tomography with 188 ms temporal resolution. *J Am Coll Cardiol* 2005;45:123-7.
11. Austen WG, Edwards JE, Frye RL, et al. A reporting system on patients evaluated for coronary artery disease. Report of the Ad Hoc Committee for Grading of Coronary Artery Disease, Council on Cardiovascular Surgery, American Heart Association. *Circulation* 1975;51 Suppl:5-40.
12. Adams DH, Chen RH, Kadner A, Aranki SF, Allred EN, Cohn LH. Impact of small prosthetic valve size on operative mortality in elderly patients after aortic valve replacement for aortic stenosis: does gender matter? *J Thorac Cardiovasc Surg* 1999;118:815-22.
13. Kuettner A, Trabold T, Schroeder S, et al. Noninvasive detection of coronary lesions using 16-detector multislice spiral computed tomography technology: initial clinical results. *J Am Coll Cardiol* 2004;44:1230-7.
14. Jakobs TF, Becker CR, Ohnesorge B, et al. Multislice helical CT of the heart with retrospective ECG gating: reduction of radiation exposure by ECG-controlled tube current modulation. *Eur Radiol* 2002;12:1081-6.

1
2
3
4
5
6
7
8
9
10
11
12
13
14
15
16
17
18
19
20
21
22
23
24
25
26
27
28
29
30
31
32
33
34
35
36
37
38
39
40
41
42
43
44
45
46
47
48
49
50
51
52
5362
63
64
65
66
67
68
69
70
71
72
73
74
75
76
77
78
79
80
81
82
83
84
85
86
87
88
89
90
91
92
93
94
95
96
97
98
99
100
101
102
103
104
105
106
107
108
109
110
111
112
113
114

mini-abstract for 1924

Accuracy of Multislice Computed Tomography in the Preoperative Assessment of Coronary Disease in Patients With Aortic Valve Stenosis

xxx

Martine Gilard, Jean-Christophe Cornily, Pierre-Yves Pennec, Cedric Joret, Grégoire Le Gal, Jacques Mansourati, Jean-Jacques Blanc, Jacques Bosch

Fifty-five consecutive patients scheduled for coronary angiography in the preoperative assessment of aortic valve stenosis underwent 16-slice multislice computed tomography (MSCT) 24 h before coronary angiography. We analyzed coronary lesions, image quality, and arterial calcium score. The MSCT seems to be an effective alternative to conventional coronary angiography. The following criteria may be proposed: in case of a calcium score >1,000, conventional coronary angiography is mandatory because of the poor performance of MSCT in such cases; in case of a calcium score <1,000, a contrast-enhanced MSCT may, when normal (80% of cases), replace conventional coronary angiography.

AQ: 77

Accuracy of Multislice Computed Tomography in the Preoperative Assessment of Coronary Disease in Patients With Aortic Valve Stenosis

xxx

Martine Gilard, Jean-Christophe Cornily, Pierre-Yves Pennec, Cedric Joret, Grégoire Le Gal, Jacques Mansourati, Jean-Jacques Blanc, Jacques Bosch

UNCORRECTED PROOF